

Iris Bombe

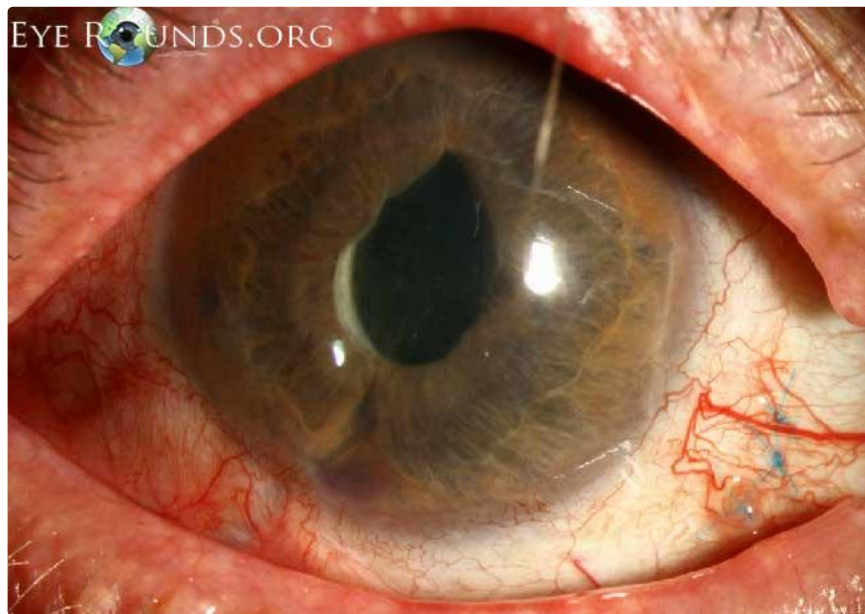Category(ies): Neuro-ophthalmology

Contributor: [Christopher Kirkpatrick, MD](#)

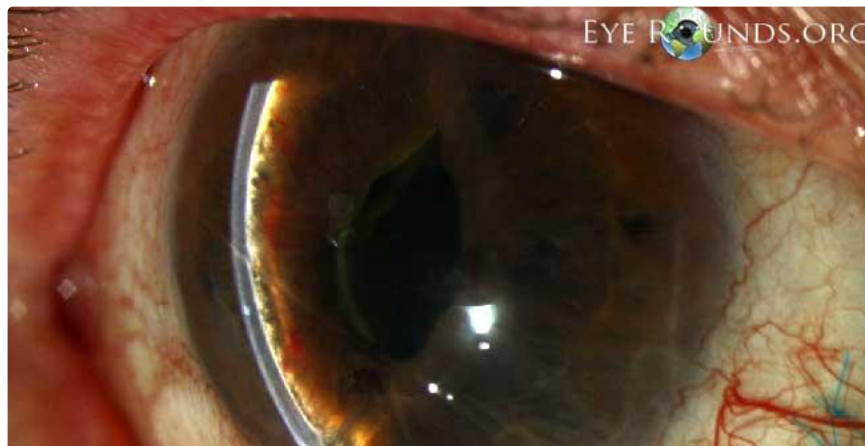Photographer: Toni Venckus, CRA

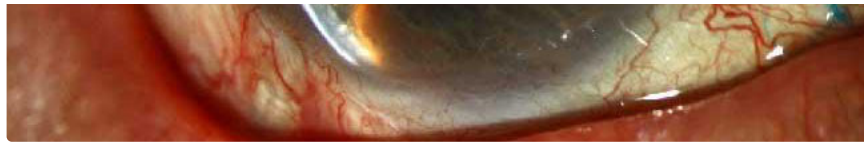

Iris bombe is a condition in which there is apposition of the iris to the lens or anterior vitreous, preventing aqueous from flowing from the posterior to the anterior chamber. The pressure in the posterior chamber rises, resulting in anterior bowing of the peripheral iris and obstruction of the trabecular meshwork. This may result in an acute attack of angle closure glaucoma. Also note in this photograph a Seton tube inferiorly that is occluded by the iris bowing forward and the iris contacting the corneal endothelium peripherally.



[Enlarge](#) [Download](#)



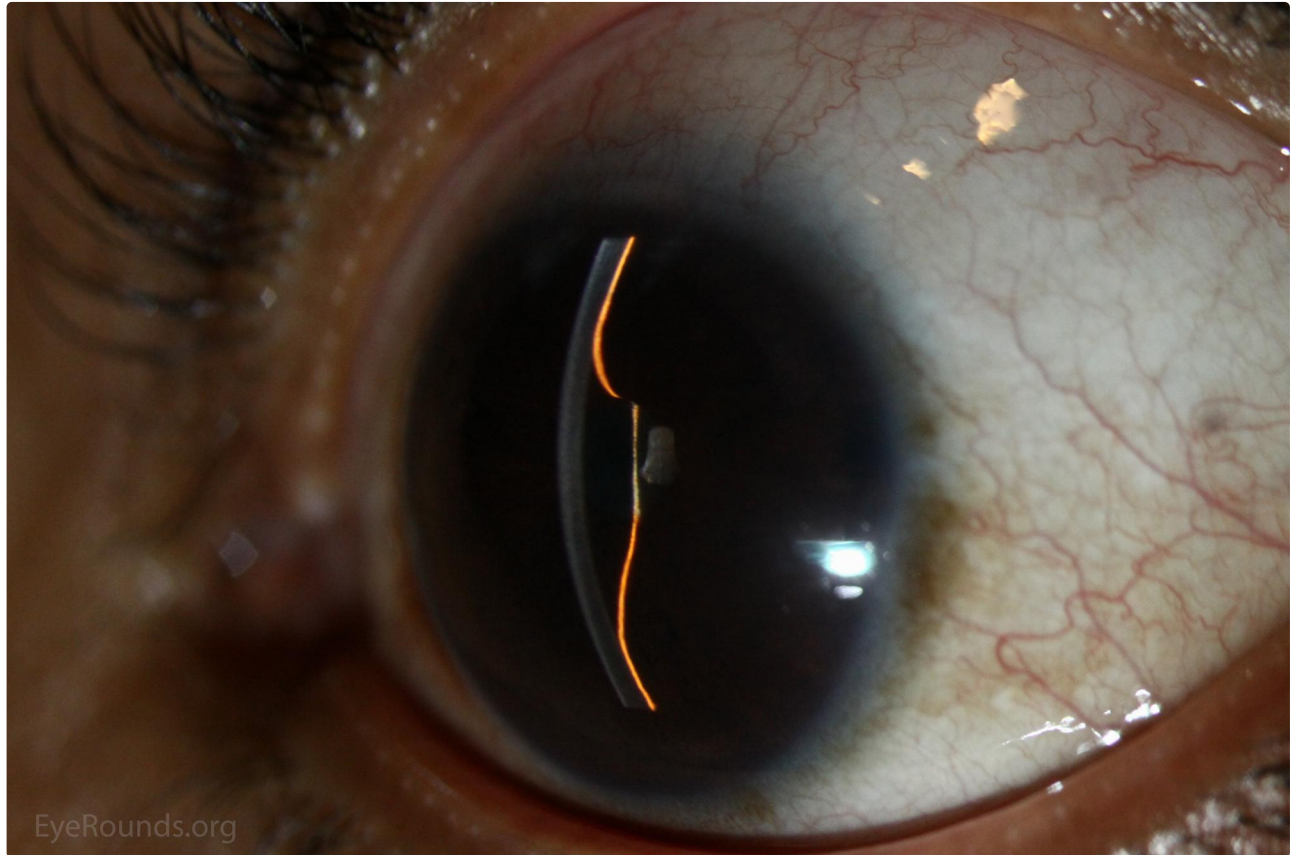


[Enlarge](#) [Download](#)

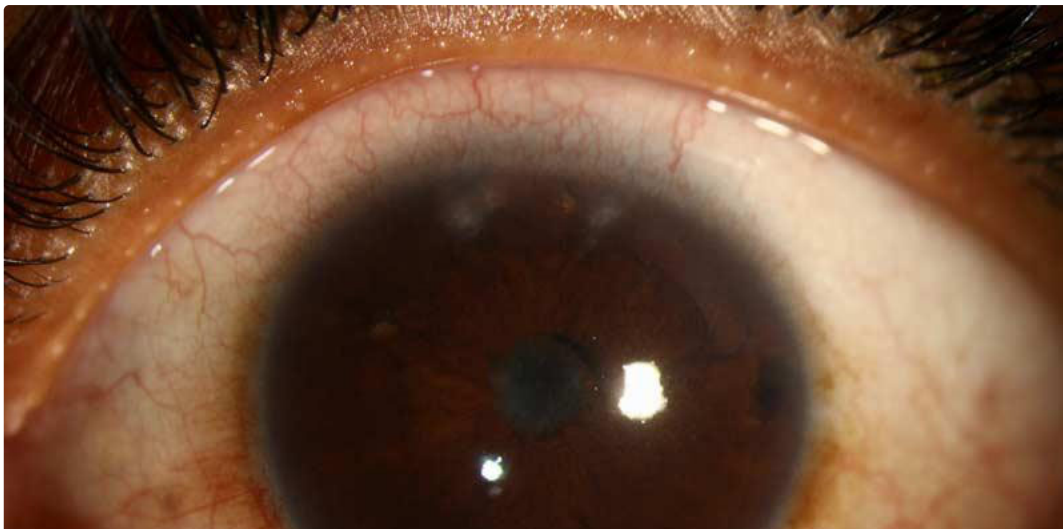
Contributor: [Austin R. Fox, MD](#)

Photographer: Douglas B. Critser

Despite multiple laser peripheral iridotomies, iris bombe developed in this patient with chronic iridocyclitis and central posterior synechiae.



[Enlarge](#) [Download](#)





[Enlarge](#)

[Download](#)

Image Permissions:



Ophthalmic Atlas Images by [EyeRounds.org](#), [The University of Iowa](#) are licensed under a [Creative Commons Attribution-NonCommercial-NoDerivs 3.0 Unported License](#).

Address

University of Iowa
Roy J. and Lucille A. Carver College
of Medicine
Department of Ophthalmology and
Visual Sciences
200 Hawkins Drive
Iowa City, IA 52242

[Support Us](#)

Legal

Copyright © 2019 The University of
Iowa. All Rights Reserved
[Report an issue with this page](#)
[Web Privacy Policy](#) |
[Nondiscrimination Statement](#)

Related Links

[Cataract Surgery for Greenhorns](#)
[EyeTransillumination](#)
[Gonioscopy.org](#)
[Iowa Glaucoma Curriculum](#)
[Iowa Wet Lab](#)
[Patient Information](#)
[Stone Rounds](#)
[The Best Hits Bookshelf](#)

EyeRounds Social Media

Follow



Receive notification of new cases,
[sign up here](#)
[Contact Us](#)
[Submit a Suggestion](#)