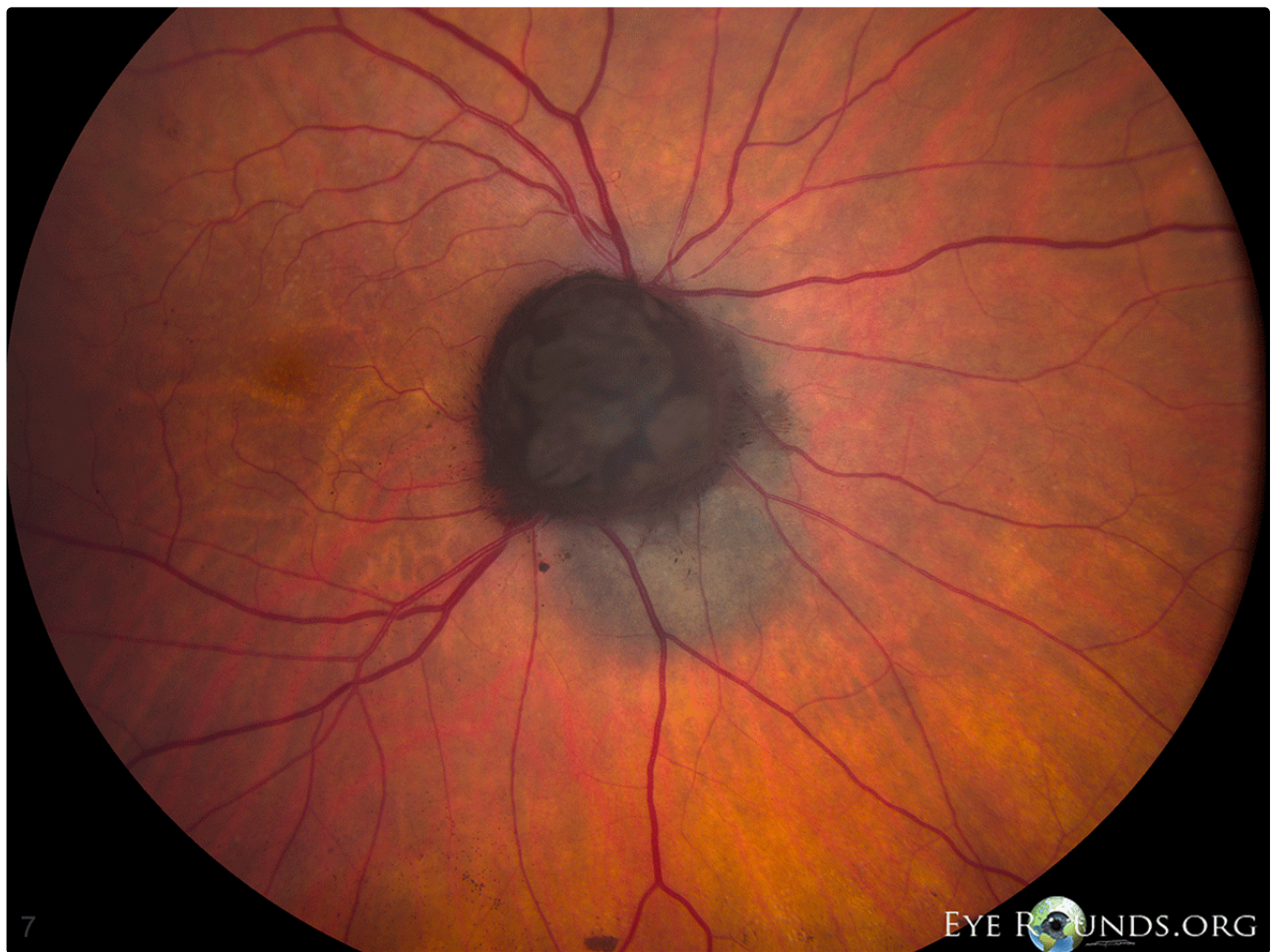

Melanocytoma with associated choroidal nevus

Category(ies): Retina, Vitreous

Contributor: [Jesse Vislisel, MD](#)

Melanocytomas, also known as magnocellular nevi, are deeply pigmented benign tumors often appearing over the optic disc. They are derived from uveal dendritic melanocytes. The tumors may be associated with nerve fiber layer or choroidal involvement as is seen in this photo.



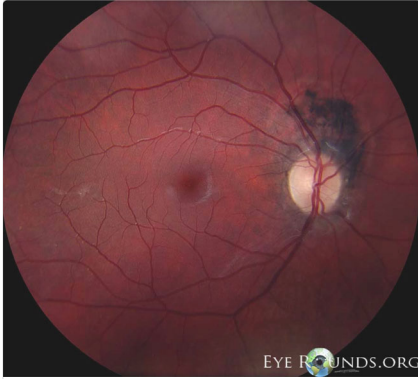[Enlarge](#) [Download](#)

Image Permissions:

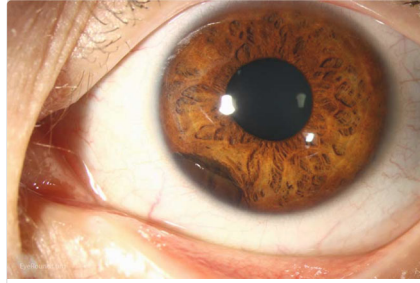


Ophthalmic Atlas Images by [EyeRounds.org](#), [The University of Iowa](#) are licensed under a [Creative Commons Attribution-NonCommercial-NoDerivs 3.0 Unported License](#).

Related Articles



[Related Atlas Entry: Melanocytoma of optic nerve](#)



[Related Atlas Entry: Iris Melanocytoma](#)

Address

University of Iowa
Roy J. and Lucille A. Carver College
of Medicine
Department of Ophthalmology and
Visual Sciences
200 Hawkins Drive
Iowa City, IA 52242

[Support Us](#)

Legal

Copyright © 2019 The University of
Iowa. All Rights Reserved
[Report an issue with this page](#)
[Web Privacy Policy I](#)
[Nondiscrimination Statement](#)

Related Links

[Cataract Surgery for Greenhorns](#)
[EyeTransillumination](#)
[Gonioscopy.org](#)
[Iowa Glaucoma Curriculum](#)
[Iowa Wet Lab](#)
[Patient Information](#)
[Stone Rounds](#)
[The Best Hits Bookshelf](#)

EyeRounds Social Media

Follow



Receive notification of new cases,
[sign up here](#)
[Contact Us](#)
[Submit a Suggestion](#)