

North Carolina macular dystrophy

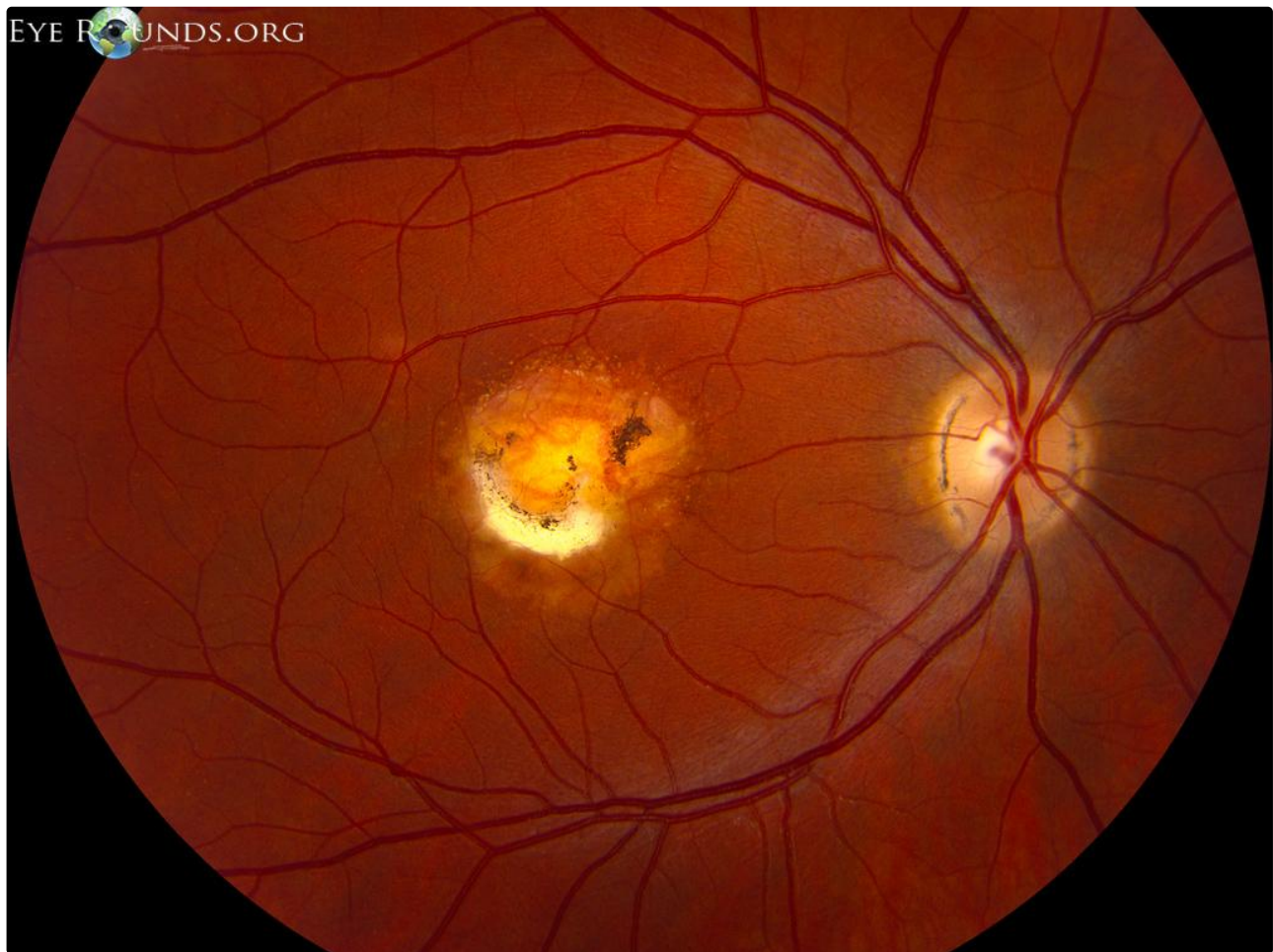
Category(ies): Genetics, Inherited Eye Disease, Retina

Contributor: [Jesse Vislisel, MD](#)

Photographer: Stefani Karakas, CRA, and Brice Critser, CRA

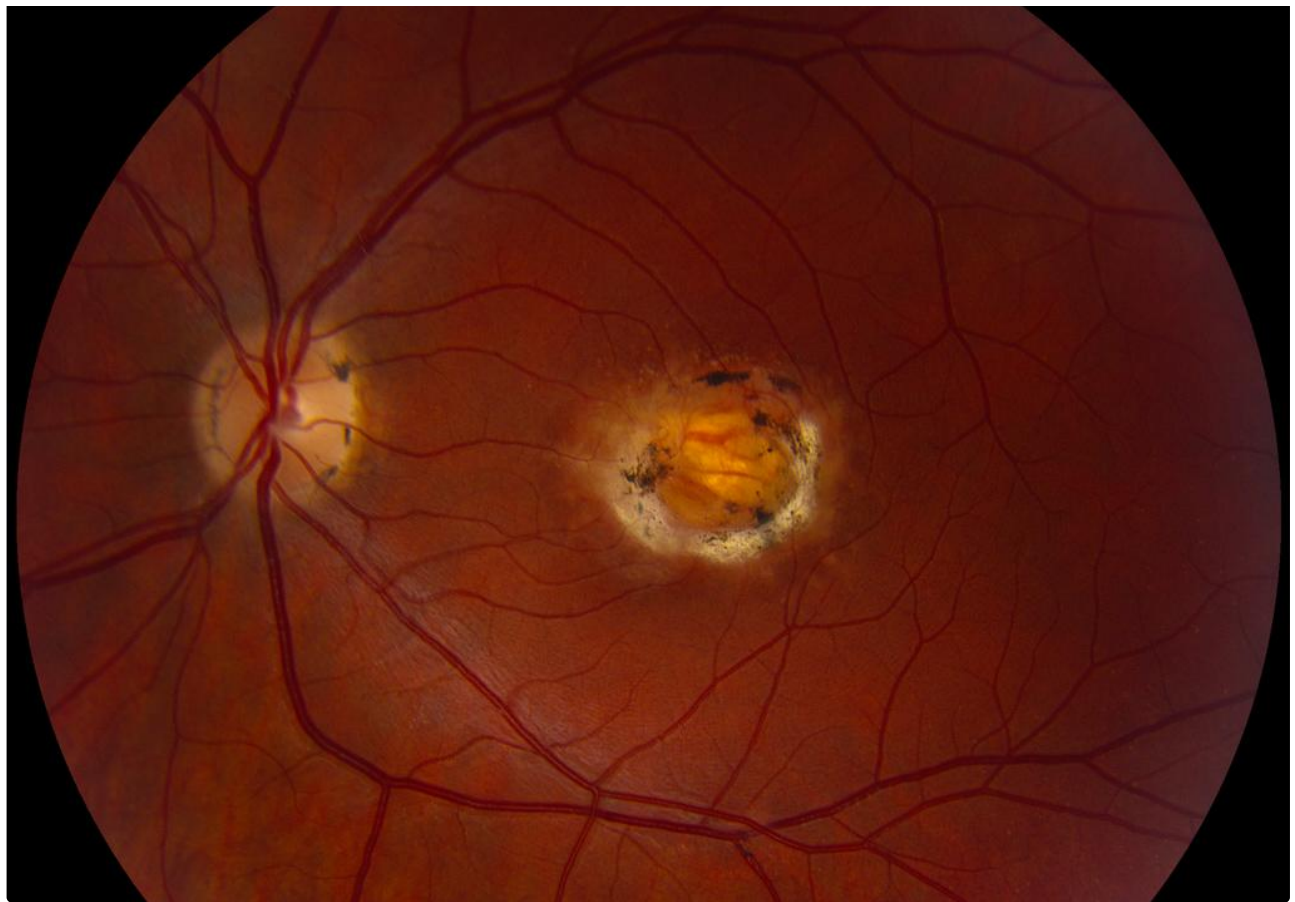

North Carolina macular dystrophy is an autosomal dominant condition resulting in congenital, stationary macular abnormalities. These photographs show the varying expressivity of the disease in two family members. Mild disease can present with central macular yellow-white drusen-like lesions at the level of the retinal pigmented epithelium. More severely affected individuals can exhibit severe macular dystrophy, often surrounded by a characteristic white, atrophic ring (visible sclera).



Right Eye

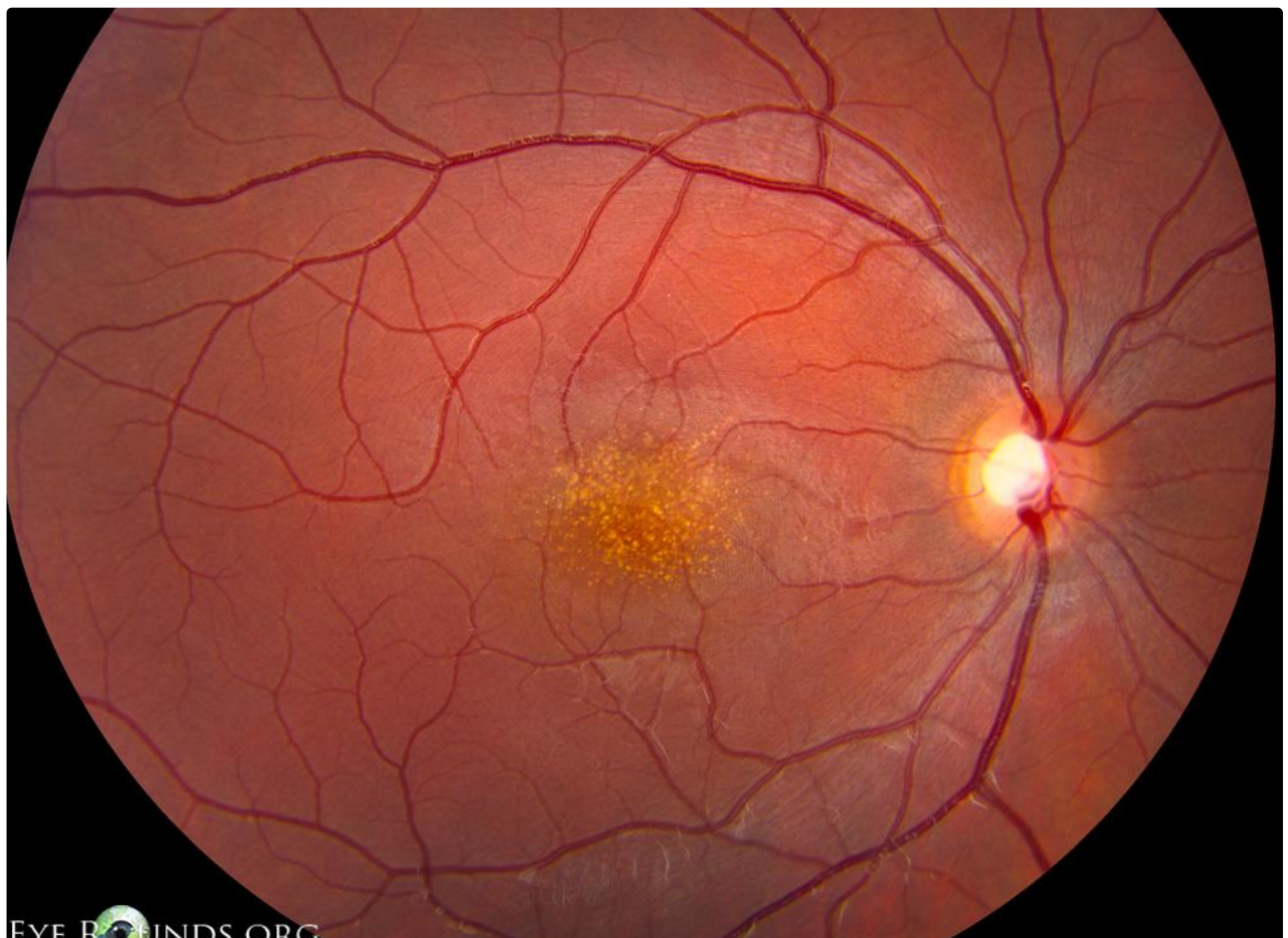
[Enlarge](#) [Download](#)



Right Eye

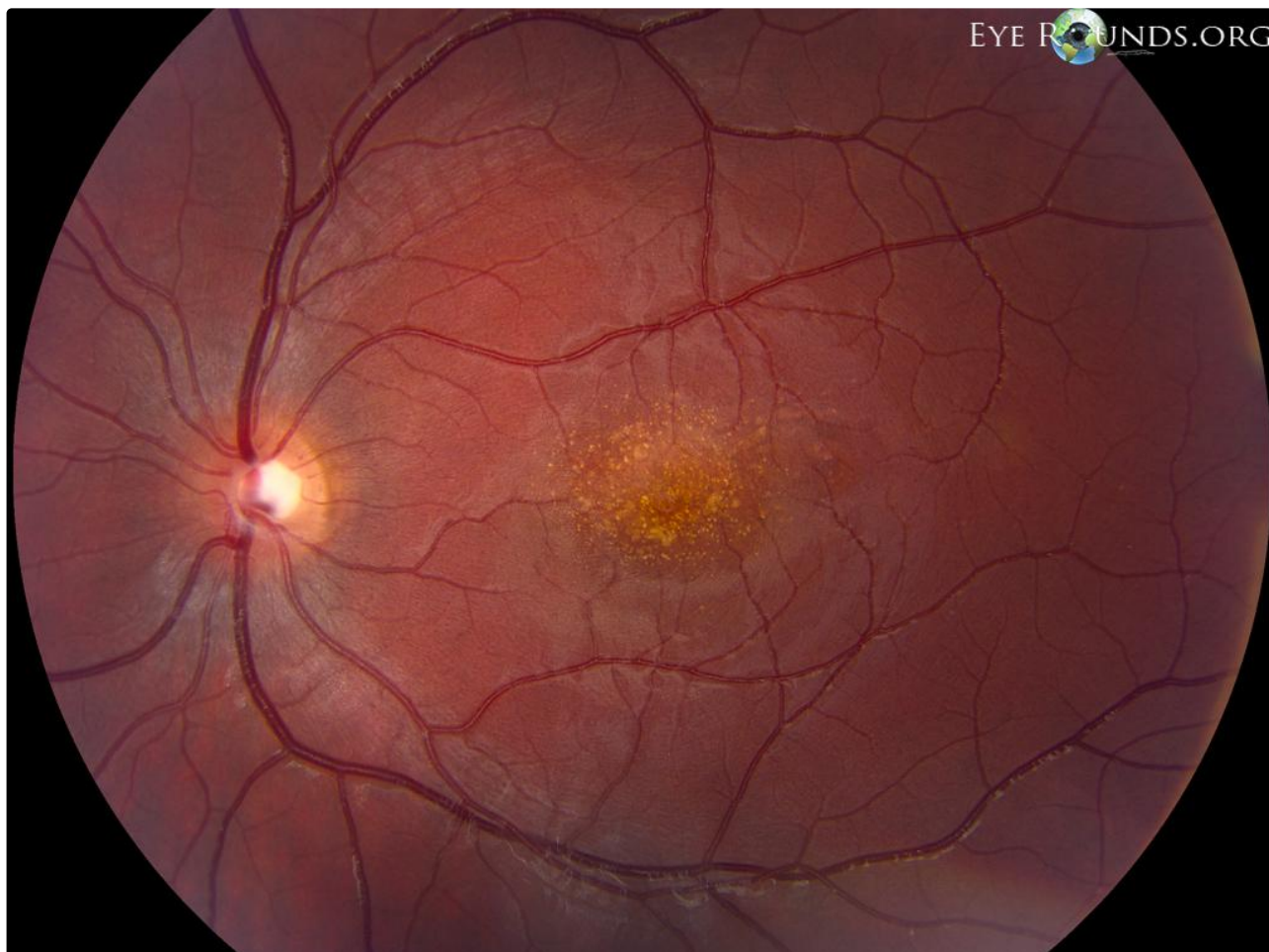
[Enlarge](#)

[Download](#)



Right Eye

[Enlarge](#) [Download](#)



Right Eye

[Enlarge](#) [Download](#)

Image Permissions:



Ophthalmic Atlas Images by EyeRounds.org, The University of Iowa are licensed under a [Creative Commons Attribution-NonCommercial-NoDerivs 3.0 Unported License](https://creativecommons.org/licenses/by-nc-nd/3.0/).

Address

University of Iowa
Roy J. and Lucille A. Carver College
of Medicine

Legal

Copyright © 2019 The University of
Iowa. All Rights Reserved
[Report an issue with this page](#)

Related Links

[Cataract Surgery for Greenhorns](#)
[EyeTransillumination](#)
[Gonioscopy.org](#)

**EyeRounds Social
Media**

[Follow](#)

Department of Ophthalmology and
Visual Sciences
200 Hawkins Drive
Iowa City, IA 52242

[Support Us](#)

[Web Privacy Policy |
Nondiscrimination Statement](#)

[Iowa Glaucoma Curriculum](#)
[Iowa Wet Lab](#)
[Patient Information](#)
[Stone Rounds](#)
[The Best Hits Bookshelf](#)



[Receive notification of new cases,
sign up here](#)
[Contact Us](#)
[Submit a Suggestion](#)