

## Rhegmatogenous retinal detachment

A rhegmatogenous retinal detachment results when liquified vitreous passes through a retinal break into the potential subretinal space.

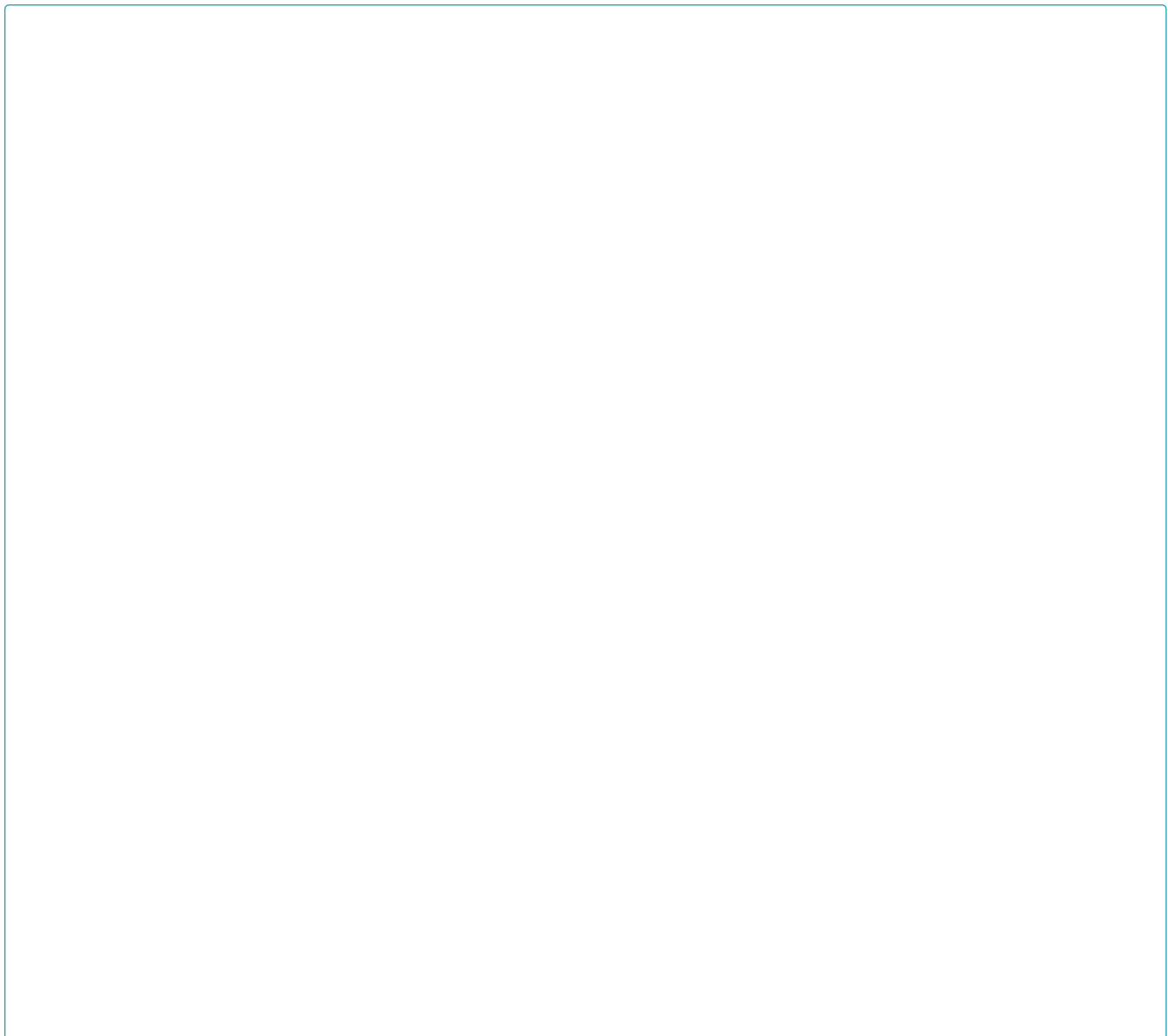
### Figure 1

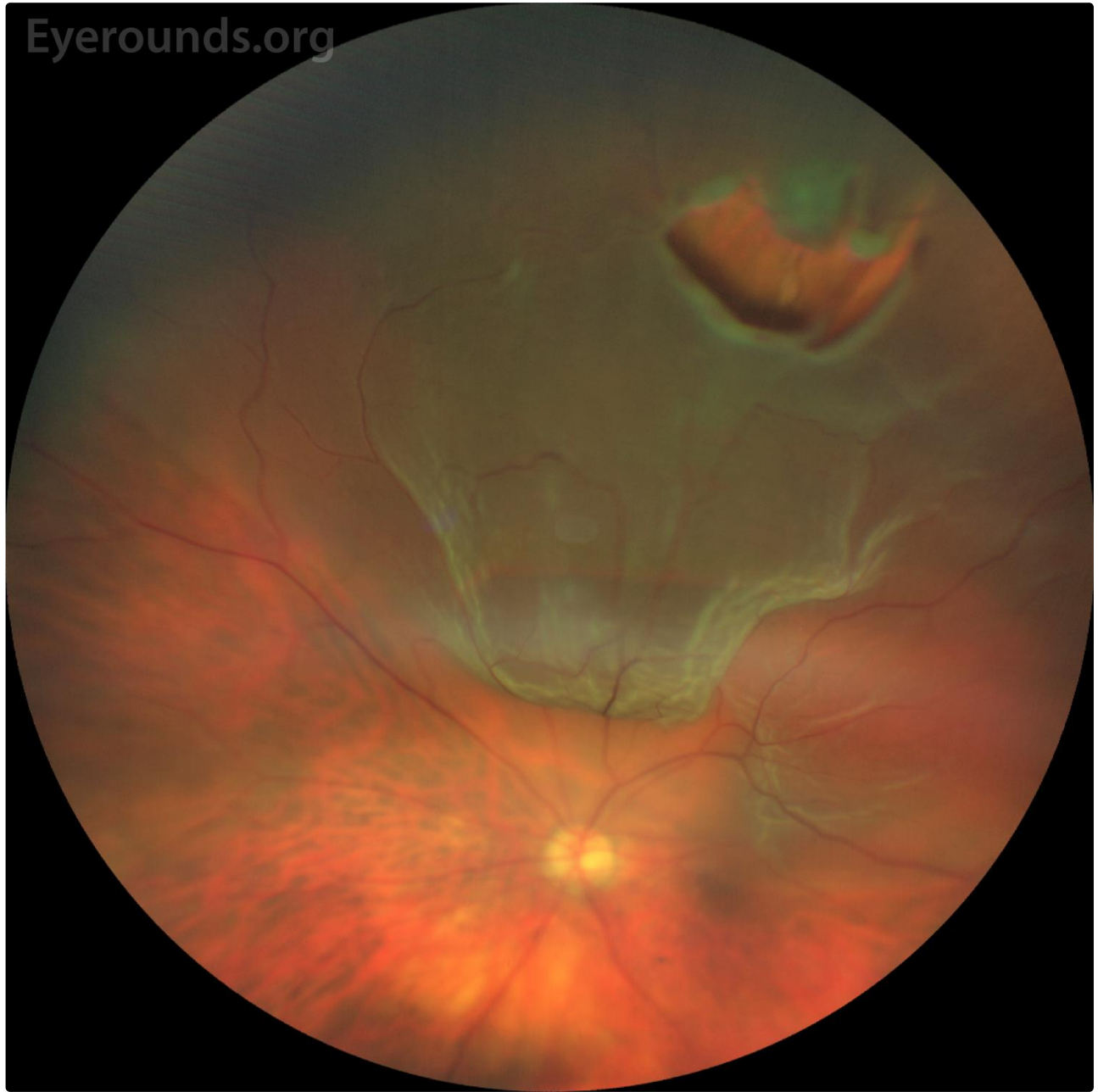**Category(ies):** Retina, Vitreous

**Contributor:** Zachary Q. Mortensen, MD; Razek G. Coussa; MDCM; James C. Folk, MD; H. Culver Boldt, MD

**Photographer:** Jody M. Troyer, CRA

71-year-old man presented with 2 weeks of blurred vision and curtain-like vision loss obscuring the inferior portion of his left visual field. Visual acuity was 20/50+2. Fundoscopy (see image) demonstrated a large horseshoe break at 12:30 at the equator, with a slightly rolled edge and a bridging vessel. There was subretinal fluid from 10:00 clockwise to 3:00, extending posteriorly to just involve the center of the fovea. This macula-involving rhegmatogenous retinal detachment was repaired surgically. Three months later, his vision improved to 20/20.





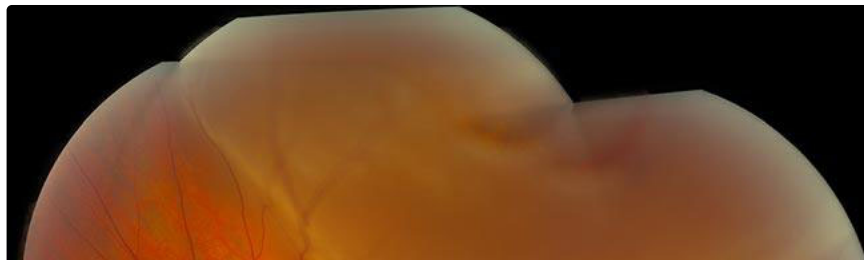
[Enlarge](#) [Download](#)

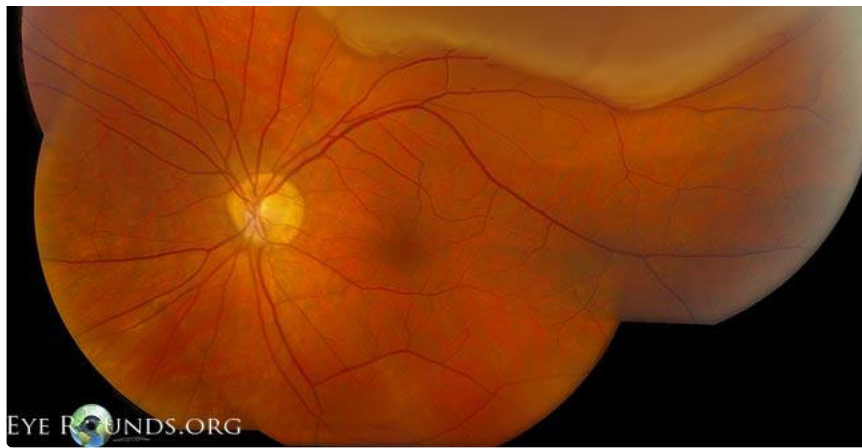## Figure 2

Category(ies): Retina, Vitreous

Contributor: [Jesse Vislisel, MD](#)

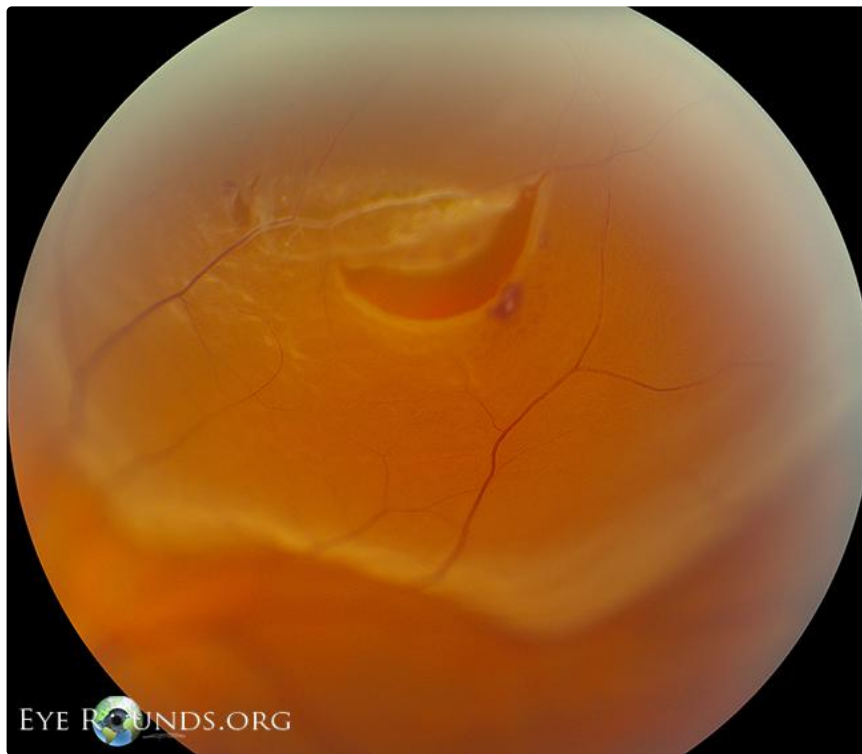Photographer: Cindy Montague, CRA





This photograph shows a superior rhegmatogenous retinal detachment that is not yet involving the macula.

[Enlarge](#) [Download](#)



The second photograph shows a closer view of the primary horseshoe tear with two smaller retinal tears nearby. Lattice degeneration and intraretinal hemorrhages can be seen adjacent to the tears.

[Enlarge](#) [Download](#)

## Figure 3

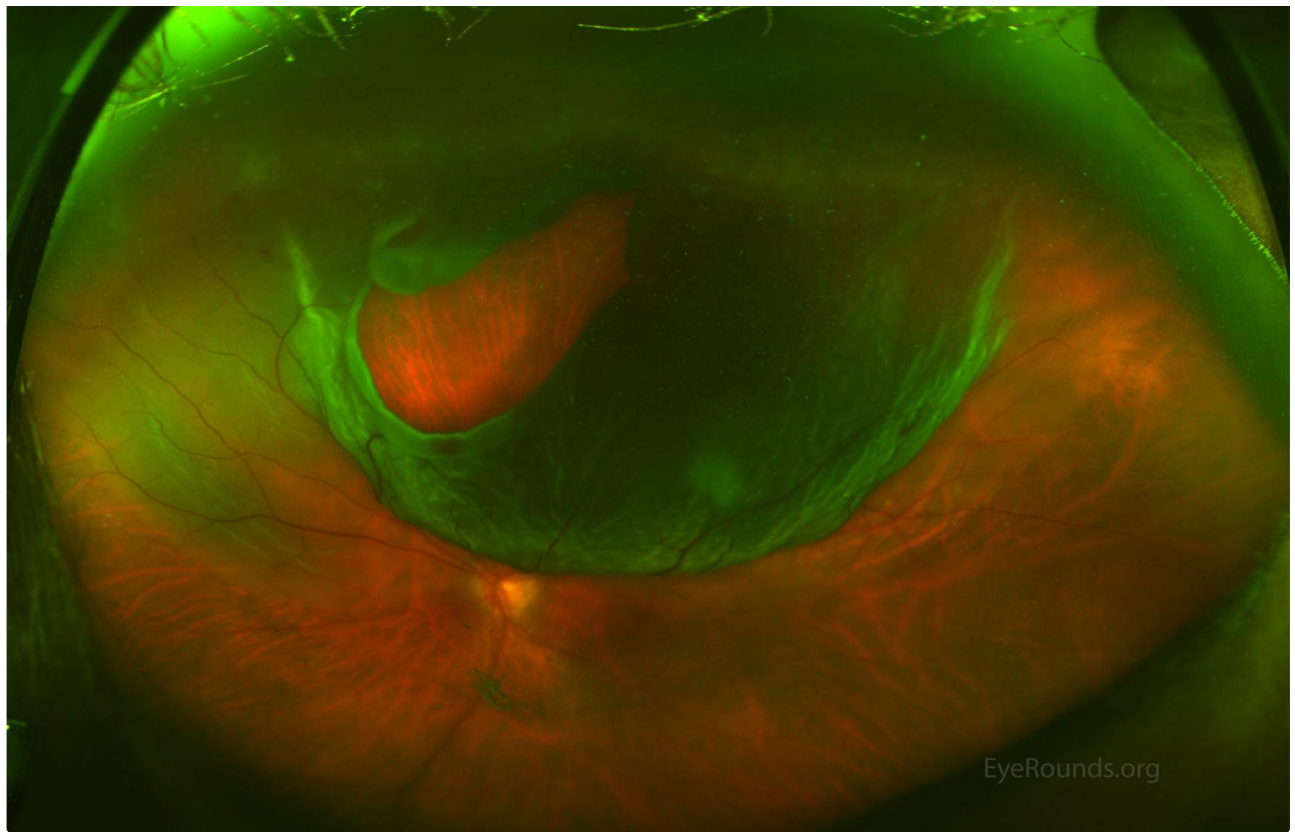
**Category(ies):** Retina, Vitreous

**Contributor:** [Lucas T. Lenci MD](#), Elaine Binkley MD, Jessica Watson MD, Culver Boldt MD

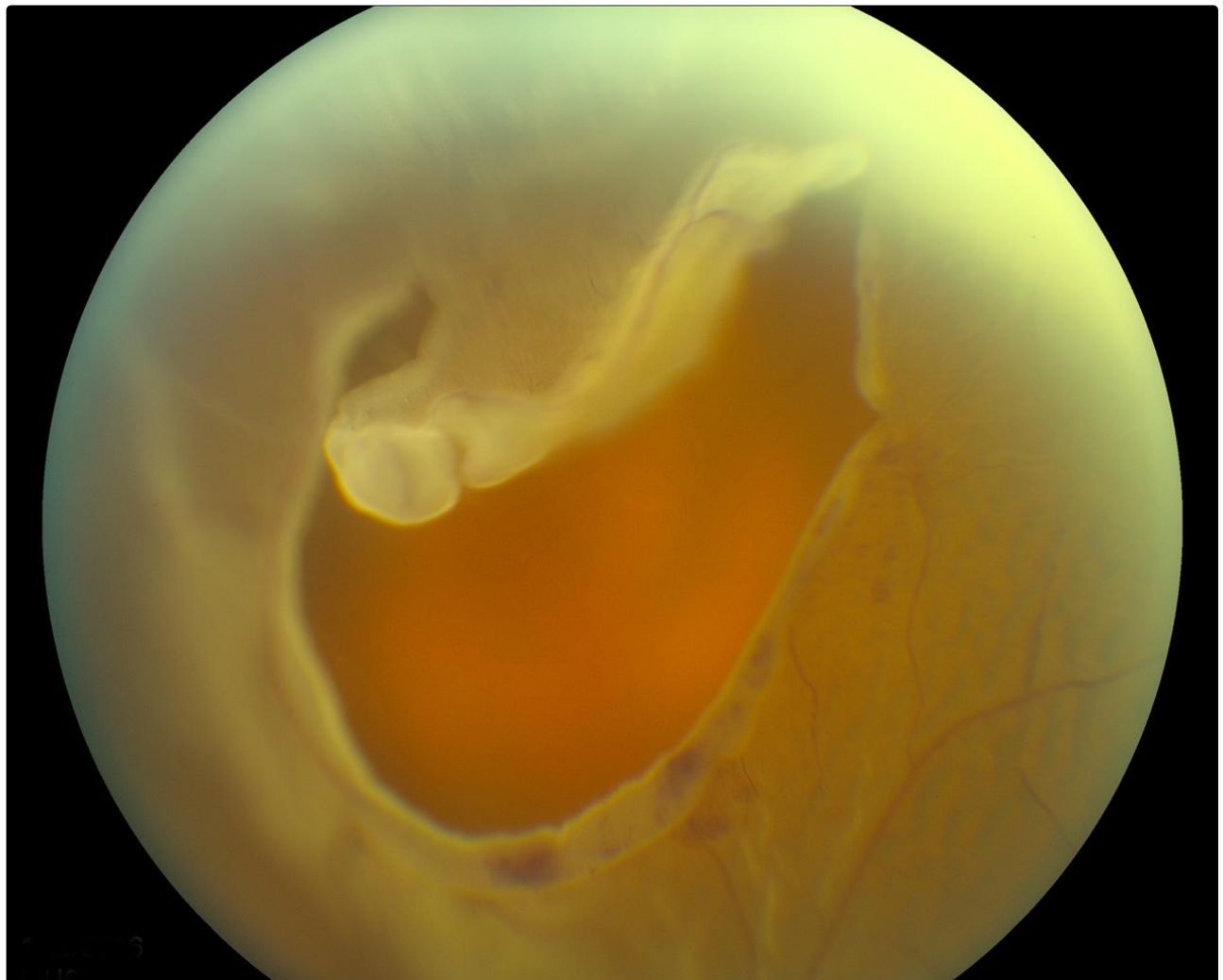
**Photographer:** Brice Critser, CRA

This is a patient who presented with an inferior visual field defect and multiple flashes and floaters. These images demonstrate an excellent example of a large, superior horseshoe tear with a bullous retinal detachment.





[Enlarge](#) [Download](#)



## Figure 4

Category(ies): Retina, Vitreous

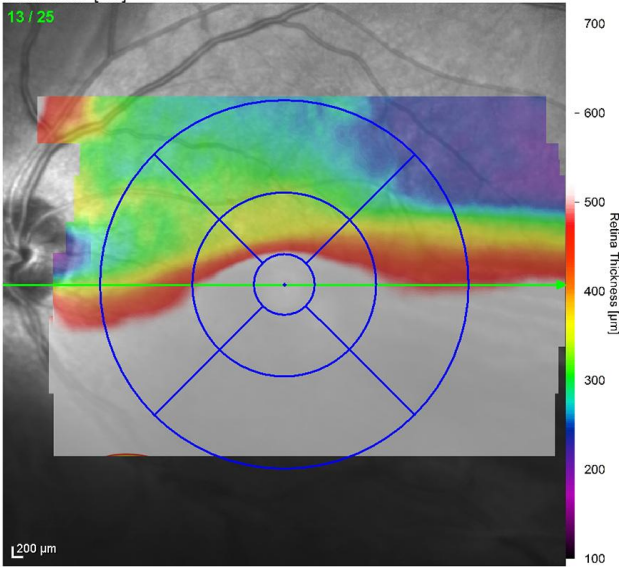
Contributor: [Tressa Larson, OD FAAO](#)

Photographer: Andrea Starkweather

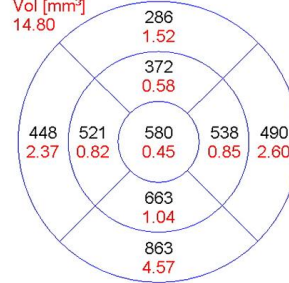
These OCT images show an inferior, macula-off, chronic rhegmatogenous retinal detachment.

IR 30° ART [HS]

13 / 25

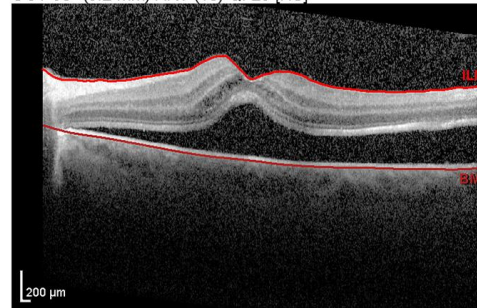


Average Thickness [ $\mu\text{m}$ ]



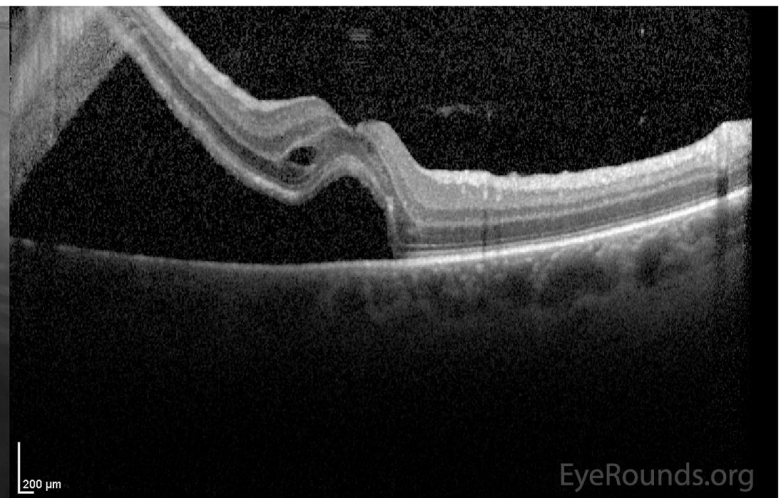
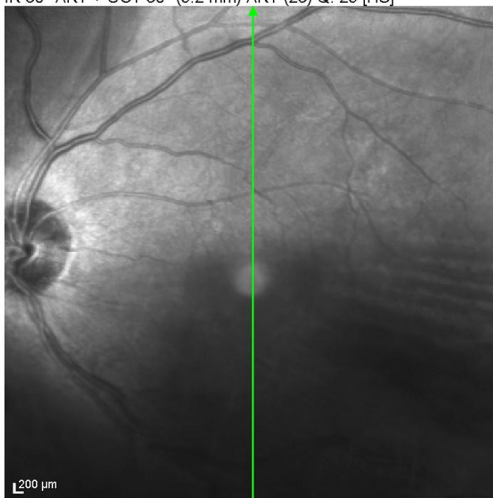
Center: 514  $\mu\text{m}$   
 Central Min: 510  $\mu\text{m}$   
 Central Max: 674  $\mu\text{m}$   
 Circle Diameters: 1, 3, 6 mm ETDRS

OCT 30° (9.2 mm) ART (10) Q: 23 [HS]



EyeRounds.org

IR 30° ART + OCT 30° (9.2 mm) ART (23) Q: 29 [HS]



EyeRounds.org

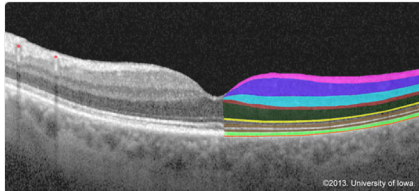
## Image Permissions:



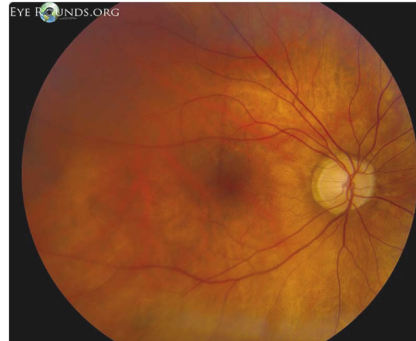
Ophthalmic Atlas Images by [EyeRounds.org](http://EyeRounds.org), [The University of Iowa](http://The University of Iowa) are licensed under a [Creative Commons Attribution-NonCommercial-NoDerivs 3.0 Unported License](https://creativecommons.org/licenses/by-nc-nd/3.0/).



## Related Articles



[Related Tutorial: Retinal Detachment: From One Medical Student to Another](#)



[Related Atlas Entry: Rhegmatogenous Retinal Detachment, Macula-Off](#)

## Address

University of Iowa  
Roy J. and Lucille A. Carver College  
of Medicine  
Department of Ophthalmology and  
Visual Sciences  
200 Hawkins Drive  
Iowa City, IA 52242

[Support Us](#)

## Legal

Copyright © 2019 The University of  
Iowa. All Rights Reserved  
[Report an issue with this page](#)  
[Web Privacy Policy](#) |  
[Nondiscrimination Statement](#)

## Related Links

[Cataract Surgery for Greenhorns](#)  
[EyeTransillumination](#)  
[Gonioscopy.org](#)  
[Iowa Glaucoma Curriculum](#)  
[Iowa Wet Lab](#)  
[Patient Information](#)  
[Stone Rounds](#)  
[The Best Hits Bookshelf](#)

## EyeRounds Social Media

Follow



Receive notification of new cases,  
[sign up here](#)  
[Contact Us](#)  
[Submit a Suggestion](#)