

Recurrent intraocular hemorrhage secondary to cataract wound neovascularization (Swan Syndrome)

John J. Chen MD, PhD; Young H. Kwon MD, PhD

August 6, 2012

Chief complaint: Recurrent vitreous hemorrhage, left eye

History of Present Illness

A 33 year-old male with history of bilateral aphakia s/p intracapsular cataract extraction (ICCE) of dislocated lenses at age 13 presented with recurrent episodes of floaters and blurred vision in the left eye over the past year. These episodes lasted anywhere between one hour and half a day, and were initially once per month but had been increasing in frequency and were occurring at least twice a week at time of initial presentation. He was found to have vitreous hemorrhage on examination by his local eye doctor and was referred to the University of Iowa for further evaluation.

Past Ocular History: Aphakia in both eyes (OU) s/p ICCE for dislocated lenses at the age of 13

Past Medical History:

- Marfan's syndrome
- Hypertension

Medications: metoprolol

Allergies: None

Family History: Marfan's syndrome in his father and son, both have dislocated lenses

Social History: non-contributory

Review of systems: non-contributory

Ocular exam:

Visual acuity:

- Right eye (OD): 20/30-2
- Left eye (OS): 20/50

Pupils: Reactive to light in each eye from 4 mm in the dark to 3 mm in the light. No relative afferent pupillary defect (RAPD).

Extraocular movements: Full OU

Confrontation visual fields: Full OU

Intra-ocular pressure:

- OD: 10 mmHg
- OS: 10 mmHg

Current prescription:

- OD: +11.50+1.00*105 +2.50
- OS: +10.75+0.75*104 +2.50

External

Downslanting palpebral fissures and malar hypoplasia

Slit lamp exam:

- Lids/Lashes: Normal
- Conjunctiva/Sclera: Inadvertent bleb superiorly OD, ICCE scar superiorly OS (Figure 1)
- Cornea: Clear
- Anterior Chamber: Deep and Quiet
- Iris: Iridodonesis, patent peripheral iridotomy superiorly OU
- Lens: Aphakia OU
- Vitreous: Normal

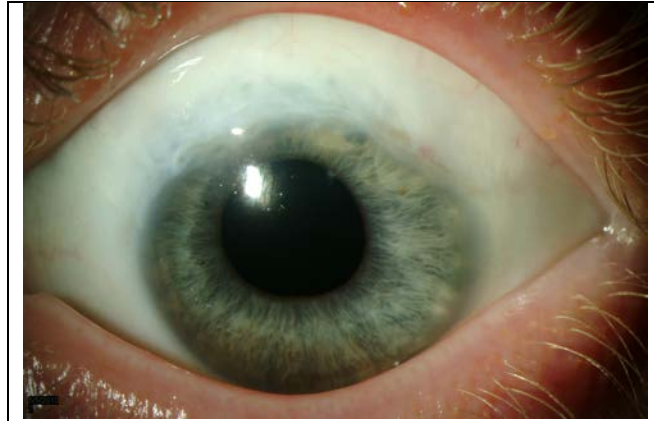


Figure 1: Slit lamp photograph of the left eye demonstrating the ICCE scar superiorly and a hint of vessels superotemporally within the wound.

Dilated fundus exam

The optic nerves appeared healthy with a 0.3 cup-to-disc ratio. The maculae were normal OU. The vessels were normal. There was patches of lattice inferiorly OD and vitreous hemorrhage inferiorly OS obscuring the view of the inferotemporal retina.

Initial clinical course

Because of the concern for a possible tear and rebleeding from bridging retinal vessels underneath the vitreous hemorrhage inferotemporally OS, the patient underwent cryotherapy OS to the inferotemporal retina. One month later, he continued to have recurrent vitreous hemorrhages OS.

The patient was told to come in during an episode of bleeding for examination while he was symptomatic. During his next episode, he was found to have bleeding into the anterior chamber from a posterior wound gap within the old cataract wound OS. On gonioscopy, the abnormal vessels were seen superotemporally within the prior ICCE wound and deemed the source of bleeding (Figure 2).

Diagnosis: Recurrent bleeding from cataract wound neovascularization (Swan syndrome)

Discussion:

Recurrent intraocular bleeding from a prior cataract wound was first described by Swan in 1973 (Swan, 1973). Since that time, there has been a handful of case reports and case series describing this entity (Banitt et al., 2009; Bene et al., 1989; Benson et al., 1978; Jarstad and Hardwig, 1987; Watzke, 1974, 1980). Intraocular hemorrhage can occur months to years after uncomplicated cataract surgery involving a scleral incision due to wound neovascularization (Bene et al., 1989). Following intracapsular cataract extraction, bleeding from these abnormal blood vessels can result in hyphema and/or vitreous hemorrhage in patients with aphakia, whereas following extracapsular cataract extraction, bleeding from wound neovascularization typically results in hyphema alone, unless the posterior capsule or zonules are compromised.




Figure 2: Gonioscopy image OS of the superotemporal angle demonstrating abnormal vessels within the prior ICCE wound.

Patients generally present with intermittent visual loss generally lasting on the order of hours, but can last days. Intraocular hemorrhages may be precipitated by minor trauma or straining, but can be completely spontaneous. In rare cases, the visual loss can be accompanied by painful hemolytic glaucoma or angle closure glaucoma (Bene et al., 1989). Symptoms are typically unilateral, but bilateral cases have been reported (Banitt et al., 2009).

The abnormal vascularization appears to arise from an extension of episcleral vessels into the cataract wound, likely due to poor wound apposition (Bene et al., 1989; Jarstad and Hardwig, 1987; Swan, 1973). Postmortem studies suggest focal abnormal vascularization of the cataract wound is not a rare sequelae of cataract surgery involving scleral incisions (Jarstad and Hardwig, 1987). However, neovascularization of the wound has not been reported in clear corneal incisions (Banitt et al., 2009).

A careful dilated retinal examination must be performed to rule out vitreous traction, retinal tear, or retinal vascular disease. Gonioscopy will ultimately provide the diagnosis, which reveals wound neovascularization at the prior scleral incision. Rocking or manipulation of the gonioscopy lens may provoke bleeding and aid in the diagnosis (Watzke, 1974). Gonioscopy fluorescein angiography can also be used to establish the diagnosis (Watzke, 1974).

The first line treatment is focal argon laser photocoagulation through a gonioscopy lens. Generally, short pulses with high intensity are used to blanch the abnormal blood vessels (Bene et al., 1989). Retreatment may be necessary because episcleral vessels often regrow leading to recurrences (Watzke, 1980). If laser photocoagulation is unsuccessful, the wound can be surgically reopened

and treated with direct diathermy, cryopexy, or surgical excision of the blood vessels (Swan, 1973; Watzke, 1980). We successfully treated our patient with limbal sutures across the cataract wound (see below).

Because abnormal neovascularization of the wound does not occur in clear corneal incision cataract extraction, the incidence of Swan syndrome will likely be reduced in the future. Nevertheless, keeping this increasingly rare entity in mind can be helpful in diagnosing late intraocular hemorrhages in patients that have previously undergone intraocular surgeries involving scleral incisions.

Clinical course

The patient underwent argon laser photocoagulation through a gonioscopy lens, but had minimal improvement in his symptoms. He then underwent wound revision with cautery to the limbal vessels and had a mild improvement. Because he continued to have significant intraocular hemorrhages, we placed multiple 10-0 nylon limbal sutures across the gap within the cataract wound to help approximate the wound and prevent recurrences of bleeding (Figure 3). Although this created a large degree of astigmatism, the procedure successfully stopped the recurrent hemorrhages. After two years of quiescence, he recently developed a few episodes of recurrent bleeding, but much less frequently than his initial presentation. We are currently observing given the infrequency of the hemorrhages.

Differential Diagnosis of Vitreous Hemorrhage

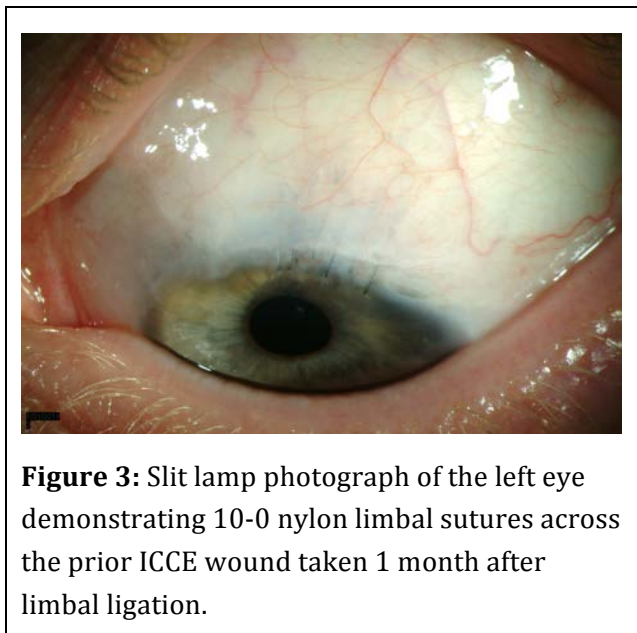
Retinal neovascularization (ex. diabetic retinopathy, central retinal vein occlusion, etc.), retinal tear +/- retinal detachment, vitreous traction/posterior vitreous detachment, trauma, intraocular lens chafing (with violated posterior capsule or zonules)

Epidemiology:

- Presents months to years following cataract surgery involving a scleral incision.

Symptoms:

- Blurred vision and floaters generally lasting on the order of hours, but can last days.
- Occasionally accompanied by pain if there is an increase in intraocular pressure.



Signs:

- Hyphema or vitreous hemorrhage.
- Gonioscopy shows wound neovascularization.
 - Rocking or manipulation of the gonioscopy lens may provoke bleeding and aid in the diagnosis.

Treatment:

- Focal argon laser photocoagulation: blanch all abnormal vessels
 - Typically 100-200 micron spot size, 0.2s duration, 600-700 milliwatts in order to achieve a white tissue reaction.
- Direct diathermy or cryopexy of the blood vessels
- Surgical excision of the vessels
- Limbal sutures to close the cataract wound gap

References:

Banitt, M.R., Rand, A., Vann, R.R., and Gedde, S.J. (2009). Bilateral intraocular hemorrhage from vascularization of cataract wounds. *J Cataract Refract Surg* 35, 1637-1639.

Bene, C., Hutchins, R., and Kranias, G. (1989). Cataract wound neovascularization. An often overlooked cause of vitreous hemorrhage. *Ophthalmology* 96, 50-53.

Benson, W.E., Karp, L.A., Nichols, C.W., Crandall, A.S., and Frayer, W.C. (1978). Late hyphema due to vascularization of the cataract wound. *Ann Ophthalmol* 10, 1109-1112.

Jarstad, J.S., and Hardwig, P.W. (1987). Intraocular hemorrhage from wound neovascularization years after anterior segment surgery (Swan syndrome). *Can J Ophthalmol* 22, 271-275.

Swan, K.C. (1973). Hyphema due to wound vascularization after cataract extraction. *Arch Ophthalmol* 89, 87-90.

Watzke, R.C. (1974). Intraocular hemorrhage from wound vascularization following cataract surgery. *Trans Am Ophthalmol Soc* 72, 242-252.

Watzke, R.C. (1980). Intraocular hemorrhage from vascularization of the cataract incision. *Ophthalmology* 87, 19-23.