

(<http://medicine.uiowa.edu/eye/>)

 Search

Ophthalmology and Visual Sciences
(<http://medicine.uiowa.edu/eye/>)

Eye  Rounds.org

([./index.htm](http://medicine.uiowa.edu/eye/./index.htm))

Fabry disease

A key differential in the diagnosis of corneal verticillata

Anthony T. Chung, MD ([./bio/authors/Chung-Anthony.htm](http://medicine.uiowa.edu/eye/./bio/authors/Chung-Anthony.htm)); Thomas A. Oetting, MS, MD ([./bio/authors/Oetting-Thomas.htm](http://medicine.uiowa.edu/eye/./bio/authors/Oetting-Thomas.htm))

posted June 15, 2017

INITIAL PRESENTATION

Chief Complaint

Slow decline in vision over 2 years

History of Present Illness

57-year-old Caucasian female with known history of heterozygous Fabry disease diagnosed in 2005, initially presented asymptotically at the age of 46 with bilateral corneal verticillata, early cataracts, and vascular tortuosity. Her primary care provider noted that she had a history of numbness and tingling of her hands and feet that resolved in early adulthood, proteinuria, hypertension, and asymptomatic left ventricular hypertrophy. She subsequently was lost to follow up with ophthalmology until 2017 when she presented with increasing blurry vision with reading and distance over the past 2 years. The patient reports that her last eye exam was 7 years ago and has been wearing the same prescription since.

Past Ocular History

No other ocular history

Past Medical History

- Chronic kidney disease, stage 2
- Left ventricular hypertrophy

- Hypertension
- Alcoholism

Medications

- Acetaminophen
- Agalsidase beta
- Albuterol
- Aspirin
- Folic acid
- Lisinopril
- Lorazepam
- Metoprolol
- Multivitamin
- Spironolactone
- Thiamine

Allergies

None

Family History

Father passed away from renal failure secondary to Fabry disease

Social History

Non-contributory

Review of Systems: Negative

OCULAR EXAMINATION

Visual Acuity with correction (Snellen)

- Right eye (OD): 20/60-1
- Left eye (OS): 20/50-1

Other Visual Acuity Tests (Manifest refraction)

- OD: 20/20
- OS: 20/20

Ocular Motility/Alignment

Normal and full

Intraocular Pressure (IOP) (Tonopen)

- OD: 12 mm Hg
- OS: 12 mm Hg

Pupils

- OD: 3 mm in dark, 2 mm in light, no RAPD
- OS: 3 mm in dark, 2 mm in light, no RAPD

Confrontation visual fields

Full

External

Normal

Slit lamp exam

- Lids/lashes: Normal
- Conjunctiva/sclera: Normal
- Cornea: Verticillata both eyes (OU)
- Anterior chamber: Deep and quiet
- Iris: Normal architecture
- Lens: 1+ nuclear sclerosis cataract, 1+ cortical cataract

Dilated fundus examination (DFE)

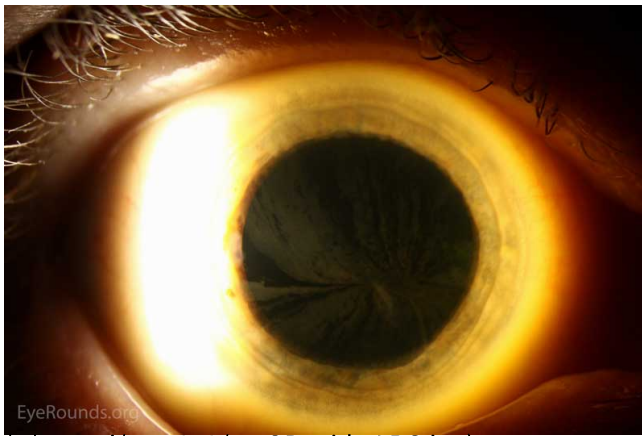
- **Vitreous:** Clear
- **Disc:** Pink, crisp margins
- **Cup-to-disc ratio:** 0.4
- **Macula:** Normal
- **Vessels:** Normal
- **Periphery:** Normal

Differential Diagnosis

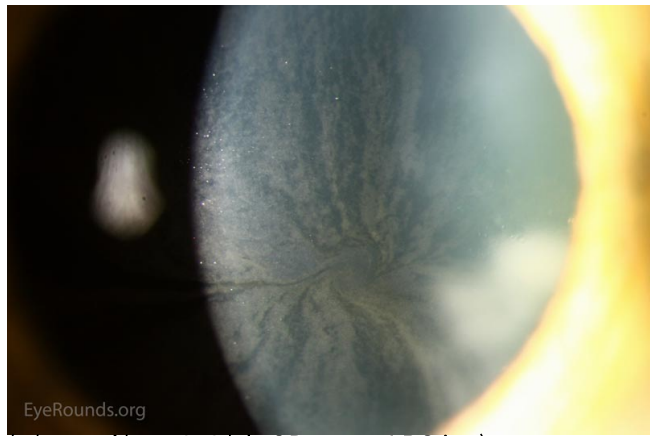- Amiodarone (Read the related case report for more information on cornea verticillata (case29.htm))
- Chloroquine and hydroxychloroquine
- Indomethacin
- Phenothiazines

Clinical course

The increase in blurry vision that was attributed to progression of her cataracts. The patient's BCVA was 20/20 OU with manifest refraction and the decision was made to observe her cataracts. She was provided a prescription for new glasses and recommended follow up in 1 year with continued follow up with her primary care provider, nephrology, and cardiology as scheduled.

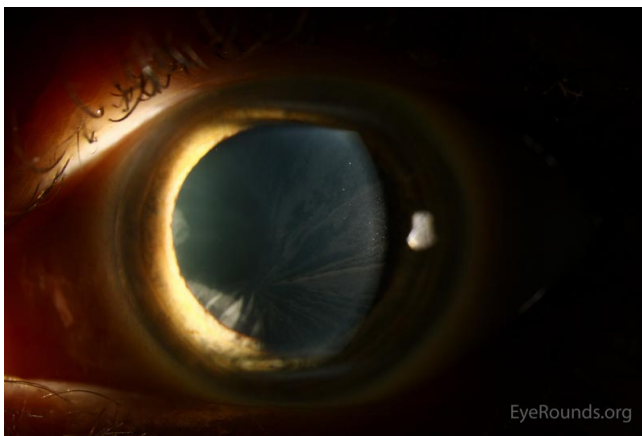

(../cases-i/case253/1a-OD-wide-LRG.jpg)

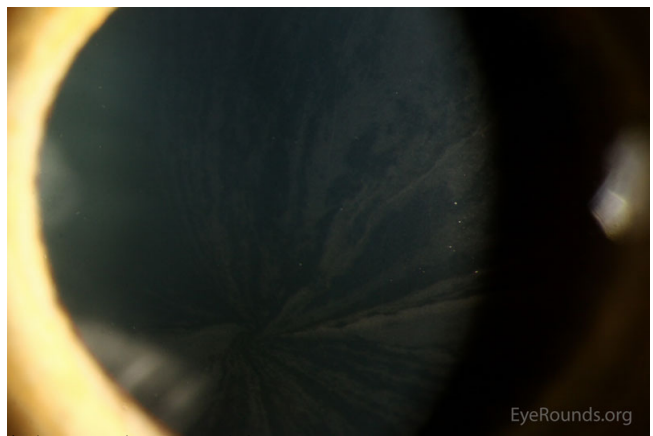


(../cases-i/case253/1b-OD-zoom-LRG.jpg)

Figure 1: Slit lamp photos of the right eye exhibiting the whorled pattern of corneal verticillata



(../cases-i/case253/2a-OS-wide-LRG.jpg)



(../cases-i/case253/2b-OS-zoom-LRG.jpg)

Figure 2: Slit lamp photos of the left eye exhibiting the whorled pattern of corneal verticillata

DISCUSSION

Fabry disease is an X-linked dominant condition that affects 1 in 40,000 to 60,000 males. The prevalence in females is unknown. [1] Fabry disease results from mutations in the GLA gene encoding alpha-galactosidase A. The inability to metabolize glycosphingolipids causes a buildup in globotriaosylceramide in the cells found in nerves, vasculature, and other tissues including the cornea. This is a systemic disease that commonly presents as numbness and tingling of the hands and feet (acroparesthesias), skin lesions (angiokeratomas), decreased sweating (hypohidrosis), gastrointestinal dysfunction, kidney dysfunction, heart disease, vascular disease, and the following ophthalmic findings: corneal verticillata and vascular tortuosity. [2]

Corneal verticillata was first reported by Gruber in 1946 but it was not until 1969 when verticillata was attributed to Fabry disease by Franceschetti et al. [3,4] Corneal verticillata are also associated with many medications that cause subepithelial deposits and rarely cause visual disturbances. The following medications have been associated with corneal verticillata: amiodarone, chloroquine, hydrochloroquine, indomethacin, and phenothiazines. These often present bilaterally and will typically resolve following cessation of these medications.[5]

Diagnosis in males in the setting of positive signs, symptoms, and family history can be completed by measuring the level of alpha-Gal A activity in leukocytes or plasma. Affected males will often have little to no detectable levels of alpha-Gal A. However, atypical presentations or marginal levels of alpha-Gal A in both males and females may require genetic testing to confirm the diagnosis. Genetic testing is not necessary in females with a positive history of Fabry disease in her father, thus making females obligate heterozygotes (as is the case with our patient).[6] Treatment of Fabry disease with enzyme replacement therapy (agalsidase beta) should be started as soon as low levels of alpha-Gal A are detected, even in the absence of systemic symptoms. These patients should be followed by ophthalmology, nephrology, cardiology, neurology, and dermatology due to systemic manifestations of the disease.[7]

<p>EPIDEMIOLOGY / ETIOLOGY</p> <ul style="list-style-type: none"> • X-linked dominant • Mutation in GLA gene encoding alpha-galactosidase A • Affects 1 in 40,000-60,000 males • Prevalence in females is unknown • Results in accumulation of globotriaosylceramide in various tissues 	<p>SIGNS</p> <ul style="list-style-type: none"> • Corneal verticillata • Vascular tortuosity • Proteinuria
<p>SYMPTOMS</p> <ul style="list-style-type: none"> • Numbness/tingling of the hands and feet (acroparesthesias) • Skin findings (angiokeratomas) • Renal disease • Hypertension • Stroke 	<p>TREATMENT/MANAGEMENT</p> <ul style="list-style-type: none"> • Enzyme replacement therapy (agalsidase beta)

References

- Fabry disease. *Genetics Home Reference*, U.S. National Library of Medicine. 2017. Updated February 2012 (Accessed May 5, 2017); Available from <https://ghr.nlm.nih.gov/condition/fabry-disease/> (<https://ghr.nlm.nih.gov/condition/fabry-disease/>)
- #301500: Fabry Disease [MIM 301500]. *Online Mendelian Inheritance in Man, OMIM®*. Johns Hopkins University, Baltimore, MD. Updated June 9, 2015 (Accessed May 5, 2017); Available from <https://www.omim.org/entry/301500> (<https://www.omim.org/entry/301500>)
- Gruber M. Cornea verticillata. (Eine einfach-dominante Variante der Hornhaut des menschlichen Auges). *Ophthalmologica* 1946; 111(2-3):120-129. PMID 20275792 <<https://pubmed.gov/20275792>>
- Franceschetti AT, Philippart M, Franceschetti A. A study of Fabry's disease. I. Clinical examination of a family with cornea verticillata. *Dermatologica* 1969;138(4): 209-221. PMID 5771636 <<https://pubmed.gov/5771636>>
- Graff JM. Verticillata: 54-year-old white male with a known history of atrial fibrillation and hypertension on amiodarone. *EyeRounds.org*, February 21, 2005 (Accessed May 5, 2017); Available from <http://www.EyeRounds.org/cases/case29.htm> (<http://www.EyeRounds.org/cases/case29.htm>)
- Mauer M. Clinical features and diagnosis of Fabry disease. In: *UpToDate*, Post TW (Ed), Waltham, MA: UpToDate. Updated October 21, 2014 (Accessed on May 5, 2017); Available from <https://www.uptodate.com/contents/clinical-features-and-diagnosis-of-fabry-disease> (<https://www.uptodate.com/contents/clinical-features-and-diagnosis-of-fabry-disease>)

- Mauer M. Treatment of Fabry disease. In: *UpToDate*, Post TW (Ed), Waltham, MA: UpToDate. Updated October 20, 2014 (Accessed on May 5, 2017); Available from <https://www.uptodate.com/contents/treatment-of-fabry-disease> (<https://www.uptodate.com/contents/treatment-of-fabry-disease>)

Suggested Citation Format

Chung AT, Oetting TA. Fabry disease. EyeRounds.org. June 15, 2017. Available from <http://EyeRounds.org/cases/253-Fabry-Disease.htm>

last updated: 06/15/2017

Share this page:

University of Iowa Carver College of Medicine
Department of Ophthalmology & Visual Sciences
200 Hawkins Dr.
Iowa City, IA 52242

Web Privacy Policy (<http://www.uiowa.edu/homepage/online-privacy-information>) | Nondiscrimination Statement
(<http://opsmanual.uiowa.edu/community-policies/nondiscrimination-statement>)



Directory (<https://www.dna.its.uiowa.edu/Whitepages/>) | **A-Z Search** (<http://www.uiowa.edu/a-z>) | **About Iowa** (<http://www.uiowa.edu/homepage/about-university>) | **Contact Us** (<http://www.uiowa.edu/homepage/about-university>) | **Calendars** (<http://www.uiowa.edu/homepage/calendars>) | **Privacy Information** (<http://www.uiowa.edu/homepage/online-privacy-information>)

copyright ©2016 The University of Iowa.