

Spinocerebellar Ataxia with Ophthalmoplegia:

46-y.o. male presenting with progressive esotropia

Brian K Privett, M.D., Randy Kardon, M.D.

History of Present Illness: Patient, a 46 year old male, presented for follow up of a long-standing progressive esotropia (ET). In 1986, he presented with 14 prism diopters of ET and was noted to have bilateral abduction deficits.

In 1994, he was seen by a neuro-ophthalmologist. It was noted that he was wearing 3 prism diopters of base out prism in his glasses. He had 36 prism diopters of ET, but no diplopia. Worth 4 dot testing showed that he was suppressing his left eye. He continued to have bilateral abduction deficits now with slow saccades of the lateral recti and end gaze nystagmus with lateral gaze. The patient brought in old photos at a follow-up exam which showed no ET as a child.

He had been followed for several years for long-standing ET, but was never given a firm diagnosis. At his last visit in 2008, he had stopped wearing prisms because they were of no help to him. He still had no diplopia.

PMH/FH/POH: Patient carried a diagnosis of primary progressive cerebellar ataxia. He reported being very clumsy as a teenager. In 1972, he developed ataxia. In 1989, an MRI of the brain revealed cerebellar and medullary atrophy. Based on this MRI and lack of family history, he was given a diagnosis of primary progressive cerebellar ataxia. He knows very little of his parent's medical history and has no siblings or children.

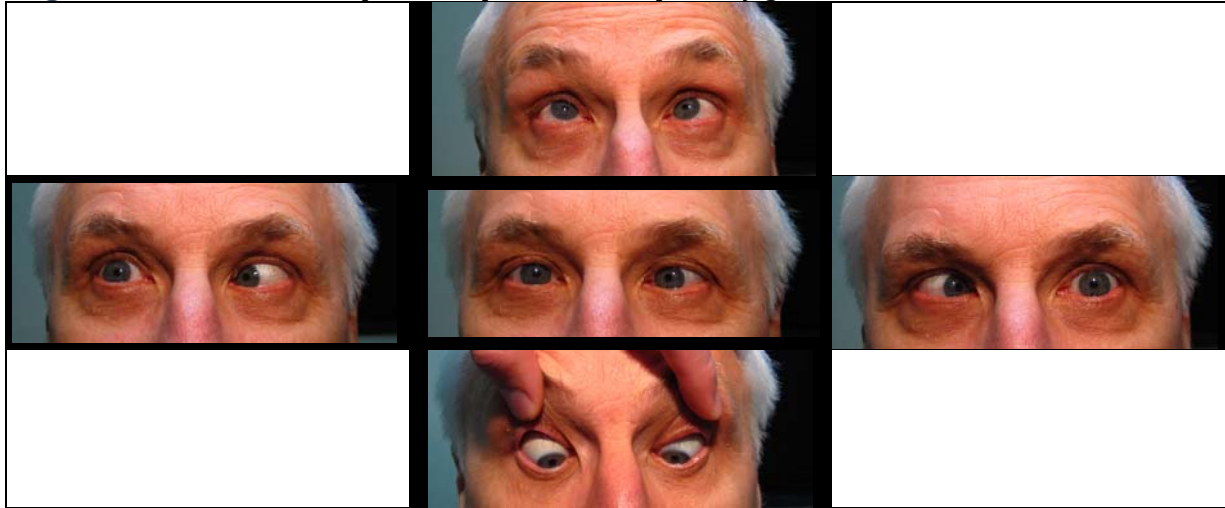
OCULAR EXAM:

- Visual acuity was 20/20 in the right eye (OD) and 20/25 in the left eye (OS)
- Pupil exam normal
- Visual field by confrontation normal
- Intra-ocular pressure normal
- Extraocular motility revealed 52 prism diopters of ET in primary gaze. There was a -3 abduction deficit OD and a -3 abduction deficit OS. He had end gaze nystagmus with lateral gaze.
- With Worth-4-Dot testing, he appeared to ignore the left image. A large base out prism caused him to see two images.
- Anterior Segment normal
- Dilated fundus exam normal

NEUROLOGIC EXAM:

- Dysdiadokinesis on finger-to-nose testing
- Ataxic gait
- Dysarthria

Figure 1-5: Patient had 52 prism diopters of ET in primary gaze with bilateral abduction deficits.



Video 1: Extraocular movements. Note the bilateral abduction deficits and end gaze nystagmus on lateral gaze.

Video 2: Dysdiadokinesia with finger-to-nose testing

Video 3: Ataxic gait

Video 4: Dysarthria

View all videos online at <http://www.EyeRounds.org/cases/109-SCA.htm>.

Discussion

This gentleman originally presented in 1986 with progressive esotropia. Since that time, there have been multiple publications linking spinocerebellar ataxia to disorders of extraocular movements and vergence. This gentleman was relieved to hear that his long-standing esotropia was likely related to his spinocerebellar ataxia. Despite his negative family history, it is possible that one of his parents could have carried a milder form of the disease due to “anticipation” (see below for explanation).

It was discussed with him that he could undergo strabismus surgery if he liked, however his esotropia would likely continue to progress. This would likely cause diplopia, which he currently did not have secondary to ignoring. He was seen one year later in follow up after this exam. His ET was stable.

Diagnosis: Spinocerebellar ataxia with ophthalmoplegia

There are at least 30 different types of spinocerebellar ataxias (SCA) also referred to as autosomal dominant cerebellar ataxias (ADCA). These are divided into three categories based on their typical presentation (See Table 2 below). The number of ADCAs increases each year as more protein products are genotyped (1).

Several of the SCAs have known protein products such as ataxin-1 which is responsible for SCA 1. Most SCA mutations involve CAG nucleotide repeats resulting in protein products with large polyglutamine domains. These proteins tend to aggregate and form inclusions. These inclusions have a toxic effect. CAG repeats are unstable leading to de novo mutations that can occur during transmission and cause trinucleotide repeat expansion. This leads to “anticipation” meaning that the phenotypical expression can increase between generations (2,3). It is important to remember

when patients present with apparent sporadic disease, their parents may have had a less severe form of the disease.

The most prevalent SCA worldwide is SCA3 also known as Machado-Joseph Disease. This disease was named for two families of Portuguese and Azorean descent described in the 1970s. The prevalence is 1 in 4000 among Portuguese and 1 in 140 on the Azorean island of Flores. It has been associated with a higher incidence of diplopia and ophthalmoplegia than other SCAs (4).

Cerebellar disease can cause multiple disorders of ocular motility. Recently there has been clear evidence of impairment of vergence eye movements in SCA3. The anatomical centers that mediate vergence movements are still not completely understood. There is some evidence that the medial nucleus reticularis tegmenti pontis (NRTP) may be involved. Interestingly, the NRTP is contiguous with the paramedian pontine reticular formation (PPRF) which controls lateral gaze (4).

<p>Table 1: Oculomotor Deficits with SCA</p> <p>Slow saccades – SCA1, SCA2, SCA3, SCA7, SCA28 Down-beat nystagmus – SCA6 Ophthalmoplegia – SCA1, SCA2, SCA3, SCA28, SCA30 Ocular dyskinesia – SCA10</p>

Aside from disorders of ocular motility, a characteristic finding of SCA7 is cone-rod dystrophy. Recent evidence suggests that ataxin-7 interacts with CRX which is a nuclear transcription factor predominantly expressed in retinal photoreceptor cells in which a mutation can cause cone-rod dystrophy (5).

Table 2: The Spinocerebellar Ataxias:

<p>Epidemiology</p> <p>Prevalence 1-4 of 400,000 Age of onset varies based on mutation but onset is typically 3rd-4th decade Spinocerebellar Ataxia implies an autosomal dominant pattern. There are several other inherited, sporadic, and acquired causes of cerebellar ataxia (1).</p>	<p>Signs</p> <p>Category I Gait ataxia, limb ataxia, dysarthria ophthalmoplegia, optic atrophy, dementia, extrapyramidal signs. Most SCAs fall into this category. Category II (SCA7) Signs of category I with pigmentary retinopathy Category III Older age of onset, typically >50 “Pure cerebellar” syndrome without other neurologic findings (1)</p>
<p>Symptoms</p> <p>Imbalance with standing Impaired coordination Slurred speech Diplopia</p>	<p>Treatment</p> <p>Limited Some results with 5-hydroxytryptophan, buspirone or tandospirone, sulfamethoxazole/trimethoprim or lamotrigine in SCA3 Strabismus surgery if stable (6)</p>

REFERENCES:

1. Furtado S, Sas S, Suchowersky O, A review of the inherited ataxias: recent advances in genetic, clinical and neuropathologic aspects. *Parkinsonism and Related Disorders* 1998;4(4):161-169.
2. Paulson H, The Spinocerebellar Ataxias. *Journal of Neuro-Ophthalmology* 2009;29:227-237.
3. Honti V, Vécsei L, Genetic and molecular aspects of spinocerebellar ataxias. *Neuropsychiatric Disease and Treatment* 2005;1(2):125-133.
4. Ohyagi Y, Yamada T, Okayama A, Sakae N, Yamasaki T, Ohshima T, Sakamoto T, Fujii N, Kira J, Vergence disorders in patients with spinocerebellar ataxia 3/Machado-Joseph disease: a synoptophore study. *Journal of the Neurological Sciences* 2000;173:120-123.
5. Hugosson T, Lotta G, Ponjavic V, Andreason S, Malar dysfunction and morphology in spinocerebellar ataxia type 7 (SCA 7). *Ophthalmic Genetics* 2009;30:1-6.
6. Manto M, Marmolino D, Cerebellar ataxias. *Current Opinion in Neurology* 2009;22:410-429.

Suggested citation format:

Privett BK, Kardon RH. Spinocerebellar Ataxia with Ophthalmoplegia: 46-y.o. male presenting with progressive esotropia. *EyeRounds.org*. February 16, 2010; Available from: <http://www.EyeRounds.org/cases/109-SCA.htm>.