

(<http://medicine.uiowa.edu/eye/>)

Ophthalmology and Visual Sciences
(<http://medicine.uiowa.edu/eye/>)

Eye  Rounds.org

([./index.htm](http://medicine.uiowa.edu/eye/./index.htm))

Sickle Cell Retinopathy

Prashant K. Parekh, MD, MBA ([./bio/authors/Parekh-Prashant.htm](http://medicine.uiowa.edu/eye/./bio/authors/Parekh-Prashant.htm)), Matthew A. Miller, MD ([./bio/authors/Miller-Matthew.htm](http://medicine.uiowa.edu/eye/./bio/authors/Miller-Matthew.htm)), Stephen R. Russell, MD (http://www.medicine.uiowa.edu/dept_primary_apr.aspx?appointment=Ophthalmology%20and%20Visual%20Sciences&id=russells)

April 6, 2016

Initial Presentation

Chief Complaint:

Blurry vision and new floaters in the left eye.

History of Present Illness

An 18-year-old African-American male with known sickle cell disease is referred to the vitreoretinal service for evaluation of two days of blurry vision and new-onset floaters in the left eye that developed while playing basketball. He denies flashes of light, loss of visual field, eye pain, eye redness, increased light sensitivity, and double vision.

Past Ocular History

None

Past Medical History

Sickle cell disease (SC trait)

Medications

None

Allergies

None

Family History

- Glaucoma (maternal aunt)
- Diabetes mellitus type 2 (father)
- Hypertension (mother)
- No known family history of sickle cell or other hematologic diseases

Social History

The patient is a senior in high school. He smokes both cigarettes and marijuana in social settings.

Review of Systems

Negative for bone pain, fatigue, chest pain, shortness of breath, abdominal pain or other symptom of vaso-occlusive crisis.

OCULAR EXAMINATION

Visual Acuity without correction: (Snellen)

- Right eye (OD): 20/25-1, no improvement with pinhole
- Left eye (OS): 20/150, improves with pinhole to 20/100

Ocular Motility

- Full, both eyes (OU)

Intraocular Pressure (IOP): (Tonopen)

- OD: 13 mmHg
- OS: 13 mmHg

Pupils

- OD: 5 mm in dark, 3 mm in light, no relative afferent pupillary defect (RAPD)
- OS: 5 mm in dark, 3 mm in light, no RAPD

Confrontation visual fields

Full to finger counting OU

Slit lamp exam

- Lids/lashes: Normal OU
- Conjunctiva/sclera: Perilimbal melanosis OU
- Cornea: Clear OU

- Anterior chamber: Deep and quiet without hyphema OU
- Iris: Normal architecture without neovascularization OU
- Lens: Clear OU

Dilated fundus examination OD

- Vitreous: Normal, without hemorrhage
- Disc: Hyperemic and without neovascularization
- Cup-to-disc ratio: 0.2
- Macula: Normal
- Vessels: Inferotemporal neovascularization (i.e., neovascularization of the retina elsewhere (NVE))
- Periphery: Tractional membrane inferotemporally from 7:00 clockwise to 9:00 o'clock with an old neovascular tuft. White without pressure from 12:00 to 5:30 in the mid-periphery.

Dilated fundus examination OS

- Vitreous: Vitreous hemorrhage overlying the disc and macula that is mobile and layers inferiorly
- Disc: Hyperemic; partially obscured by vitreous hemorrhage
- Cup-to-disc ratio: 0.2
- Macula: Flat, obscured by vitreous hemorrhage
- Vessels: Inferotemporal NVE
- Periphery: Tractional membrane from 4:00 clockwise to 5:30 at the ora serrata with small membrane at 11:00. Salmon patches. White without pressure from 4:00 to 10:00 clockwise at the equator.

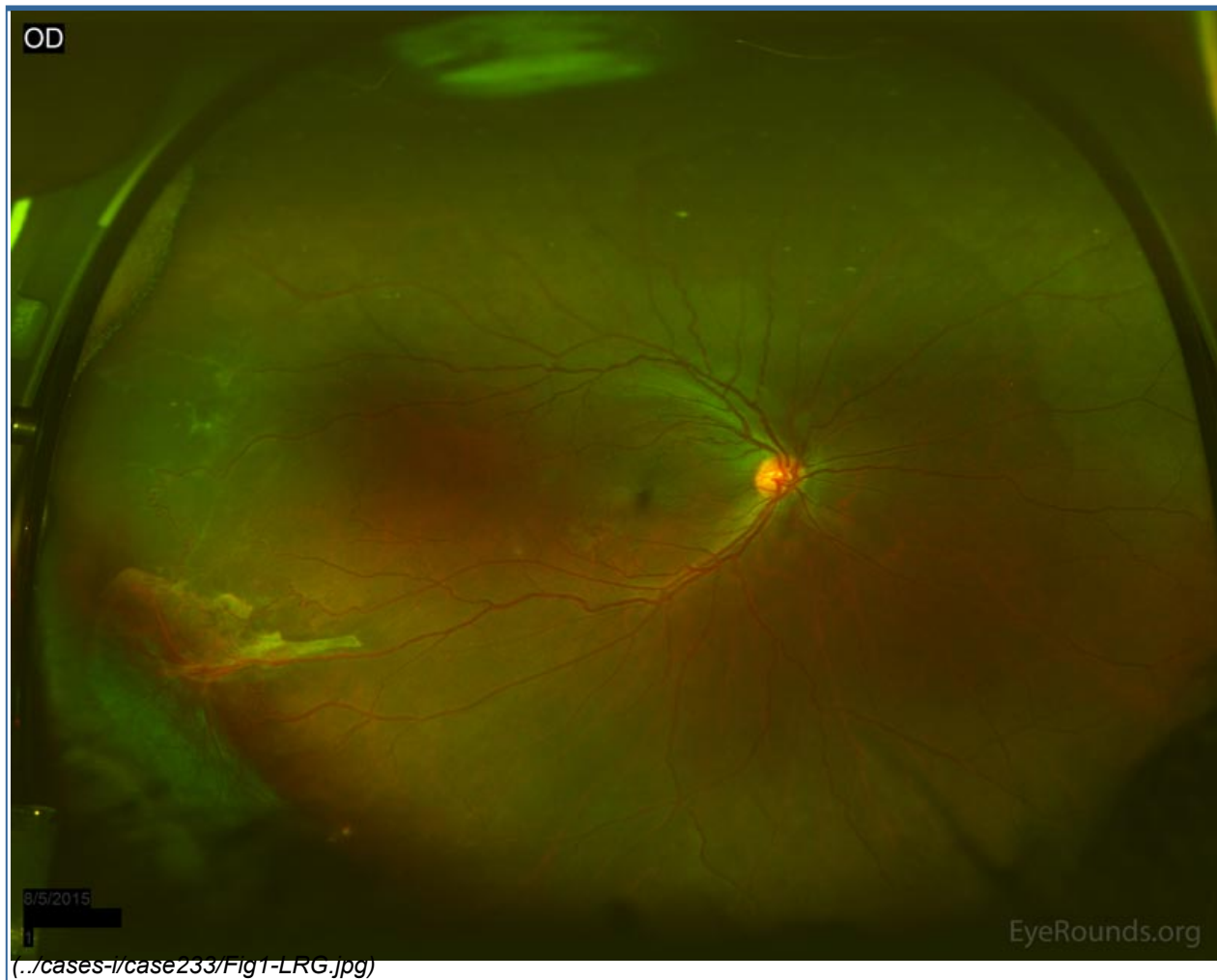


Figure 1: Widefield fundus photo of the right eye demonstrating white membranes and NVE in the far temporal periphery. Tractional membrane inferotemporally from 7:00 clockwise to 9:00 with old neovascular tufts. White without pressure from 12:00 to 5:30 in the mid-periphery.

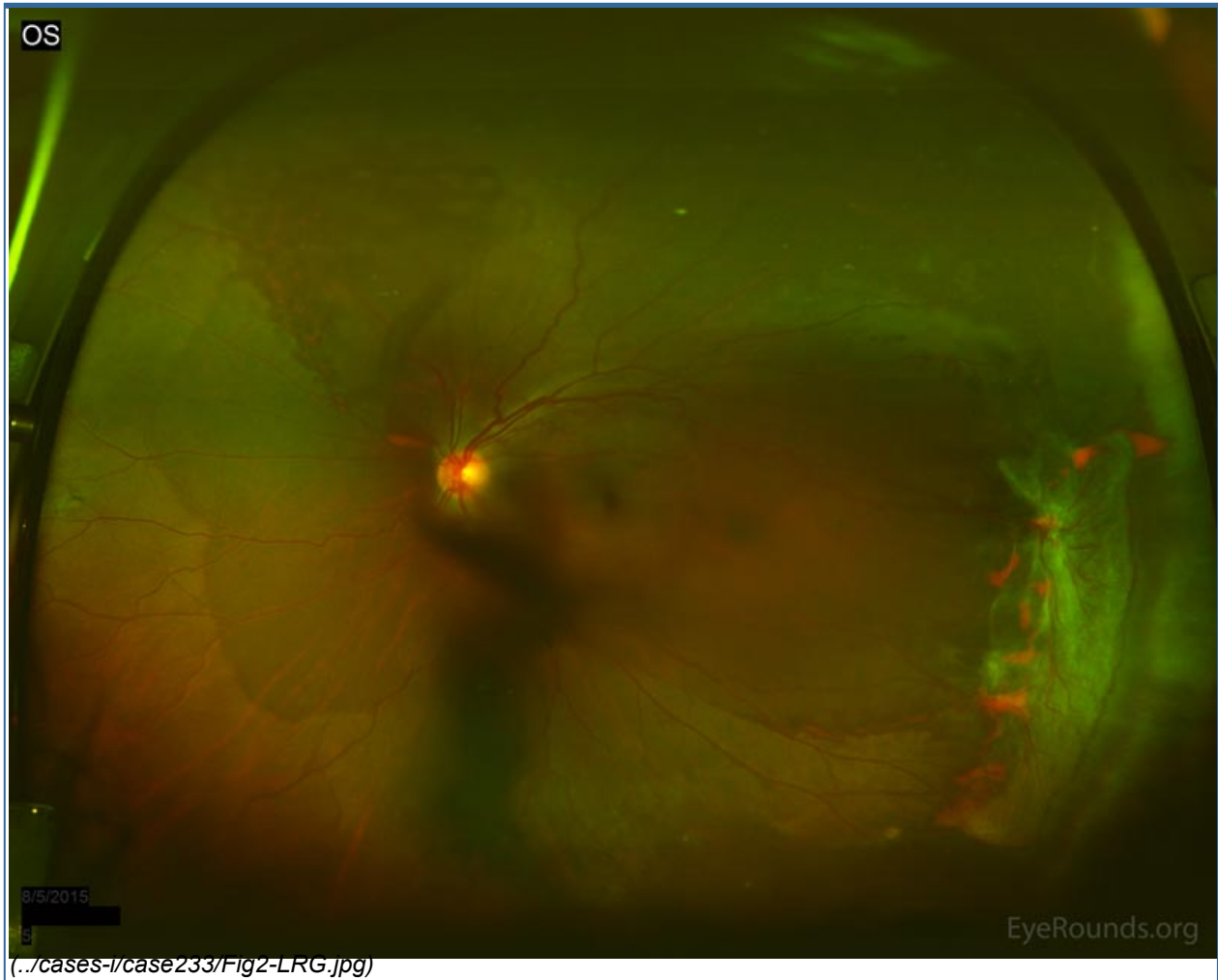

Figure 2: Widefield fundus photo of the left eye demonstrating moderate vitreous hemorrhage overlying the optic nerve. Tractional membrane inferotemporally near the equator with minimal elevation of the retina with associated NVE. White without pressure from 4:00 to 10:00 at the equator.

Additional testing



OS

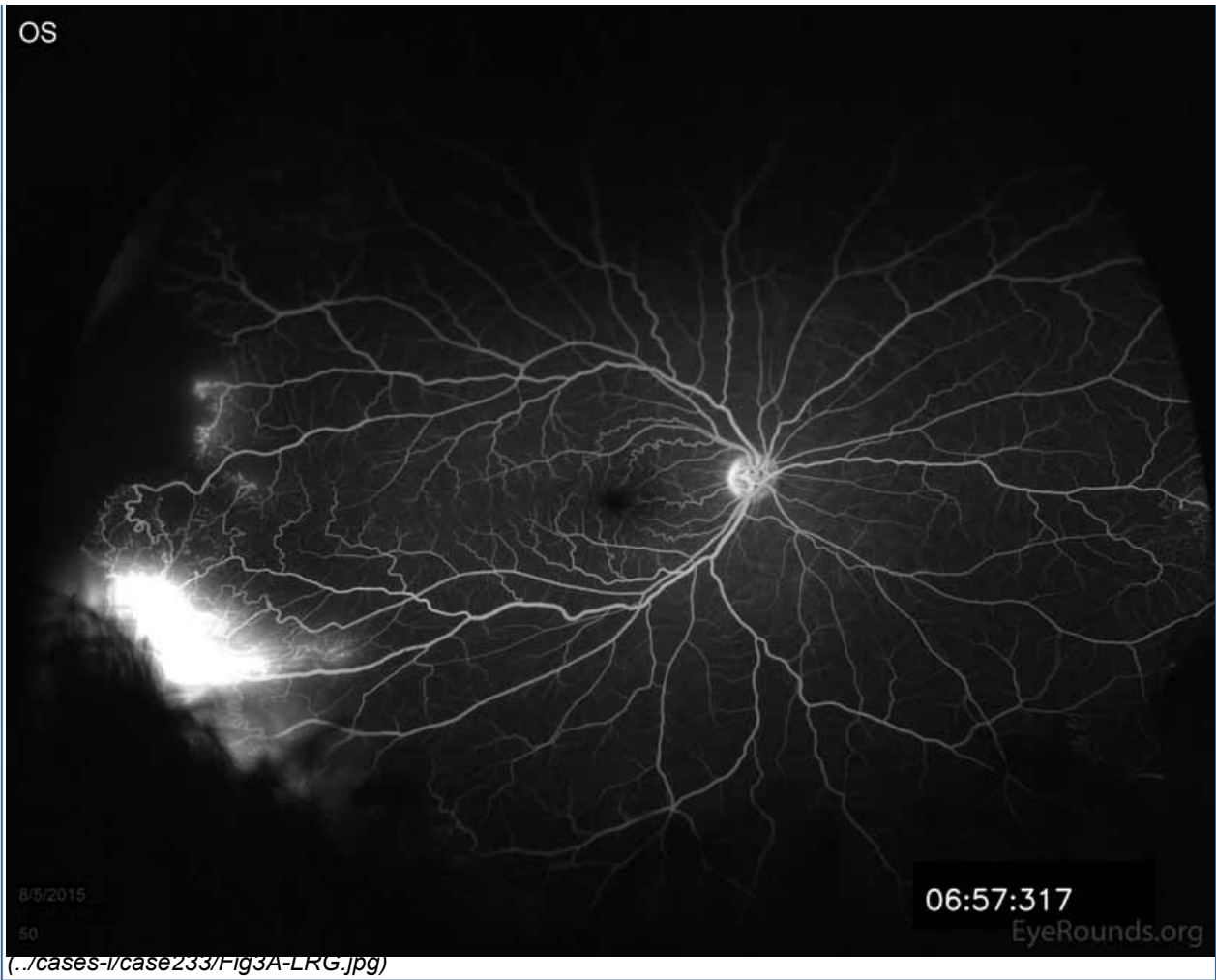
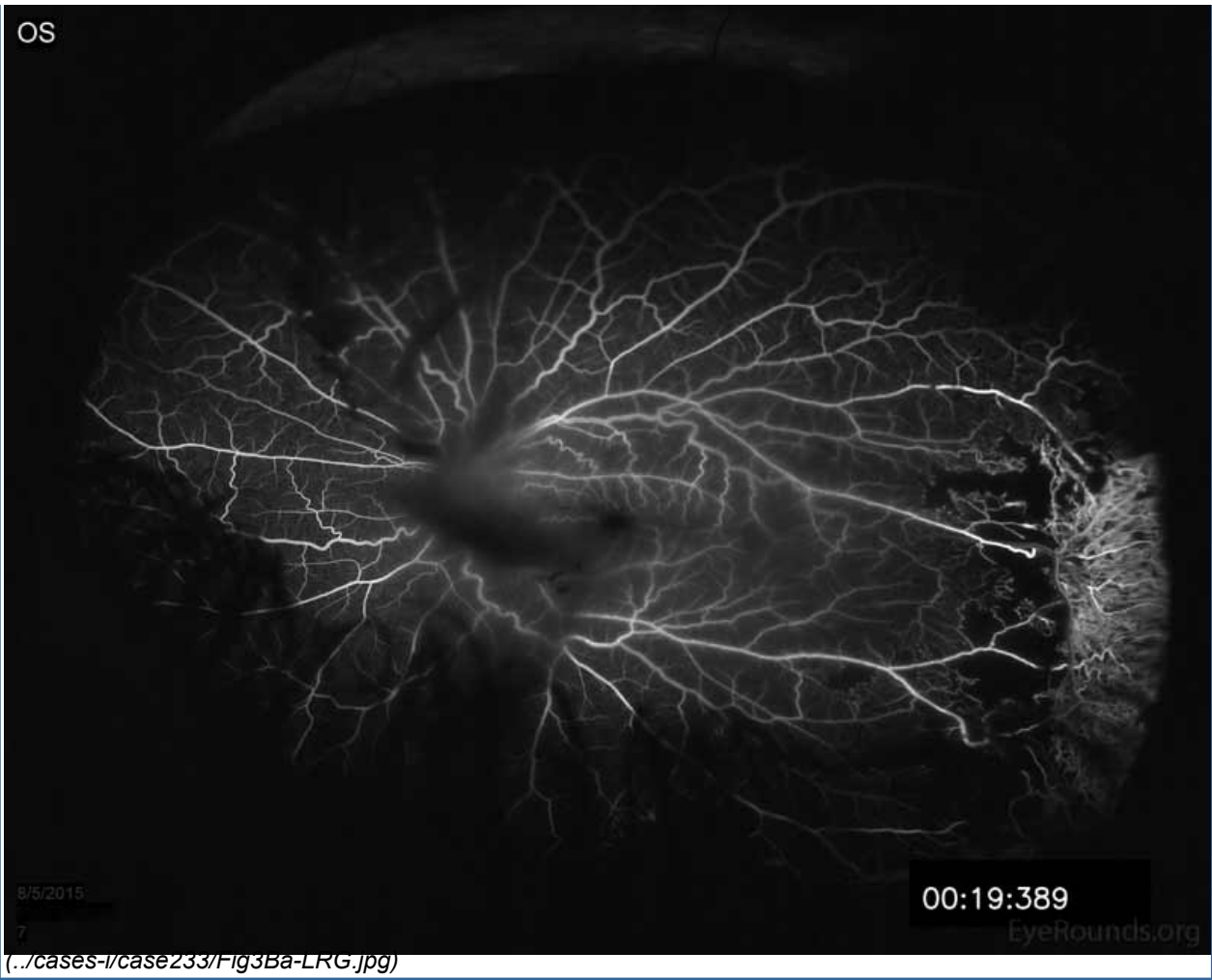


Figure 3A: Fluorescein angiogram of the right eye demonstrating NVE at 9:00 with marked late leakage inferotemporally in the area of retinal neovascularization.

OS



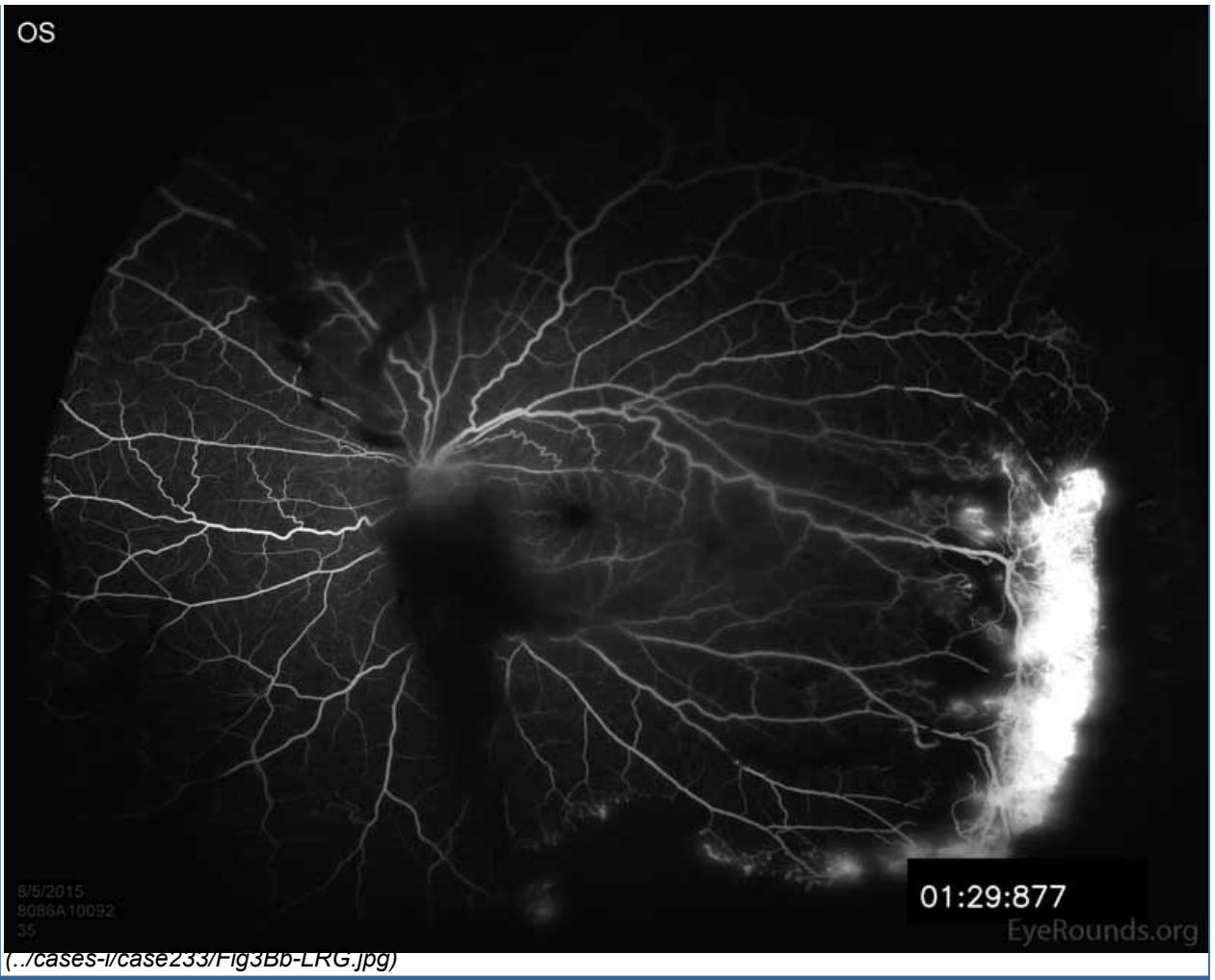
8/5/2015

00:19:389

EyeRounds.org

(../cases-1/case233/fig3Ba-LRG.jpg)

OS



8/5/2015
8086A10092
35

01:29:877

EyeRounds.org

(../cases-1/case233/fig3Bb-LRG.jpg)

OS

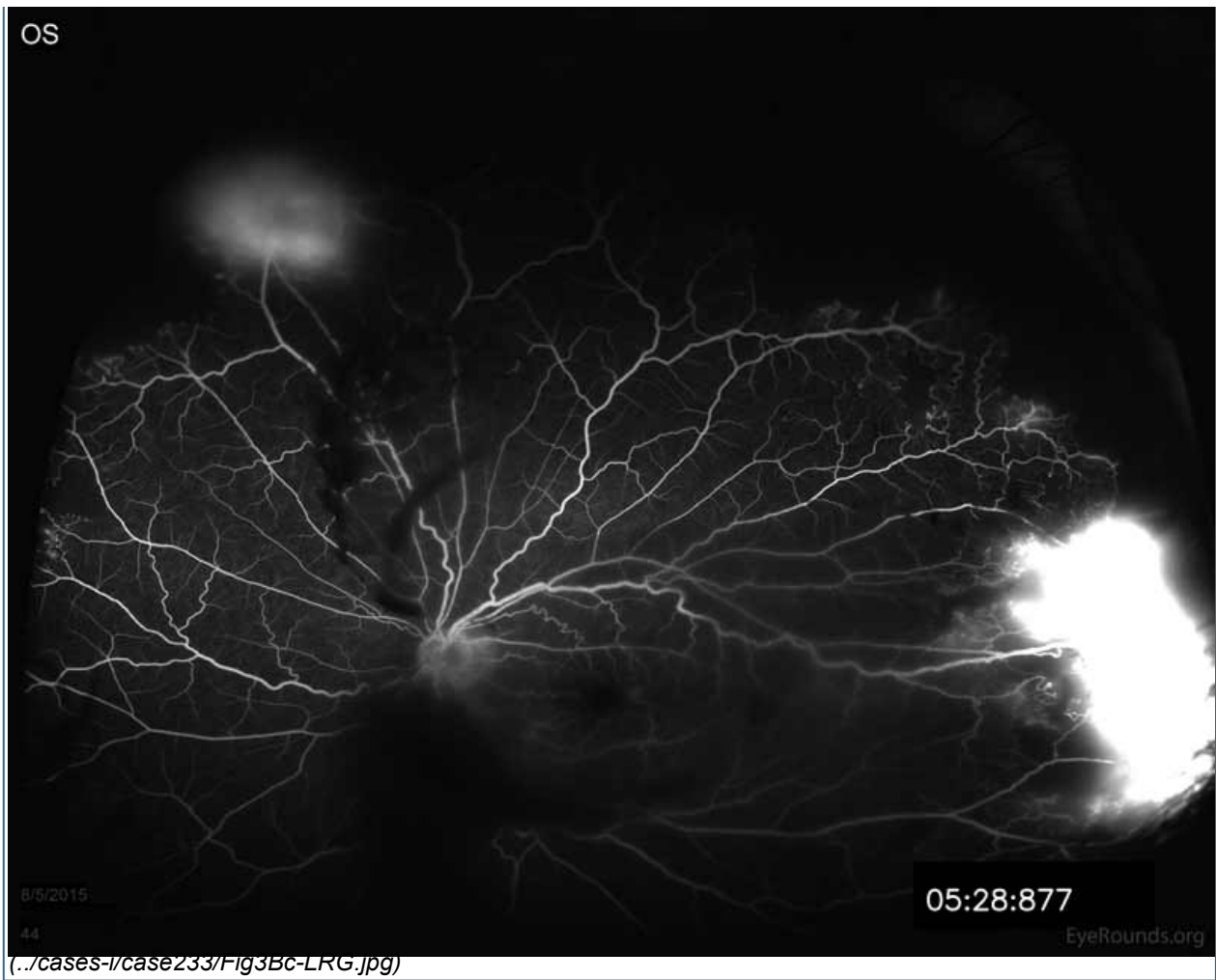


Figure 3B: Fluorescein angiogram of the left eye showing hypofluorescence over the disc and macula from overlying vitreous hemorrhage. Note the late leakage from NVE in the superior retina. There is also marked late leakage inferotemporally associated with the NVE and a tractional membrane with adjacent peripheral capillary non-perfusion is visible in the nasal and temporal periphery.

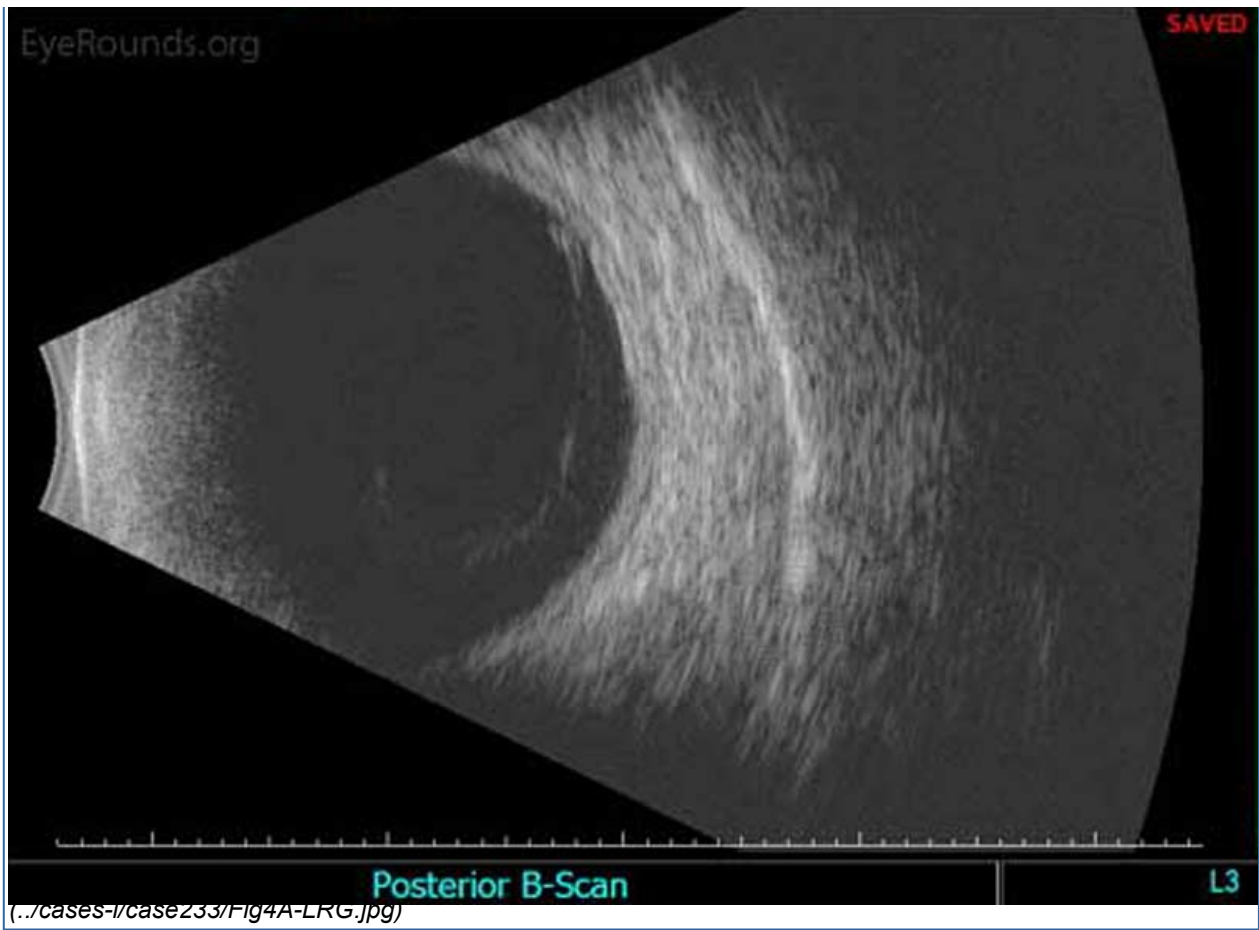

Figure 4A: Standardized ocular echography of the left eye shows a highly visible, complete posterior vitreous detachment (PVD)

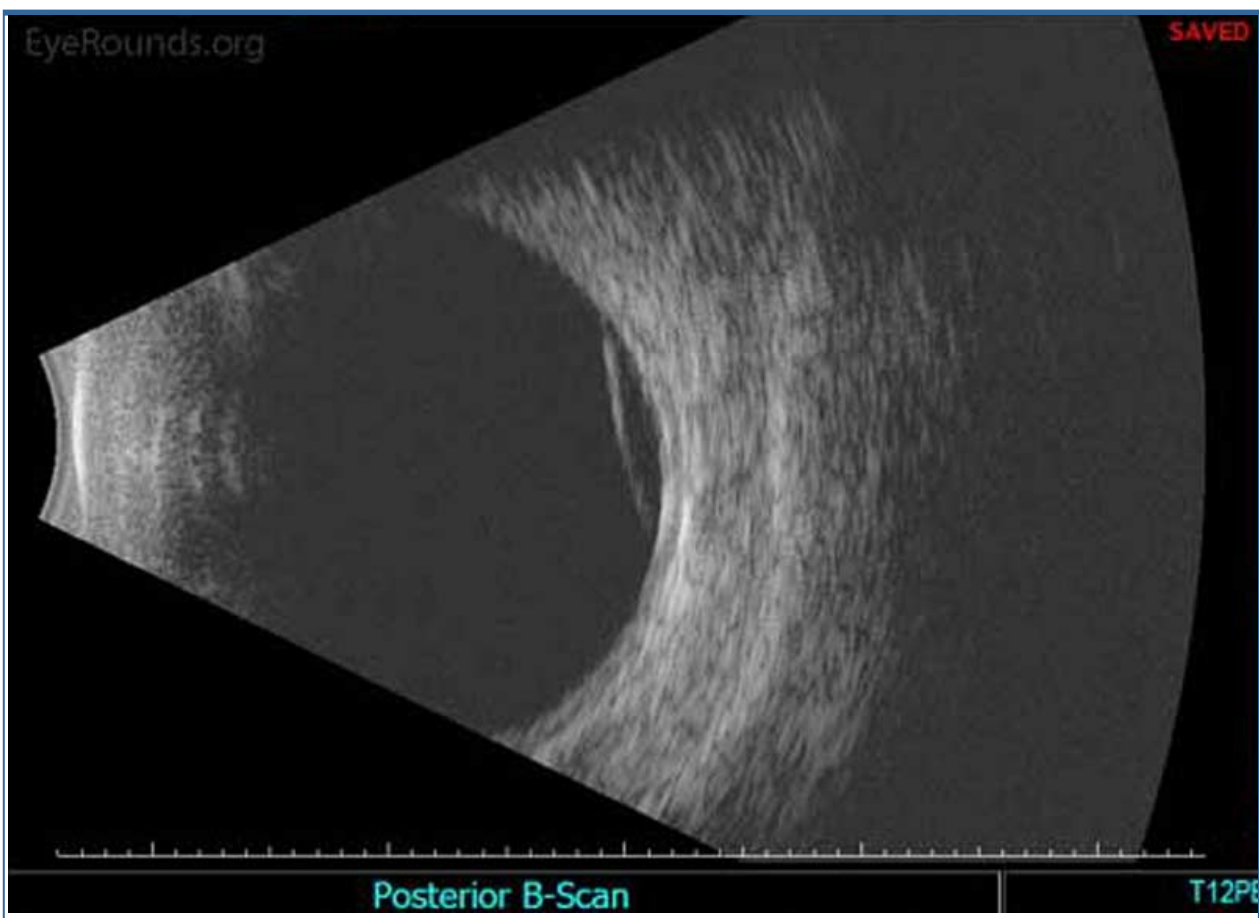

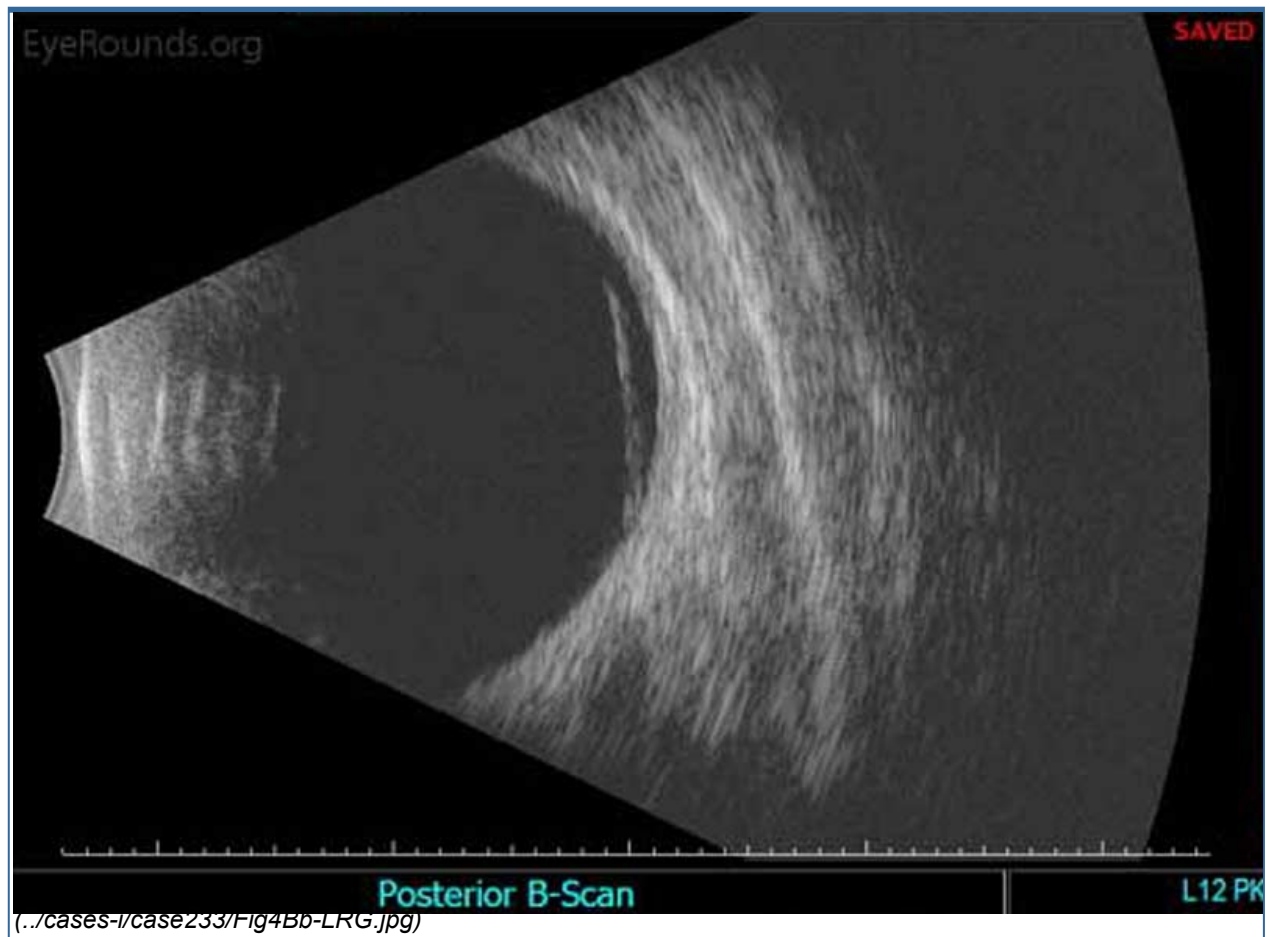


Figure 4B: A membrane, or hyper-reflective layer, is noted in the superior vitreous at 12:00 o'clock near the equator.

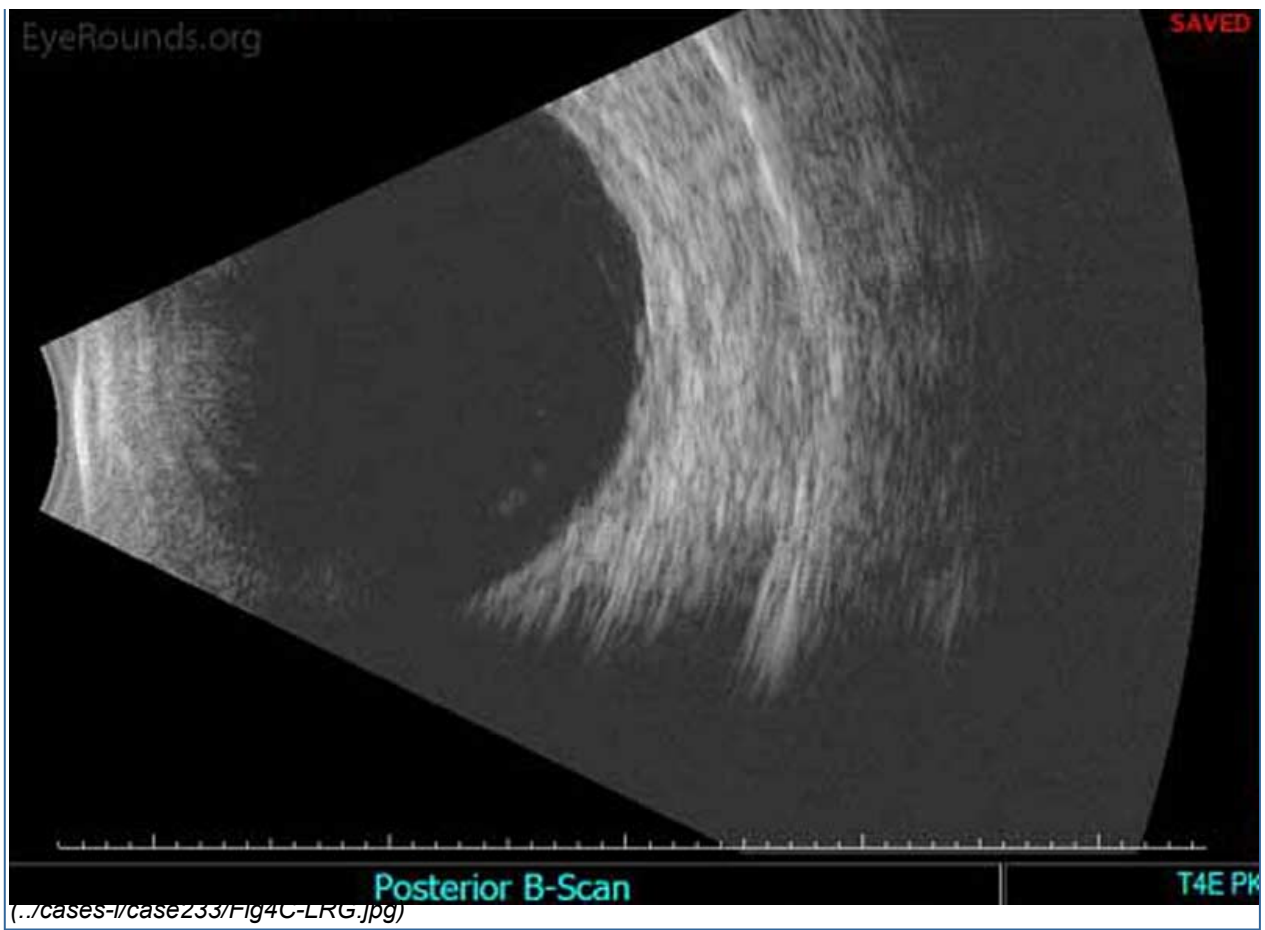

Figure 4C: The tractional membrane seen inferotemporally near the equator is associated with minimal thickening of the retina, but a retinal detachment is not present.

Differential Diagnosis

- Sickle cell retinopathy
- Proliferative diabetic retinopathy (../atlas/pages/Severe-Proliferative-Diabetic-Retinopathy/index.htm) | 2 (../atlas/pages/proliferative-diabetic-retinopathy/index.htm)
- Retinal vascular occlusion (../atlas/pages/CRVO/index.htm)
- Retinal embolization (e.g., talc) (../atlas/pages/BRAO-due-to-fibrin-embolus.html)
- Hypertensive retinopathy (../atlas/pages/hypertensive-retinopathy.html) | 2 (../atlas/pages/Accelerated-Hypertension-with-hypertensive-retinopathy.html)
- Sarcoidosis (../atlas/pages/Sarcoidosis-w-choroidal-infiltrates/index.htm)
- Eale's disease
- Infectious retinopathy (../atlas/pages/ocular-toxoplasmosis.htm) (e.g., toxoplasmosis, dengue) | 2 (../atlas/pages/ocular-toxoplasmosis-2.htm)
- Ocular ischemic syndrome
- Retinopathy of prematurity (ROP)
- Familial exudative vitreoretinopathy (FEVR (../atlas/pages/FEVR.htm))
- Hyperviscosity syndromes (e.g., chronic myelogenous leukemia) (../atlas/pages/leukemic-retinopathy.htm)

CLINICAL COURSE

The patient returned the following day, with improvement in his visual acuity in the left eye from 20/100 to 20/70 due to interval layering of the vitreous hemorrhage. Peripheral scatter photocoagulation was performed first on the left eye and later on the right eye.

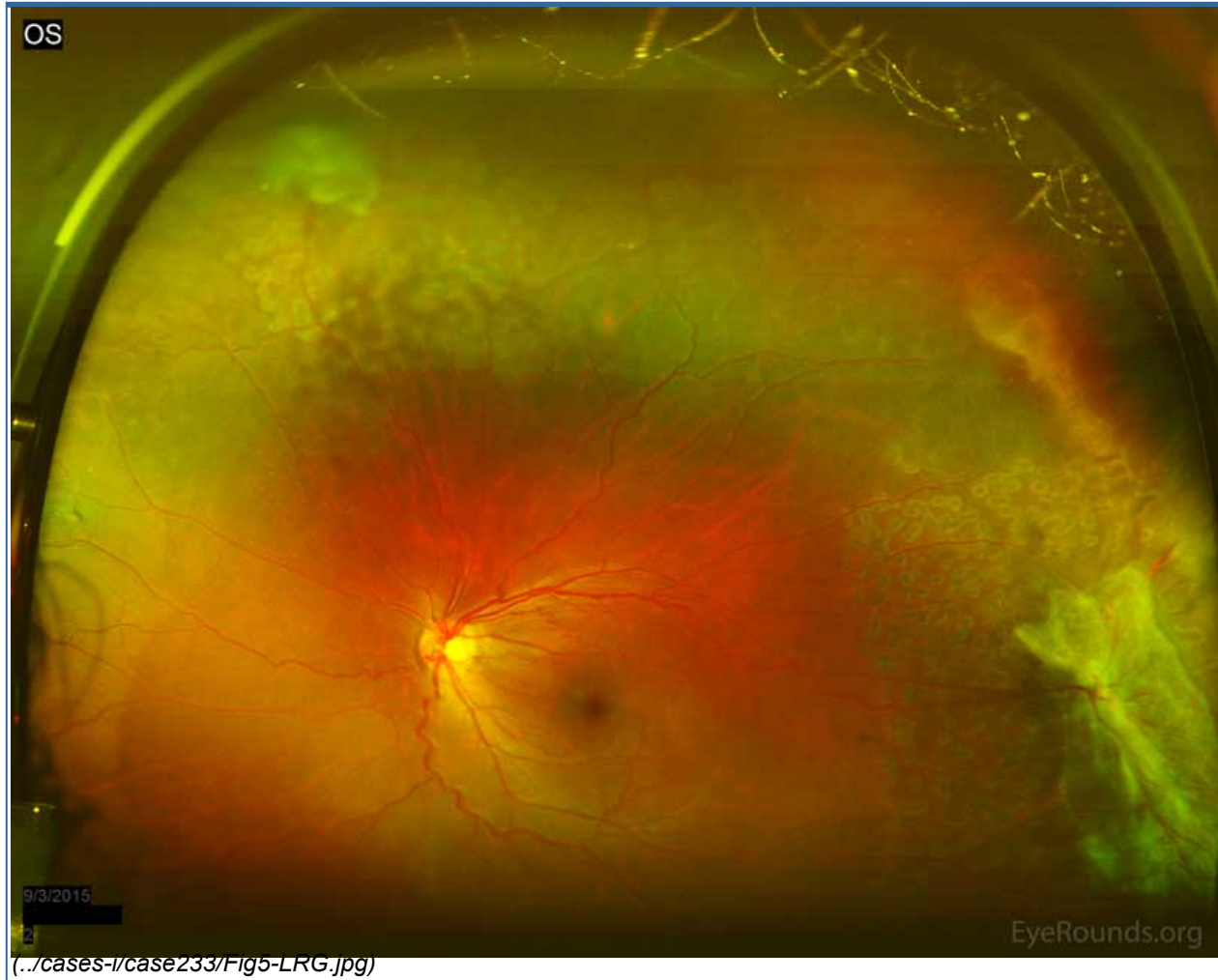

Figure 5: Acute scatter photocoagulation edema spots can be seen in the areas of retinal capillary non-perfusion. Care was taken to avoid areas of traction in the left eye.

DIAGNOSIS

The diagnosis of proliferative sickle cell retinopathy was made based on the presence of "sea fan" neovascularization with associated tractional membranes and vitreous hemorrhage in the setting of known sickle cell disease. The patient was instructed to maintain upright positioning to hasten clearance of the vitreous hemorrhage, and was educated regarding symptoms of retinal tear and detachment, with instructions to call immediately should these occur.

DISCUSSION

Etiology/Epidemiology

Sickle cell hemoglobinopathy is a disorder in which genetic mutations in the beta subunit of adult hemoglobin increase the propensity for intravascular erythrocyte deformation in a low oxygen environment [1]. This results in distal tissue ischemia and a host of related systemic and ocular complications. The disease is most prevalent

among African Americans, due to its protective effect against malaria, which is highly endemic to Africa [2]. Currently, sickle cell hemoglobinopathies as a whole have a 10% incidence in the United States. The most significant systemic form is the homozygous SS disease, whose incidence is 0.4%, in which patients experience vaso-occlusive crises and secondary end-organ damage (e.g., splenic auto-infarction, pulmonary ischemia, myocardial infarction) [3]. This form, however, uncommonly leads to proliferative retinopathy (3% incidence). The most important genotypes with regard to ophthalmic manifestations include the heterozygous SC and SThal disease, which account for 33% and 14% incidence of proliferative sickle cell retinopathy, respectively [1].

Pathophysiology

The most likely reason for the inverse relationship between the severity of systemic disease and severity of retinopathy is that the better circulatory capability of erythrocytes with hemoglobin SC and SThal allows for continued flow within neovascular lesions [5]. This is in contrast to erythrocytes with hemoglobin SS, in which occlusion of peripheral retinal vasculature is more complete, thus precluding development of proliferative lesions [6].

Signs/Symptoms

Presenting ocular symptoms include eye pain, redness, decreased visual acuity, floaters, flashes, and peripheral vision loss. The fundus of a patient with sickle cell retinopathy can have characteristic non-neovascular and/or neovascular signs. Non-neovascular signs include hemorrhage in one or more layers of the retina. Pre-retinal hemorrhages predispose to epiretinal membranes, intraretinal hemorrhages have a characteristic "salmon patch" appearance, and subretinal hemorrhages demonstrate a "black sunburst" configuration [4]. Neovascular signs include sea fan neovascularization, which can lead to vitreous hemorrhage, retinal breaks, and tractional or rhegmatogenous retinal detachments [4].

Diagnosis

Diagnosis of sickle cell retinopathy is primarily clinical and is based on the characteristic signs described above. Fluorescein angiography is helpful in the detection of retinal capillary non-perfusion, which ultimately leads to proliferative disease. Proliferative disease can be classified into five stages, as follows [4]:

1. Peripheral arteriolar occlusion and resultant non-perfusion
2. Peripheral arterio-venular anastomoses, characterized by dilated capillary channels
3. Pre-retinal sea fan neovascularization, which tends to occur at the posterior border of non-perfused areas
4. Vitreous hemorrhage
5. Tractional or rhegmatogenous retinal detachment

Management

Treatment of sickle cell retinopathy depends upon the presence or absence of proliferative disease. Non-proliferative disease should be observed by the ophthalmologist periodically (e.g., every 6 months). The patient should be regularly followed by a primary care physician and/or hematologist for surveillance of other symptoms and signs of systemic disease. Proliferative disease is managed with low-intensity scatter photocoagulation to the junction of perfused and non-perfused peripheral retina. Care must be taken in applying the laser, as retinal tears and subsequent rhegmatogenous retinal detachments are more common in this disease than in proliferative diabetic retinopathy [4]. Furthermore, ophthalmologists should avoid treating large areas (i.e., greater than 3-4 clock hours) of peripheral non-perfusion in one treatment session, as these patients are more prone to anterior segment ischemia [7]. Proliferative disease may lead to non-clearing vitreous hemorrhages, which may necessitate pars plana vitrectomy. In the unfortunate event of a

rhegmatogenous or tractional retinal detachment, the surgical approach should include the following considerations to best prevent anterior segment ischemia: local anesthesia *without* epinephrine, avoidance of encircling scleral buckles (which can promote anterior segment ischemia), maintenance of the extraocular muscles, cautious use of cryopexy, generous intravenous hydration, and the use of supplementary oxygen [7].

<h2>EPIDEMIOLOGY</h2> <ul style="list-style-type: none"> • Affects 90,000-100,000 Americans. • The incidence of sickle cell trait (SC) and Hemoglobin C trait are 8% and 2%, respectively, and uncommonly have ocular sequelae. • Sickle cell hemoglobin C (SC) and Sickle cell thalassemia (SThal), are milder systemic forms in the sickle cell disease spectrum, but have a 33% and 14% incidence of proliferative sickle cell retinopathy, respectively. 	<h2>SIGNS</h2> <p>Non-proliferative</p> <ul style="list-style-type: none"> • Salmon patch hemorrhages (intraretinal hemorrhages following peripheral retinal arteriolar occlusion) • Refractile (iridescent) deposits/spots (old, resorbed hemorrhages with hemosiderin deposition beneath the internal limiting membrane) • Black sunburst lesions (focal areas of retinal pigment epithelial hypertrophy, hyperplasia, and pigment translocation into the retina) <p>Proliferative</p> <ul style="list-style-type: none"> • Arterio-venular anastomoses (dilated capillary channels) • Pre-retinal sea fan neovascularization • Vitreous hemorrhage • Tractional/rhegmatogenous retinal detachment
<h2>SYMPTOMS</h2> <ul style="list-style-type: none"> • Eye pain • Eye redness • Decreased vision • Floaters • Flashes • Loss of peripheral vision 	<h2>TREATMENT/MANAGEMENT</h2> <ul style="list-style-type: none"> • Low-intensity scatter laser photocoagulation to areas of capillary non-perfusion • Pars plana vitrectomy for non-clearing vitreous hemorrhage and/or retinal detachment

References

1. Friberg TR, Young CM, and Milner PF. Incidence of ocular abnormalities in patients with sickle hemoglobinopathies. *Ann Ophthalmol* 1986;18(4): 150–153
2. "Protective Effect of Sickle Cell Trait Against Malaria-Associated Mortality And Morbidity." *Malaria*. Centers for Disease Control and Prevention, 08 Feb. 2010. Web. 11 Feb. 2016. Available from http://www.cdc.gov/malaria/about/biology/sickle_cell.html (http://www.cdc.gov/malaria/about/biology/sickle_cell.html)
3. "Data & Statistics." *Sickle Cell Disease (SCD)*. Centers for Disease Control and Prevention, 08 July 2015. Last Accessed 11 Feb. 2016. Available from <http://www.cdc.gov/ncbddd/sicklecell/data.html> (<http://www.cdc.gov/ncbddd/sicklecell/data.html>)

4. Schubert HD, Atebara NH, Kaiser RK, Martidis AA, McCannel CA, Zacks ZN, and Dhindsa HS. Retina. Section 12, Basic and Clinical Science Course. San Francisco: American Academy of Ophthalmology; 2014-2015; Chapter 6, pp. 115-121.
5. Barbosa de Melo, M. An eye on sickle cell retinopathy. Revista Brasileira de Hematologia e Hemoterapia 2014;36(5): 319–321.
6. Nagel RL, Fabry ME, Steinberg MH. The paradox of hemoglobin SC disease. Blood 2003;17(3): 167–178
7. Leen JS, Ratnakaram R, Del Priore LV, et al. Anterior segment ischemia after vitrectomy in sickle cell disease. Retina 2002;22: 216–219.

Suggested Citation Format:

Parekh PK, Miller MA, Russell SR. Sickle Cell Retinopathy. EyeRounds.org. March 29, 2016. Available from <http://EyeRounds.org/cases/233-Sickle-Cell-Retinopathy.htm>

last updated: 04/06/2016

Share this page:

University of Iowa Carver College of Medicine
Department of Ophthalmology & Visual Sciences
200 Hawkins Dr.
Iowa City, IA 52242

Web Privacy Policy (<http://www.uiowa.edu/homepage/online-privacy-information>) | Nondiscrimination Statement (<http://opsmanual.uiowa.edu/community-policies/nondiscrimination-statement>)

 **THE UNIVERSITY OF IOWA**
(<http://www.uiowa.edu>)

Directory (<https://www.dna.its.uiowa.edu/Whitepages/>) | **A-Z Search** (<http://www.uiowa.edu/a-z>) | **About Iowa** (<http://www.uiowa.edu/homepage/about-university>) | **Contact Us** (<http://www.uiowa.edu/homepage/about-university>) | **Calendars** (<http://www.uiowa.edu/homepage/calendars>) | **Privacy Information** (<http://www.uiowa.edu/homepage/online-privacy-information>)

copyright ©2016 The University of Iowa.