

## Thygeson's superficial punctate keratitis

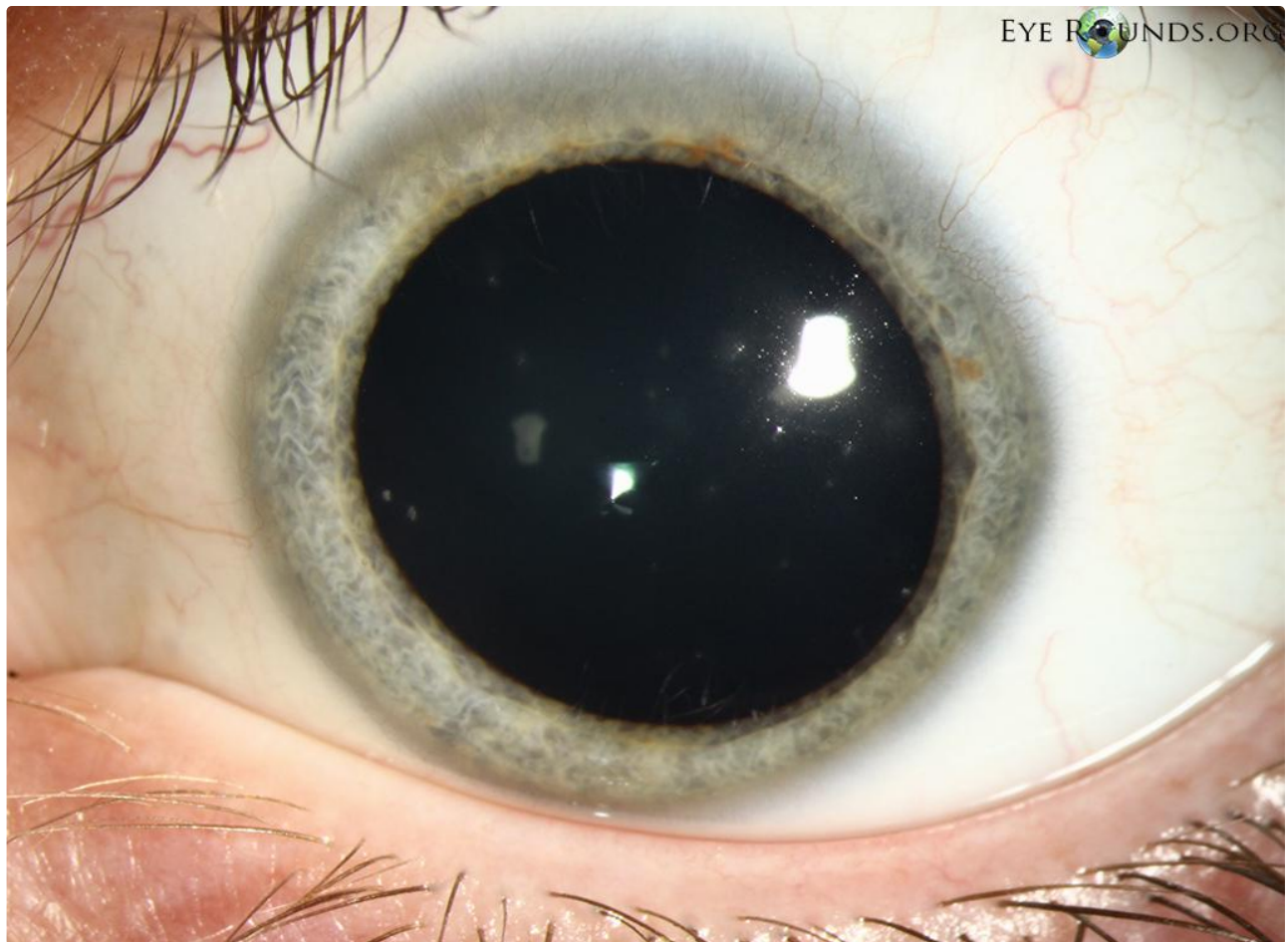
**Category(ies):** Cornea

**Contributor:** [Lucas Lenci, MD](#); [Blake Perry, MD](#)

**Photographer:** Brice Critser, CRA

In 1950, Dr. Phillips Thygeson reported a case series of 26 patients. These patients classically have a history of cyclical exacerbations and remissions with symptoms of foreign body sensation, photophobia, burning, tearing and occasionally blurring of vision. Symptoms are commonly bilateral but asymmetric. On exam, there are multiple slightly elevated corneal lesions which are round to oval conglomerates of gray, granular "crumblike" subepithelial opacities. These lesions normally negatively stain, but during exacerbations one can see staining with fluorescein dye. There is minimal conjunctival reaction. On average there are 15-20 lesions, with the greatest density being in the central cornea. These patients can present a difficult treatment conundrum. However, typical treatment consists of topical corticosteroids primarily with cyclosporine and bandaged contact lenses as secondary options. Visual prognosis is excellent.

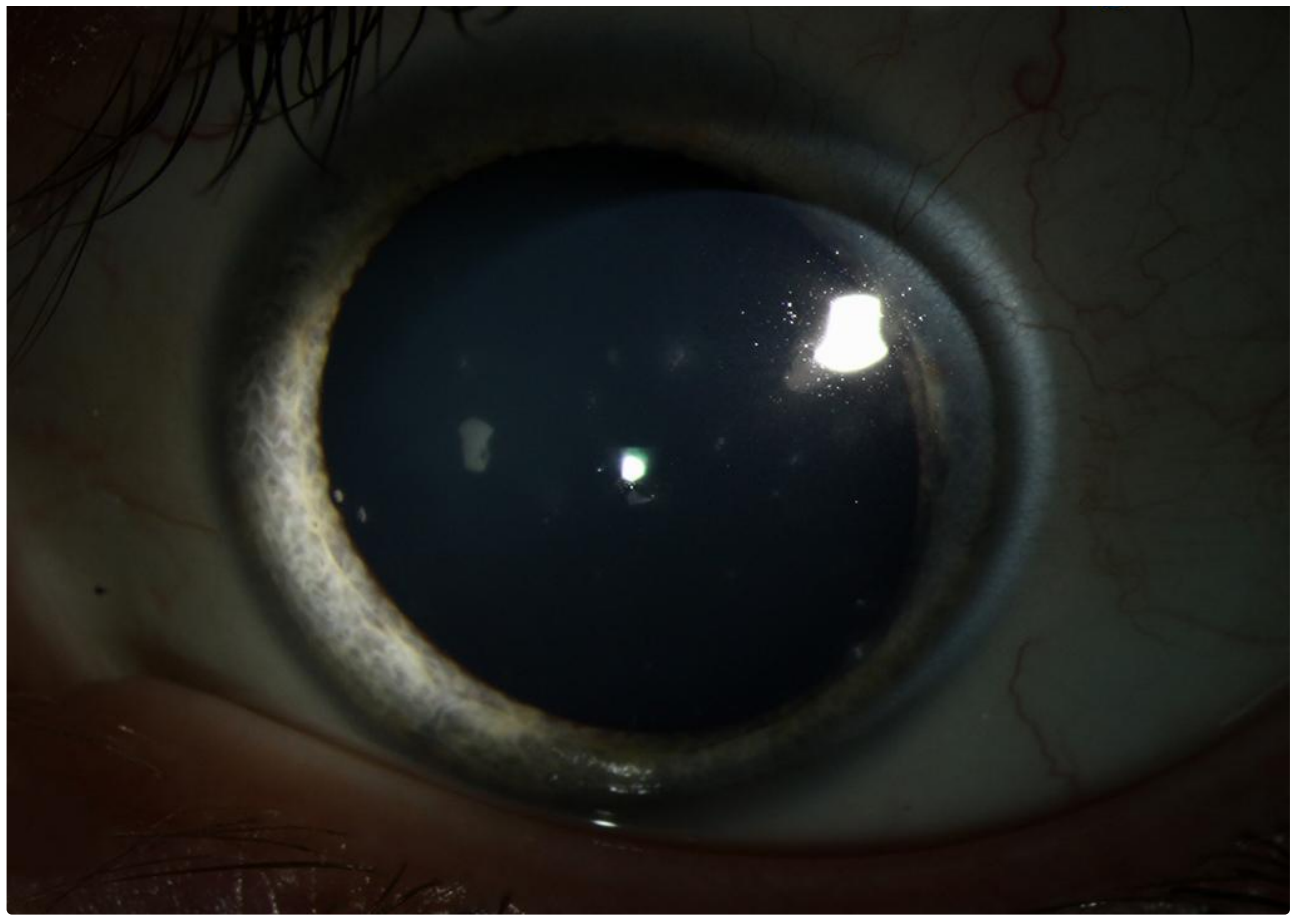
As an interesting side note, Dr. Thygeson was a faculty member of the University of Iowa Department of Ophthalmology in the 1930's.



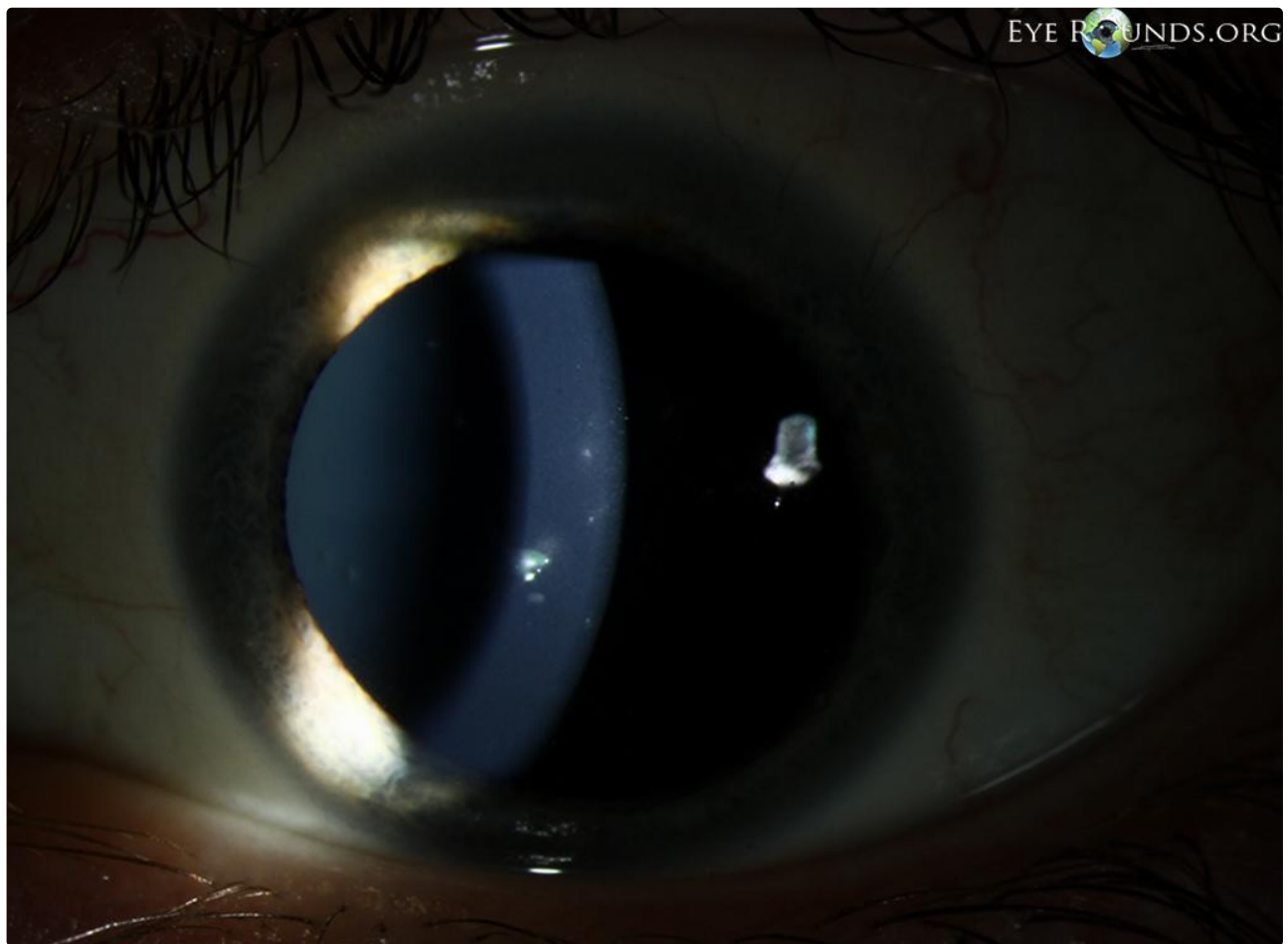
EYE ROUNDS.ORG

[Enlarge](#)

[Download](#)

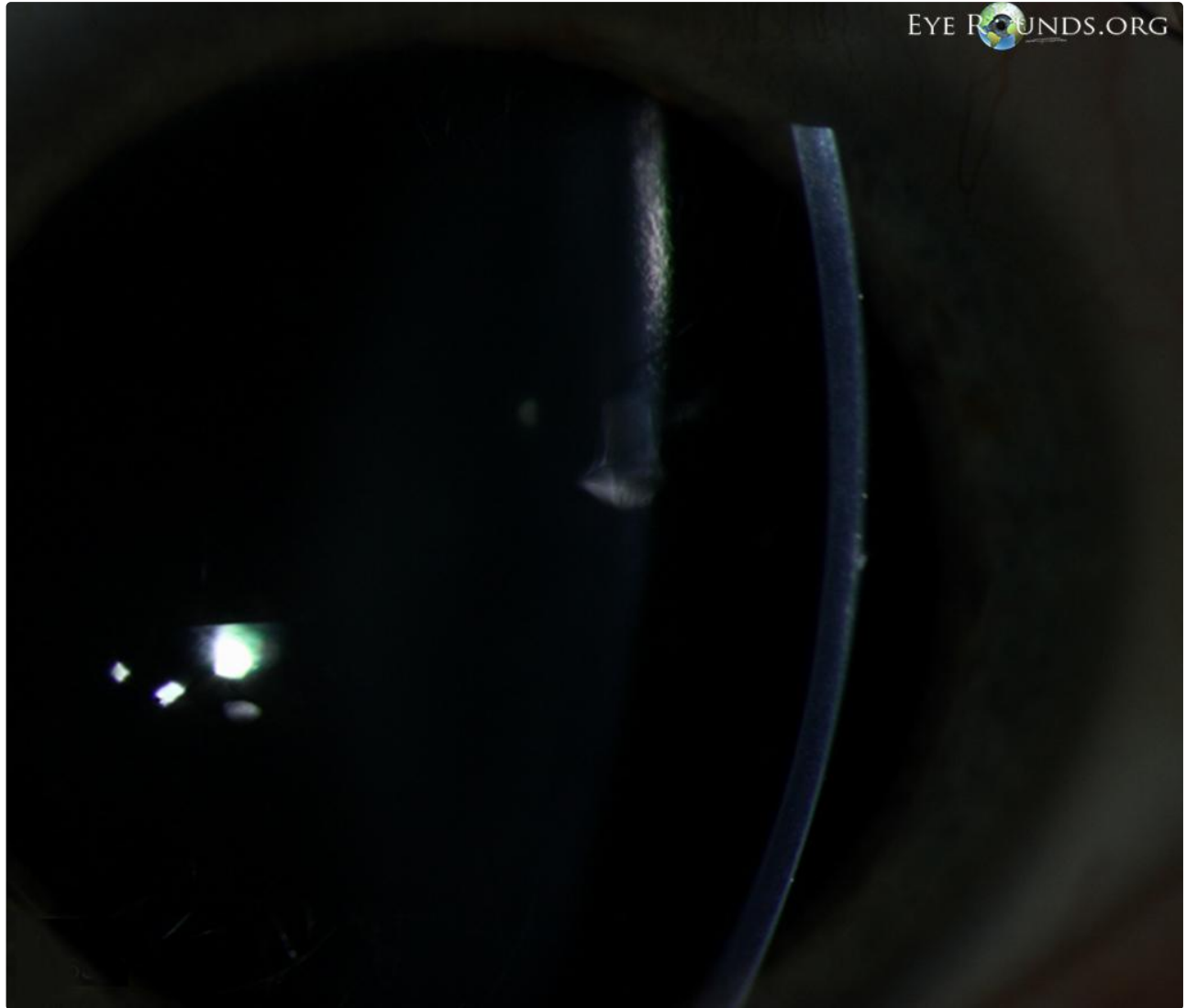

[Enlarge](#) [Download](#)



Enlarge

Download



Enlarge

Download

#### Reference:

- Nagra PK, Rapuano CJ, Cohen EJ, Laibson PR. Thygeson's superficial punctate keratitis: ten years' experience. *Ophthalmology*. 2004; 111(1):34-7
- Thygeson P. Superficial punctate keratitis. *J Am Med Assoc*. 1950; 144(18):1544-9.

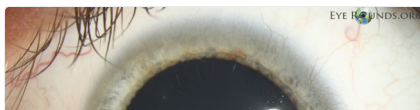#### Image Permissions:

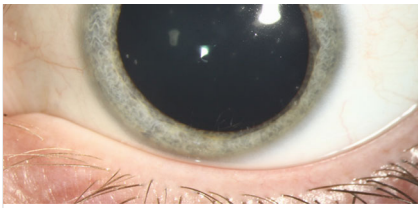


Ophthalmic Atlas Images by [EyeRounds.org](http://EyeRounds.org), [The University of Iowa](http://The University of Iowa) are licensed under a [Creative Commons Attribution-NonCommercial-NoDerivs 3.0 Unported License](http://Creative Commons Attribution-NonCommercial-NoDerivs 3.0 Unported License).



#### Related Articles





[Related Case: Thygeson's Superficial Punctate Keratitis](#)

---

### Address

University of Iowa  
Roy J. and Lucille A. Carver College  
of Medicine  
Department of Ophthalmology and  
Visual Sciences  
200 Hawkins Drive  
Iowa City, IA 52242

[Support Us](#)

### Legal

Copyright © 2019 The University of  
Iowa. All Rights Reserved  
[Report an issue with this page](#)  
[Web Privacy Policy](#) |  
[Nondiscrimination Statement](#)

### Related Links

[Cataract Surgery for Greenhorns](#)  
[EyeTransillumination](#)  
[Gonioscopy.org](#)  
[Iowa Glaucoma Curriculum](#)  
[Iowa Wet Lab](#)  
[Patient Information](#)  
[Stone Rounds](#)  
[The Best Hits Bookshelf](#)

### EyeRounds Social Media

Follow



Receive notification of new cases,  
[sign up here](#)  
[Contact Us](#)  
[Submit a Suggestion](#)