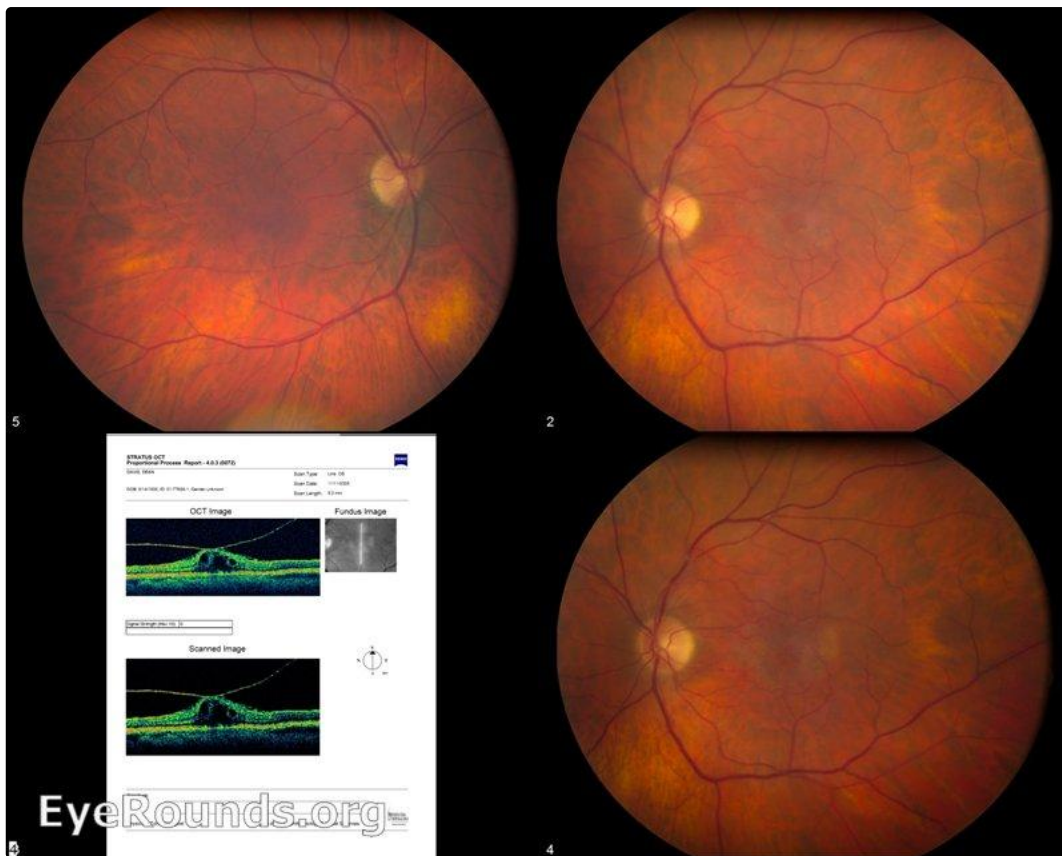


Vitreoretinal Traction (VRT) and Cystoid Macular Edema (CME)

Category(ies): Cornea, Retina

Contributor: Thomas A. Weingeist, PhD, MD



Vitreoretinal traction with associated macular edema is evident in the fundus of this patient's left eye. The posterior hyaloid traction edema are well seen in the correlating OCT image.

[Enlarge](#) [Download](#)

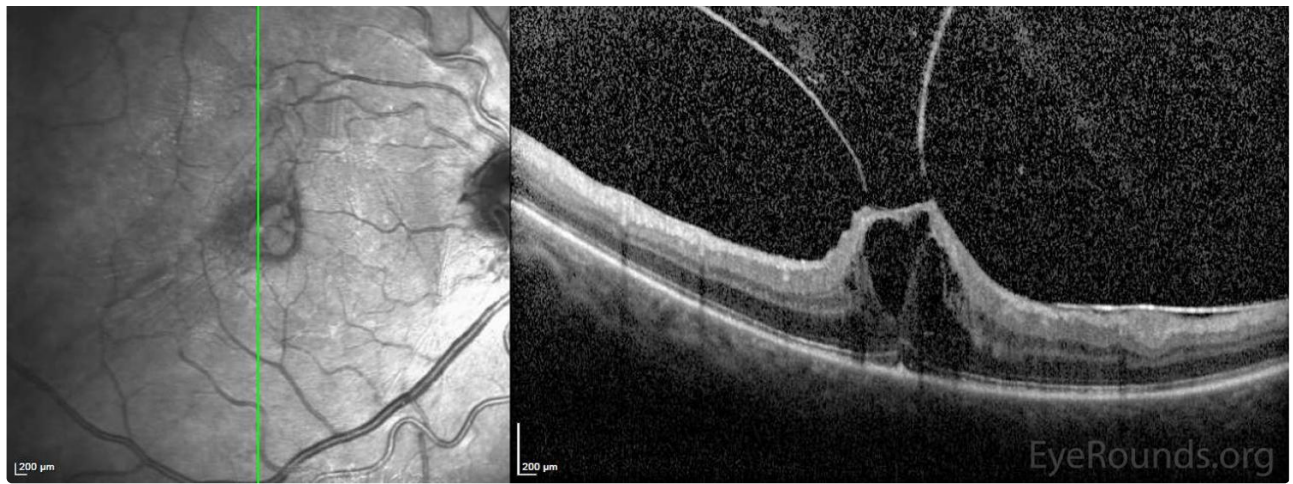
Contributor: [Ben Janson, MD](#)

Photographer: [Jody Troyer](#)

This patient presented with blurry vision and visual distortion in one eye, and vitreomacular traction was discovered by optical coherence tomography (OCT) imaging. Vitreomacular traction occurs as the result of vitreomacular adhesions in a detaching posterior vitreous.

Hyaloid traction causes symptoms of decreased visual acuity and metamorphopsia and may lead to the development of a foveal pseudocyst. Treatment includes observation, intravitreal injection (fluid, air/gas, or ocriplasmin), or pars plana vitrectomy with membrane peel and gas bubble.





[Enlarge](#) [Download](#)

References:

1. Vitreomacular traction diseases. In: Basic and clinical science course (BCSC) Section 12: Retina and vitreous. Chapter 16 Diseases of the vitreous and vitreoretinal interface. San Francisco, CA: American Academy of Ophthalmology. 2016-2017 p293-294
2. Idiopathic macular holes. In: Basic and clinical science course (BCSC) Section 12: Retina and vitreous. Chapter 16 Diseases of the vitreous and vitreoretinal interface. San Francisco, CA: American Academy of Ophthalmology. 2016-2017 p294-297

Image Permissions:



Ophthalmic Atlas Images by [EyeRounds.org](#), [The University of Iowa](#) are licensed under a [Creative Commons Attribution-NonCommercial-NoDerivs 3.0 Unported License](#).

Address

University of Iowa
Roy J. and Lucille A. Carver College
of Medicine
Department of Ophthalmology and
Visual Sciences
200 Hawkins Drive
Iowa City, IA 52242

[Support Us](#)

Legal

Copyright © 2019 The University of
Iowa. All Rights Reserved
[Report an issue with this page](#)
[Web Privacy Policy](#) |
[Nondiscrimination Statement](#)

Related Links

[Cataract Surgery for Greenhorns](#)
[EyeTransillumination](#)
[Gonioscopy.org](#)
[Iowa Glaucoma Curriculum](#)
[Iowa Wet Lab](#)
[Patient Information](#)
[Stone Rounds](#)
[The Best Hits Bookshelf](#)

EyeRounds Social Media

Follow



Receive notification of new cases,
[sign up here](#)
[Contact Us](#)
[Submit a Suggestion](#)