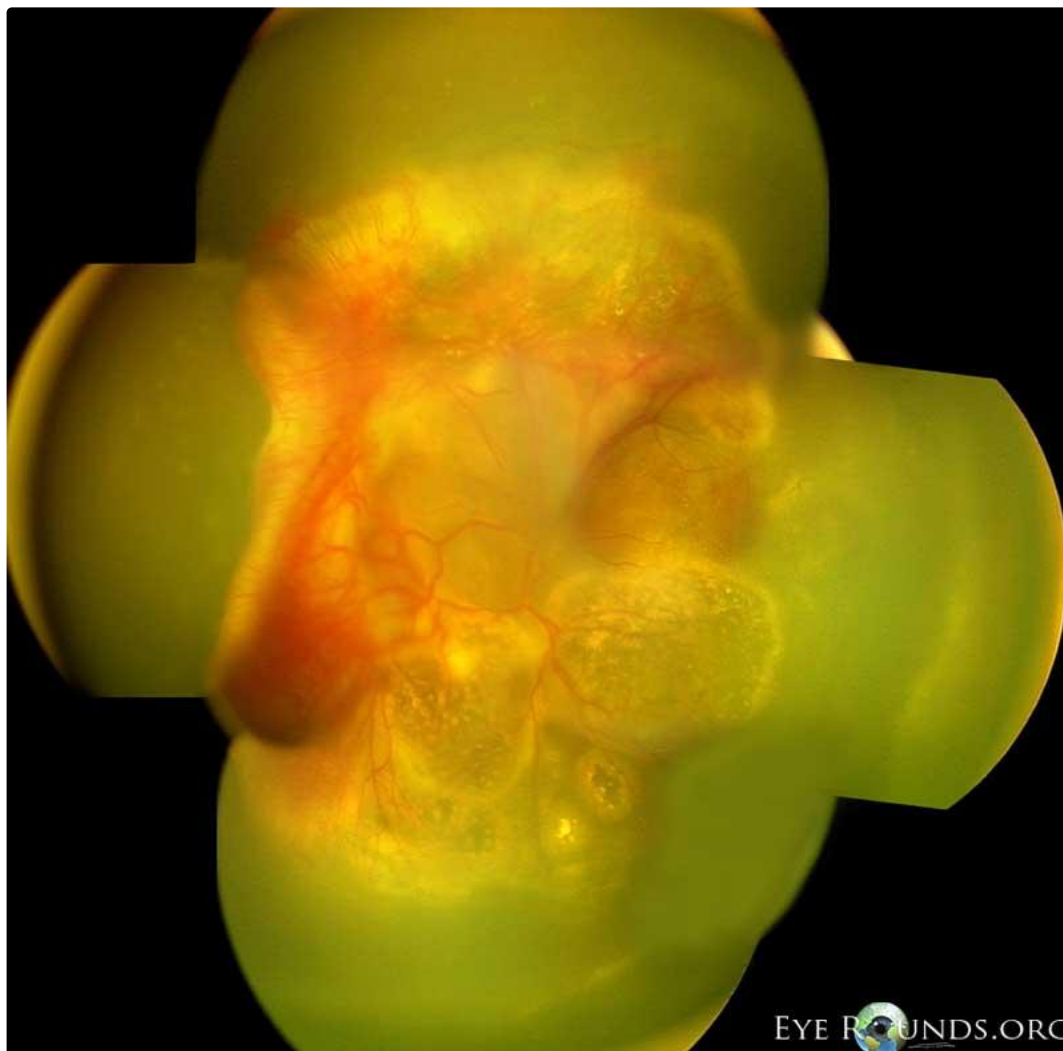


## Familial Exudative Vitreoretinopathy (FEVR)(1)

**Category(ies):** Genetics, Inherited Eye Disease, Pediatrics, Retina, Vitreous

**Contributor:** [Lorna Grant, MD](#), [Mark K. Walsh, MD, PhD](#) and [Matthew Feng, MD](#),

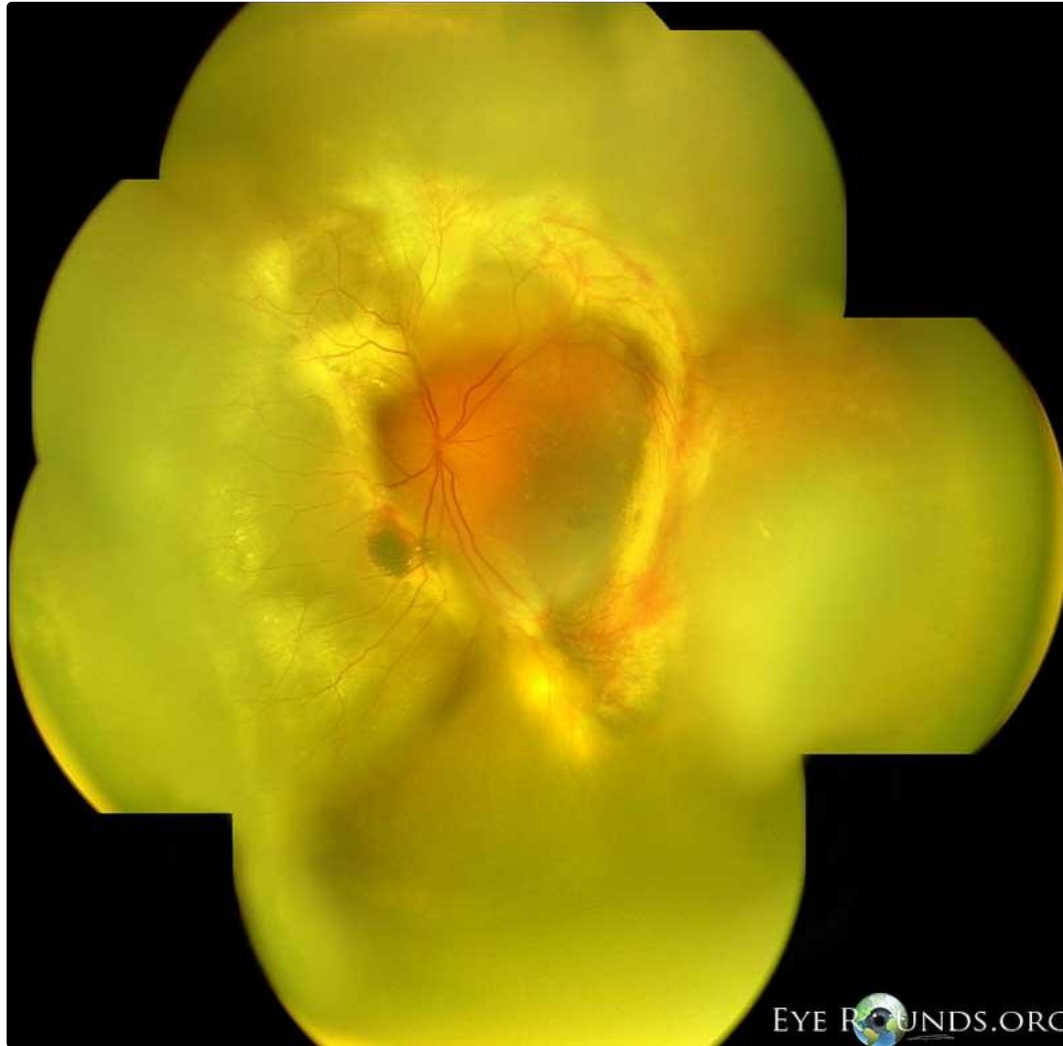These fundus photos are from a 4 week-old baby boy who has familial exudative vitreoretinopathy (FEVR) manifesting bilateral retinal detachments with tractional and exudative components, as well as preretinal neovascularization and subretinal hemorrhage and lipid exudate.



Right Eye

 Enlarge

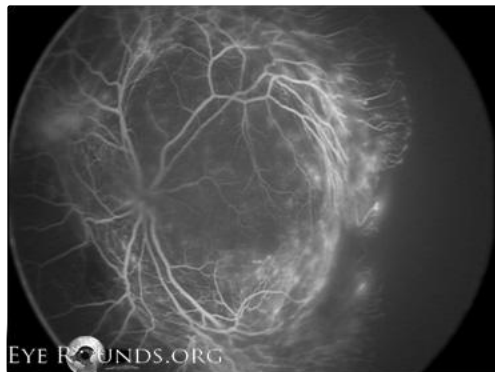
 Download



Left Eye

[Enlarge](#)

[Download](#)



Fluorescein Angiogram

[Enlarge](#)

[Download](#)

[OMIM: 133780](#)

Image Permissions

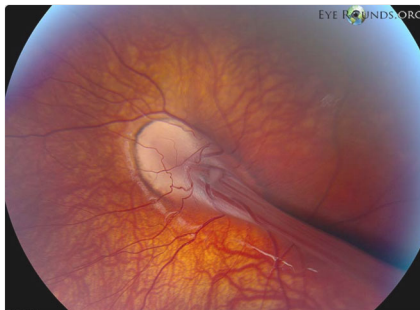
## Image Permissions:



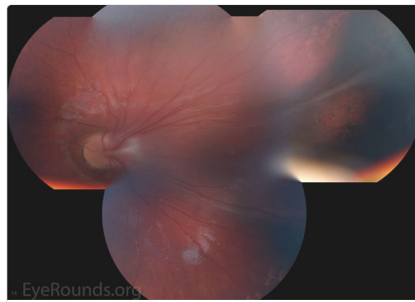
Ophthalmic Atlas Images by [EyeRounds.org](https://www.eyerounds.org), [The University of Iowa](https://www.theuniversityofiowa.edu) are licensed under a [Creative Commons Attribution-NonCommercial-NoDerivs 3.0 Unported License](https://creativecommons.org/licenses/by-nc-nd/3.0/).



## Related Articles



[Related Atlas Entry: Familial exudative vitreoretinopathy \(FEVR\)](#)



[Related Atlas Entry: Familial exudative vitreoretinopathy \(FEVR\) \(2\)](#)

## Address

University of Iowa  
Roy J. and Lucille A. Carver College  
of Medicine  
Department of Ophthalmology and  
Visual Sciences  
200 Hawkins Drive  
Iowa City, IA 52242

[Support Us](#)

## Legal

Copyright © 2019 The University of  
Iowa. All Rights Reserved  
[Report an issue with this page](#)  
[Web Privacy Policy](#) |  
[Nondiscrimination Statement](#)

## Related Links

[Cataract Surgery for Greenhorns](#)  
[EyeTransillumination](#)  
[Gonioscopy.org](#)  
[Iowa Glaucoma Curriculum](#)  
[Iowa Wet Lab](#)  
[Patient Information](#)  
[Stone Rounds](#)  
[The Best Hits Bookshelf](#)

## EyeRounds Social Media

Follow



Receive notification of new cases,  
[sign up here](#)  
[Contact Us](#)  
[Submit a Suggestion](#)