

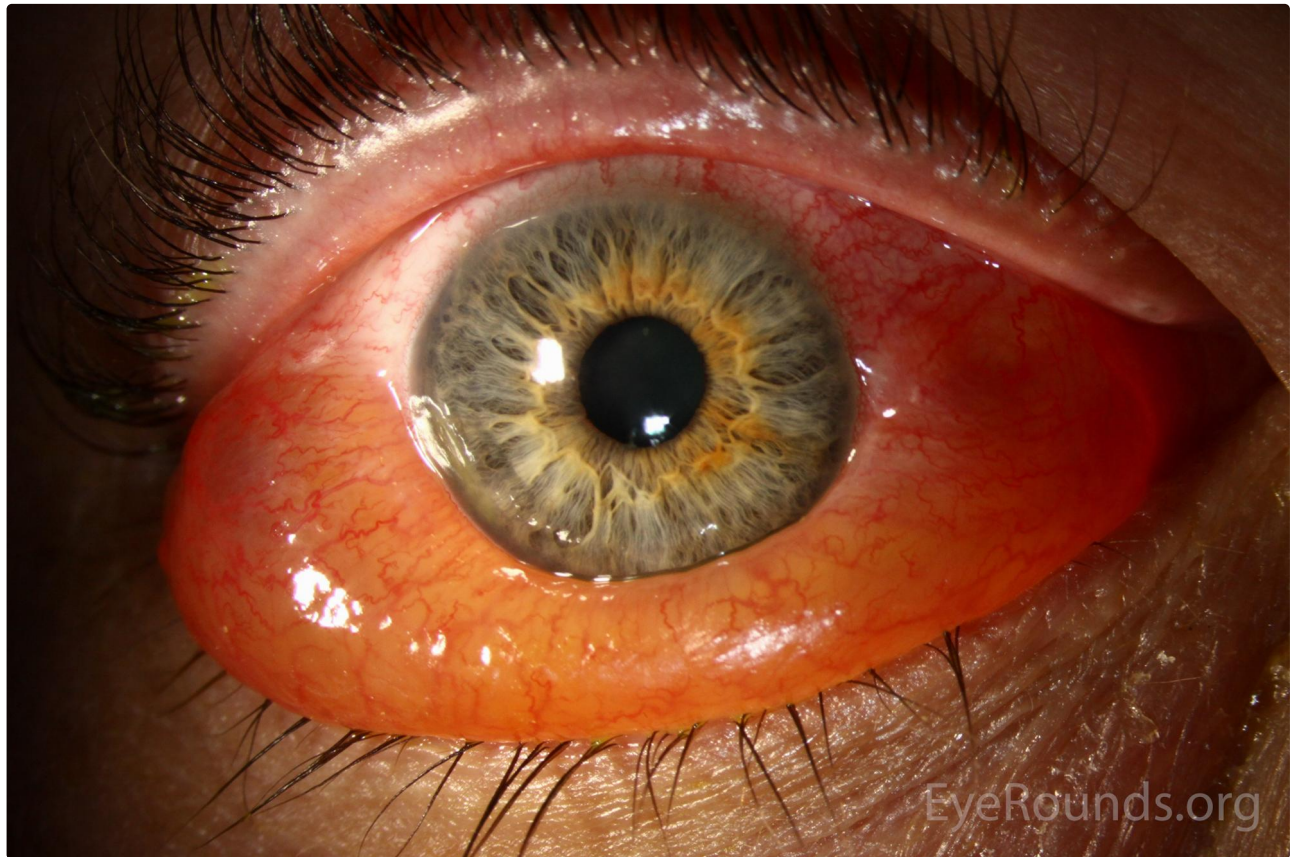## Bilateral chemosis in thyroid eye diseases

Category(ies): Oculoplastics

Contributor: [Brittni A. Scruggs, MD, PhD](#); [Audrey C. Ko, MD](#); [Alison K. Bozung, OD, FAAO](#)

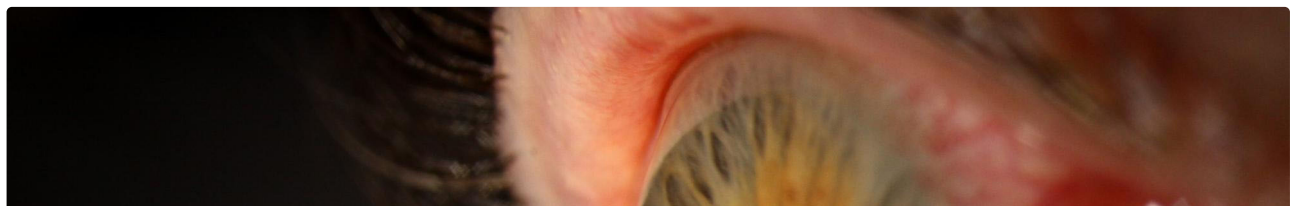
Photographer: Jody M. Troyer, CRA

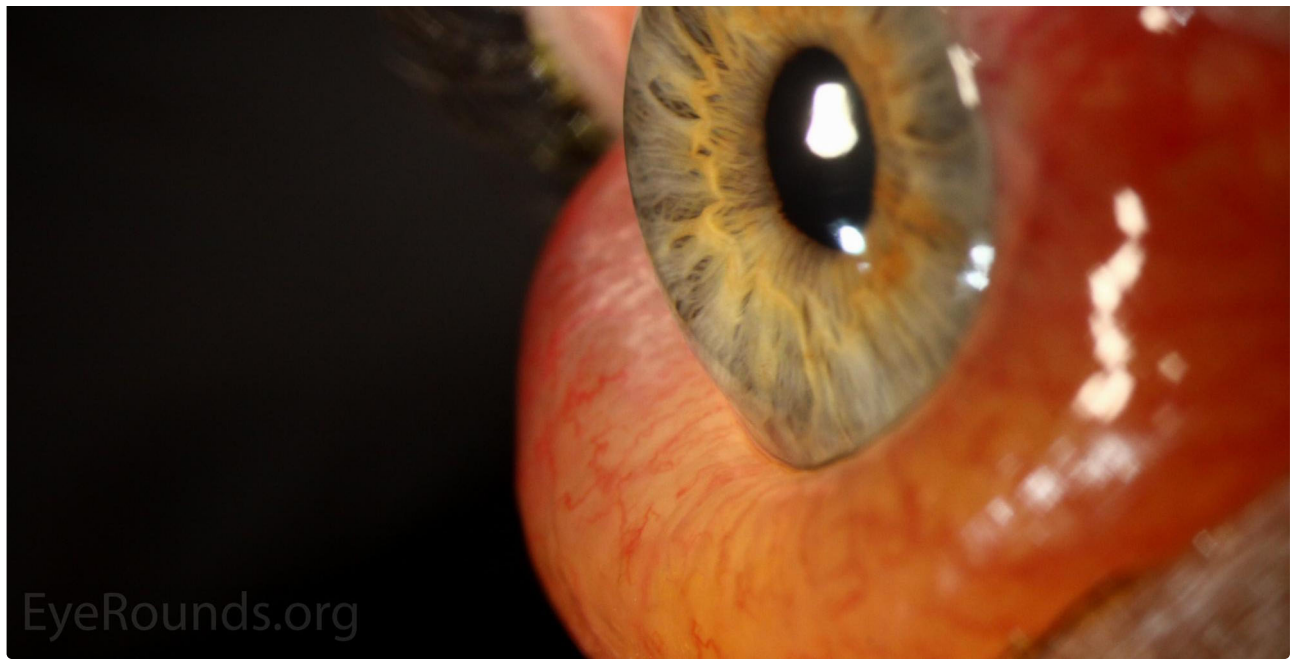This 51-year-old man presented with acute onset of binocular diplopia, injected eyes, and periocular swelling that was initially diagnosed as episcleritis but worsened despite lubrication and topical steroids. Examination was remarkable for a restrictive strabismus, right upper and lower eyelid retraction, and right greater than left inferior chemosis. Additional imaging and serology testing confirmed the diagnosis of thyroid eye disease (TED). In the early presentation of thyroid eye disease, patients may experience chemosis, conjunctival injection, and eyelid swelling secondary to orbital congestion. For more information on TED, see the [EyeRounds TED tutorial](#).



Right eye : Minimal edema of right upper and lower eyelids, 4+ bullous chemosis from 0200 to 0930 with 2+ diffuse injection, mild inferotemporal thinning (dellen) at the limbus

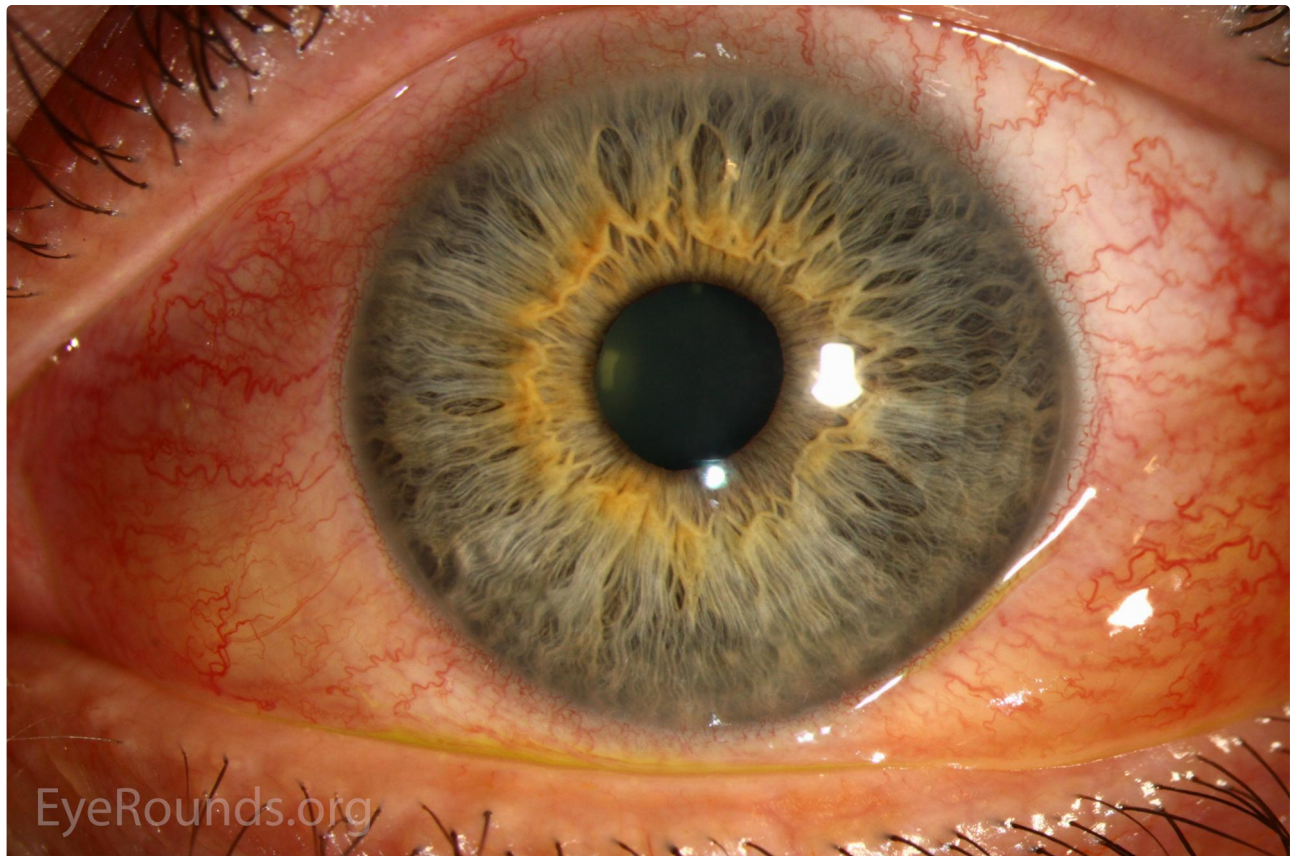[Enlarge](#) [Download](#)





Right eye : Minimal edema of right upper and lower eyelids, 4+ bullous chemosis from 0200 to 0930 with 2+ diffuse injection, mild inferotemporal thinning (dellen) at the limbus

[Enlarge](#) [Download](#)



Left eye: Minimal edema of left upper and lower eyelids, 2+ diffuse chemosis with 1+ diffuse injection.

[Enlarge](#) [Download](#)

Image Permissions:

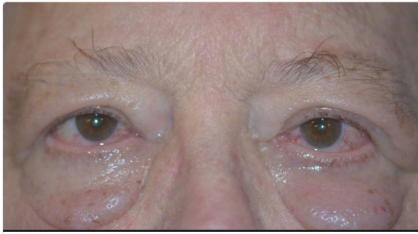



Ophthalmic Atlas Images by [EyeRounds.org](https://www.eyerounds.org/), [The University of Iowa](https://www.theuniversityofiowa.edu/) are licensed under a [Creative Commons Attribution-NonCommercial-NoDerivs 3.0 Unported License](https://creativecommons.org/licenses/by-nc-nd/3.0/).



### Related Articles



[Related Tutorial: Thyroid Eye Disease \(TED\)](#)

### Address

University of Iowa  
Roy J. and Lucille A. Carver College  
of Medicine  
Department of Ophthalmology and  
Visual Sciences  
200 Hawkins Drive  
Iowa City, IA 52242

[Support Us](#)

### Legal

Copyright © 2019 The University of  
Iowa. All Rights Reserved  
[Report an issue with this page](#)  
[Web Privacy Policy](#) |  
[Nondiscrimination Statement](#)

### Related Links

[Cataract Surgery for Greenhorns](#)  
[EyeTransillumination](#)  
[Gonioscopy.org](#)  
[Iowa Glaucoma Curriculum](#)  
[Iowa Wet Lab](#)  
[Patient Information](#)  
[Stone Rounds](#)  
[The Best Hits Bookshelf](#)

### EyeRounds Social Media

Follow



Receive notification of new cases,  
[sign up here](#)  
[Contact Us](#)  
[Submit a Suggestion](#)