

# EyeRounds.org

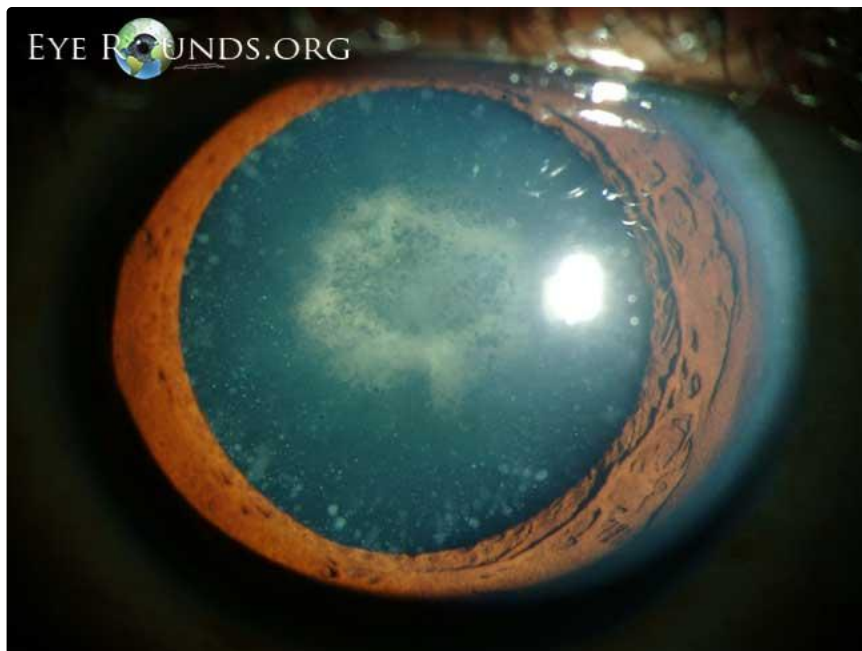
## Cerulean cataract

Category(ies): Cataract

Contributor: [Justin Risma, MD](#)

Photographer: Brice Critser, CRA

Cerulean cataracts are composed of small bluish dot-like opacities in the peripheral lens cortex. They usually do not cause visual symptoms. This patient also has a dense central posterior subcapsular cataract which was visually significant.



[Enlarge](#) [Download](#)

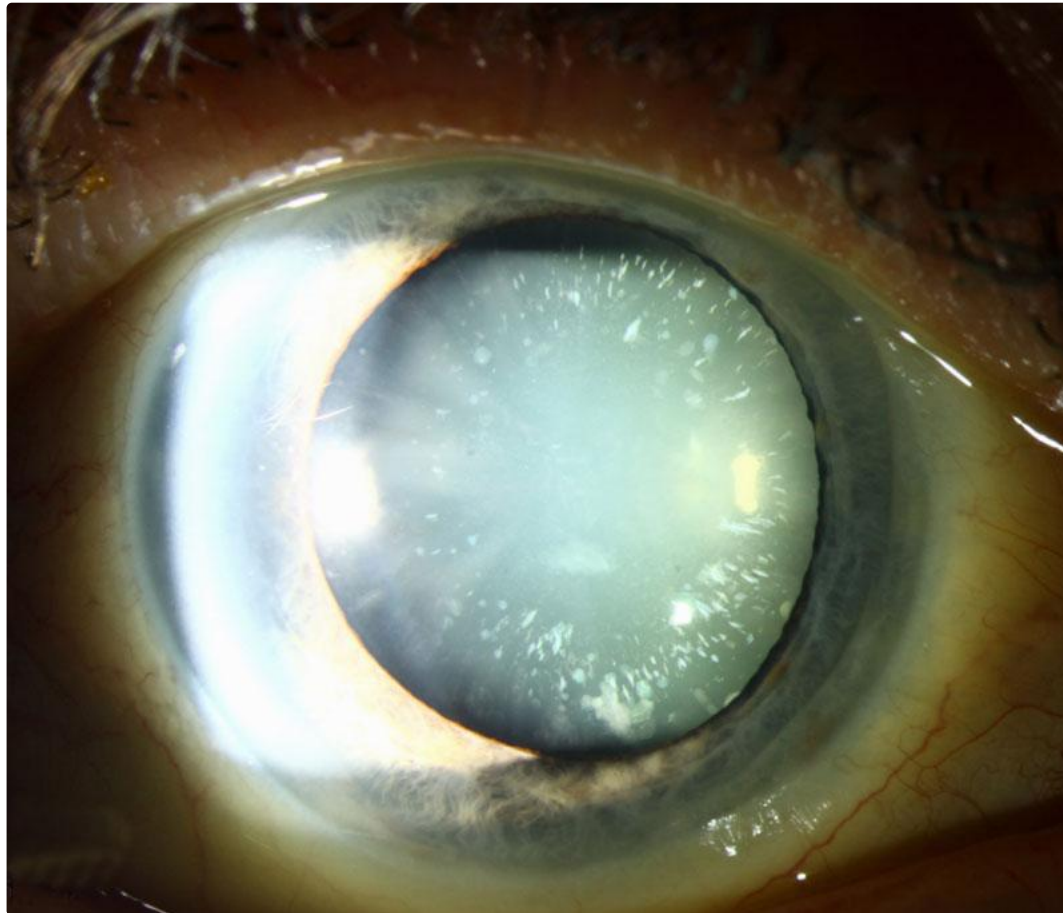




[Enlarge](#) [Download](#)

**Contributor:** Matt Ward, MD

This is a congenital cataract that is rarely visually significant and strikingly beautiful. Cerulean is a sky blue color, the word deriving from the Latin word for 'heaven' and also related to copper--imagine the blue color on tarnished copper.



[Enlarge](#) [Download](#)

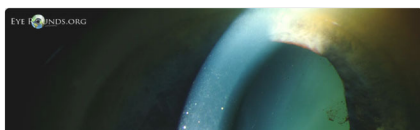
### Image Permissions:

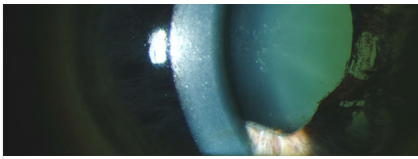


Ophthalmic Atlas Images by [EyeRounds.org](#), [The University of Iowa](#) are licensed under a [Creative Commons Attribution-NonCommercial-NoDerivs 3.0 Unported License](#).



### Related Articles





Glaukomflecken and iris atrophy after acute angle closure glaucoma

## Address

University of Iowa  
Roy J. and Lucille A. Carver College  
of Medicine  
Department of Ophthalmology and  
Visual Sciences  
200 Hawkins Drive  
Iowa City, IA 52242

[Support Us](#)

## Legal

Copyright © 2019 The University of  
Iowa. All Rights Reserved  
[Report an issue with this page](#)  
[Web Privacy Policy](#) |  
[Nondiscrimination Statement](#)

## Related Links

[Cataract Surgery for Greenhorns](#)  
[EyeTransillumination](#)  
[Gonioscopy.org](#)  
[Iowa Glaucoma Curriculum](#)  
[Iowa Wet Lab](#)  
[Patient Information](#)  
[Stone Rounds](#)  
[The Best Hits Bookshelf](#)

## EyeRounds Social Media

Follow



Receive notification of new cases,  
[sign up here](#)  
[Contact Us](#)  
[Submit a Suggestion](#)