

Coppock Cataract

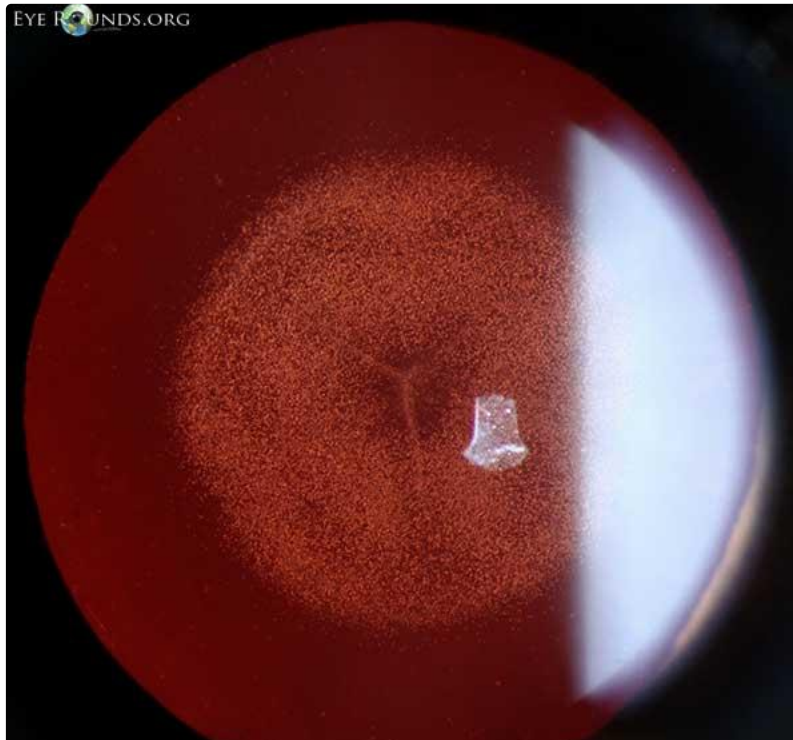
Category(ies): [Cataract](#), [Lens](#)

Contributor: [Elizabeth Gauger, MD](#)

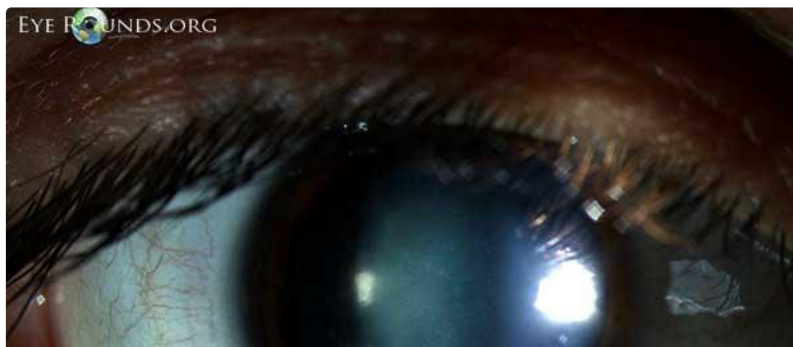Photographer: [Cindy Montague, CRA](#)

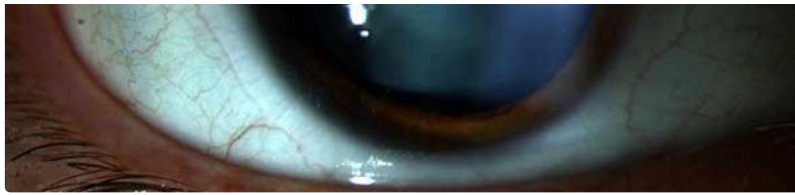


21-year-old female with history of bilateral congenital cataracts. This is called a "Coppock cataract," also known as a "central pulverulent cataract." It refers to a pulverulent disc-like opacity involving the embryonal and fetal nucleus with many tiny white dots in the lamellar portion of the lens. It is usually bilateral and dominantly inherited.



[Enlarge](#) [Download](#)

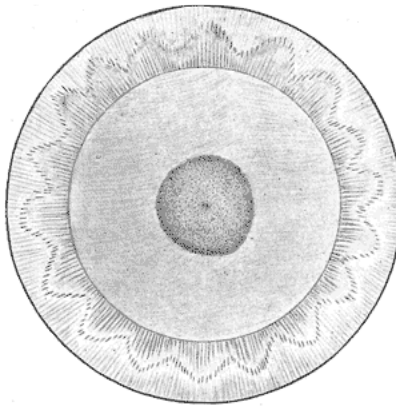




[Enlarge](#) [Download](#)

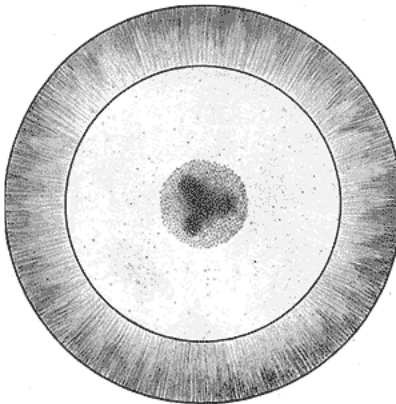
The patient's mother and older sister also have nearly identical-appearing cataracts. These cataracts were not removed, because in this case, they were non-amblyogenic. Patients with this type of congenital cataract often have excellent visual acuity and are unaware that they even have a cataract. This patient has 20/20 visual acuity.

Historical Images from Nettleship 1906



Nettleship (1906) Figure 1: Typical form of the cataract. Illustration from 1888, showing the lens appearance of William Coppock.

[Enlarge](#) [Download](#)



Nettleship (1906) Figure 2: Atypical form, showing a triradiate opacity of greater density than the rest.

[Enlarge](#) [Download](#)

References:

1. Nettleship E, Ogilvie F. A peculiar form of hereditary congenital cataract. *Trans Ophthalmol Soc UK*. 1906;26:191.

Image Permissions:



Ophthalmic Atlas Images by EyeRounds.org, The University of Iowa are licensed under a [Creative Commons Attribution-NonCommercial-NoDerivs 3.0 Unported License](https://creativecommons.org/licenses/by-nc-nd/3.0/).

Address

University of Iowa
Roy J. and Lucille A. Carver College
of Medicine
Department of Ophthalmology and
Visual Sciences
200 Hawkins Drive
Iowa City, IA 52242

[Support Us](#)

Legal

Copyright © 2019 The University of
Iowa. All Rights Reserved
[Report an issue with this page](#)
[Web Privacy Policy](#) |
[Nondiscrimination Statement](#)

Related Links

[Cataract Surgery for Greenhorns](#)
[EyeTransillumination](#)
[Gonioscopy.org](#)
[Iowa Glaucoma Curriculum](#)
[Iowa Wet Lab](#)
[Patient Information](#)
[Stone Rounds](#)
[The Best Hits Bookshelf](#)

EyeRounds Social Media

Follow



Receive notification of new cases,
[sign up here](#)
[Contact Us](#)
[Submit a Suggestion](#)