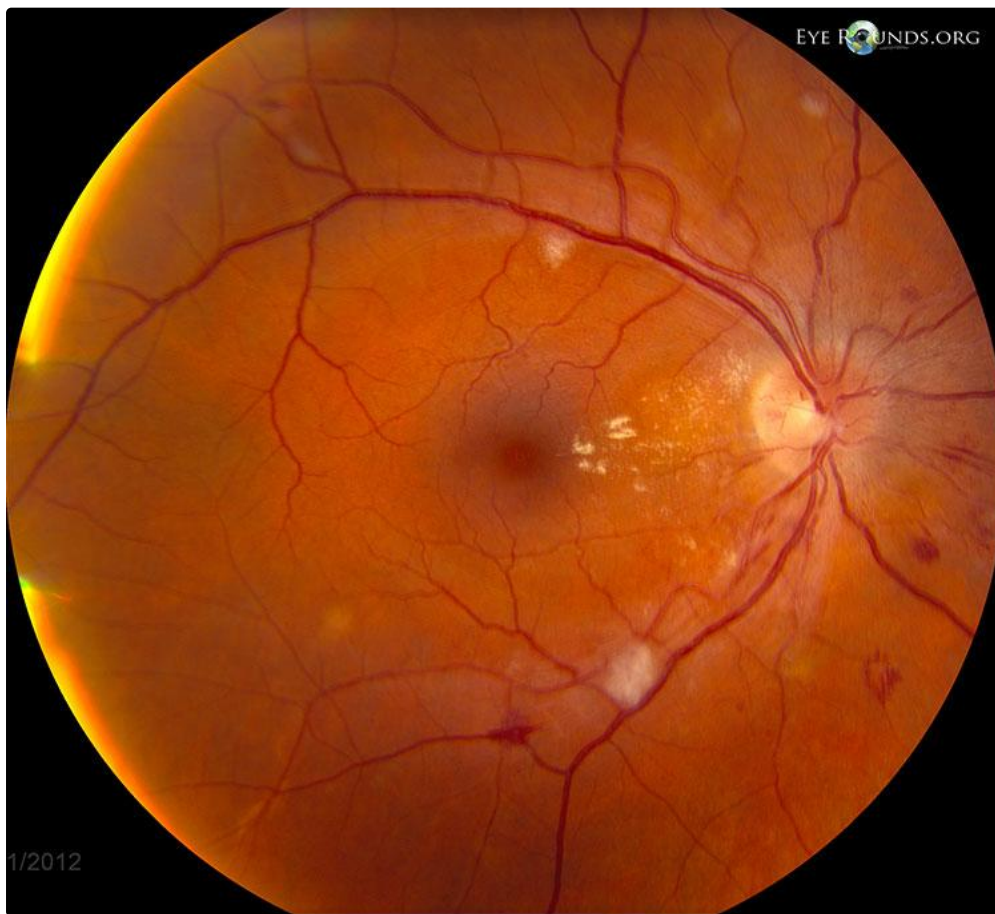


Hypertensive retinopathy

Category(ies): Retina, Vitreous

Contributor: Jaci Haugsdal, (4th year medical student) and [Justin Risma, MD](#)

Photographer: Cindy Montague, CRA



Hypertensive retinopathy: 37-year-old male with optic disc edema, cotton wool spots, flame hemorrhages, dot blot hemorrhages, arteriovenous nicking, and exudates. He was asymptomatic and his vision was 20/20 in both eyes. Blood pressure in clinic was 198/142.

[Enlarge](#) [Download](#)

Image Permissions:



Ophthalmic Atlas Images by [EyeRounds.org](#), [The University of Iowa](#) are licensed under a [Creative Commons Attribution-NonCommercial-NoDerivs 3.0 Unported License](#).

Address

University of Iowa
Roy J. and Lucille A. Carver College
of Medicine
Department of Ophthalmology and
Visual Sciences
200 Hawkins Drive
Iowa City, IA 52242

[Support Us](#)

Legal

Copyright © 2019 The University of
Iowa. All Rights Reserved
[Report an issue with this page](#)
[Web Privacy Policy](#) |
[Nondiscrimination Statement](#)

Related Links

[Cataract Surgery for Greenhorns](#)
[EyeTransillumination](#)
[Gonioscopy.org](#)
[Iowa Glaucoma Curriculum](#)
[Iowa Wet Lab](#)
[Patient Information](#)
[Stone Rounds](#)
[The Best Hits Bookshelf](#)

EyeRounds Social Media

Follow



Receive notification of new cases,
[sign up here](#)
[Contact Us](#)
[Submit a Suggestion](#)