

## Idiopathic Intracranial Hypertension (IIH)

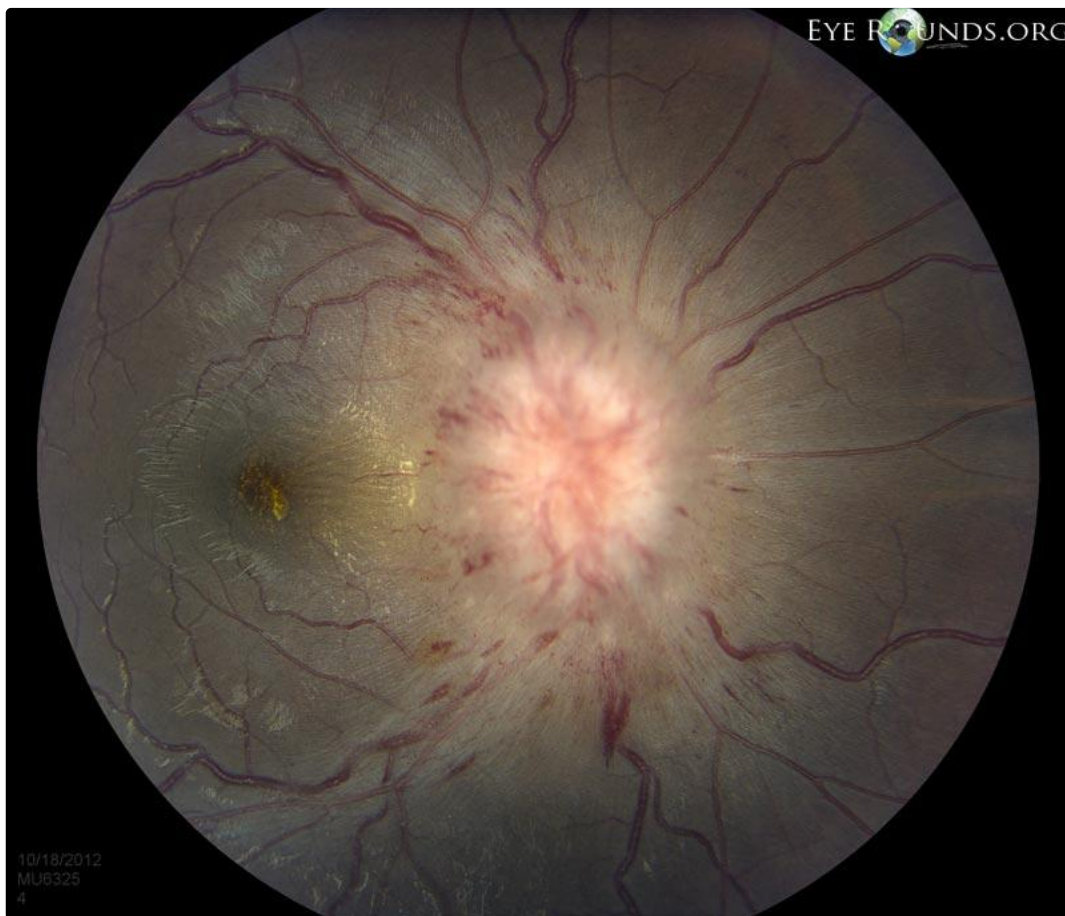
Category(ies): Neuro-ophthalmology

Contributor: Kimberly Wings, MD>

Photographer: Toni Venckus, CRA

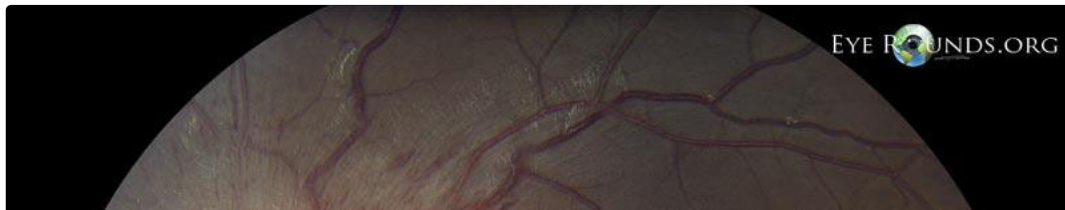


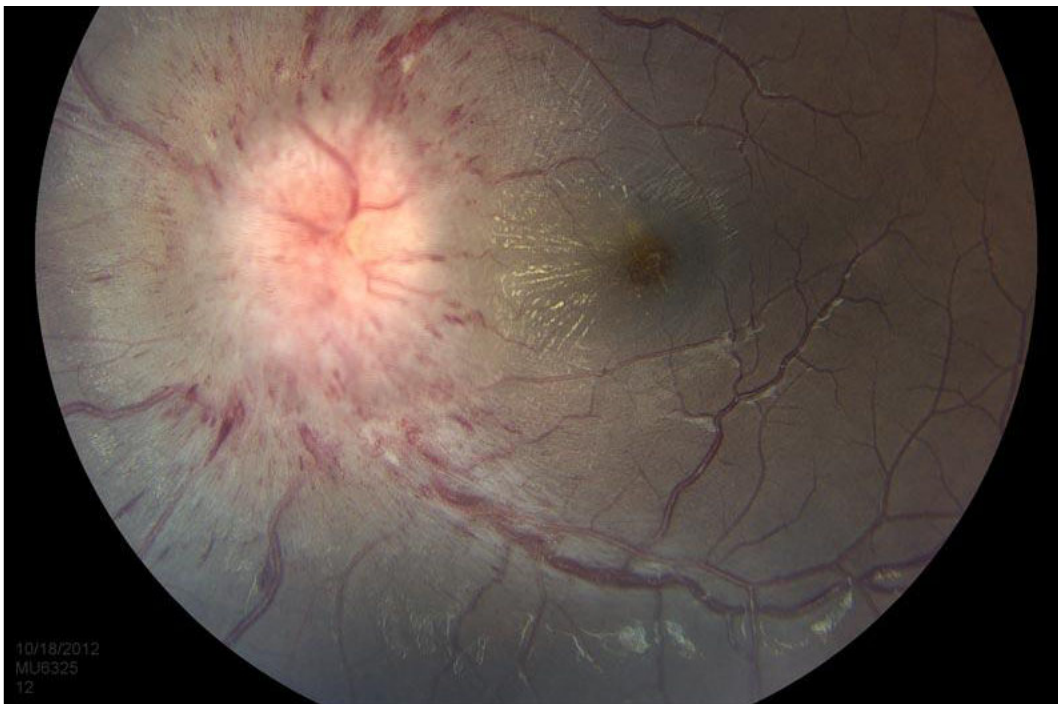IIH first presentation in a 19-year-old Female with pulse-synchronous tinnitus and positional headache. Papilledema Grade 4 in both eyes.



Right eye

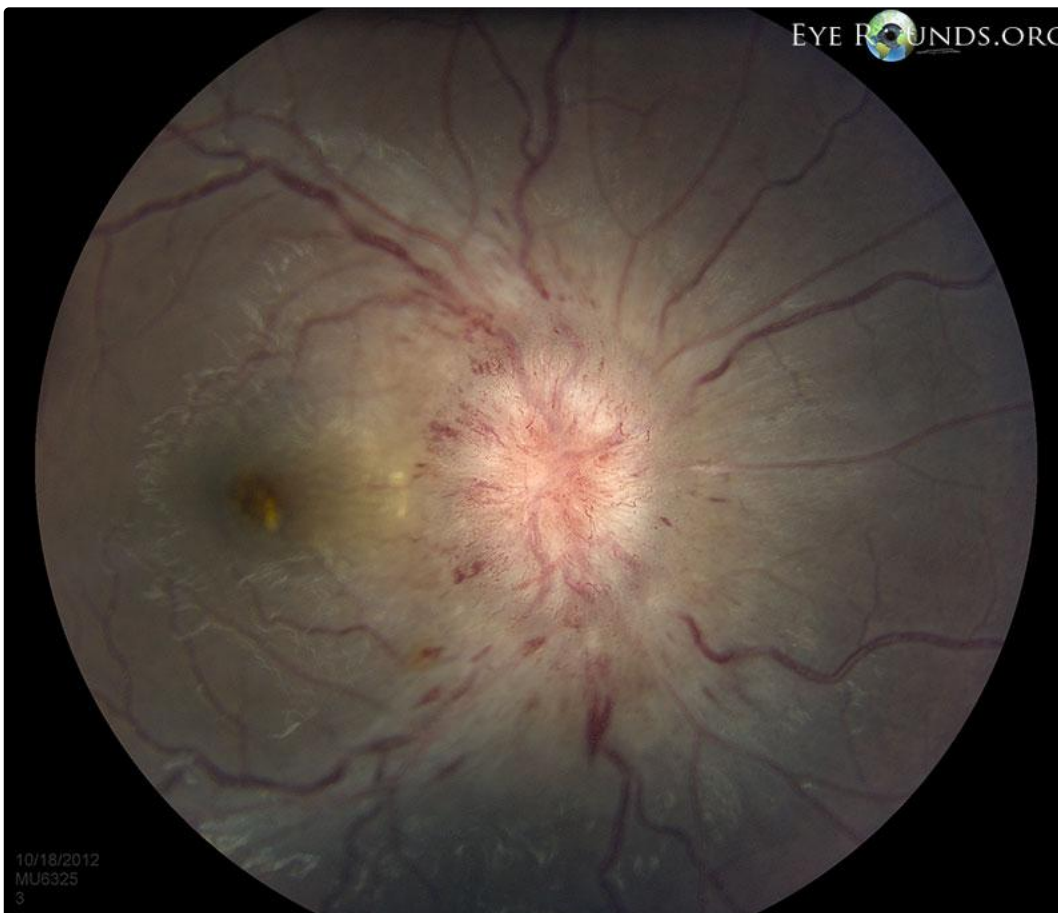
[Enlarge](#) [Download](#)





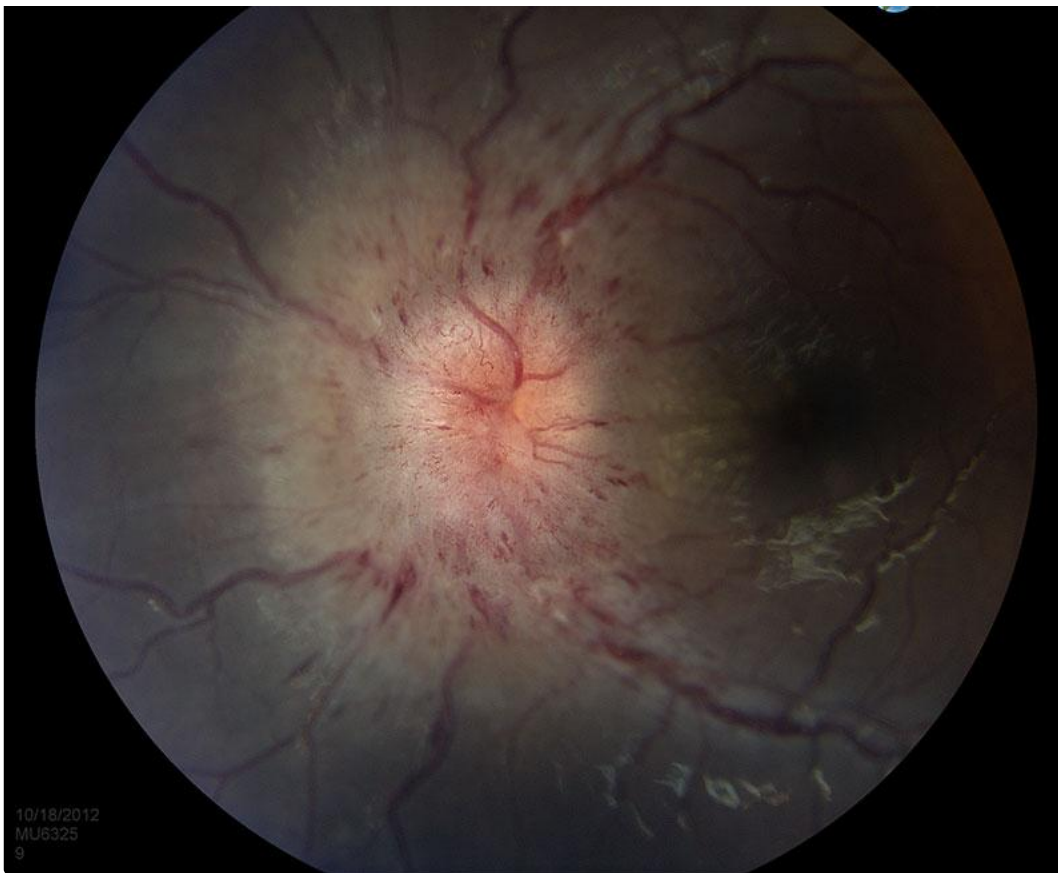Left eye

[Enlarge](#) [Download](#)



Right eye

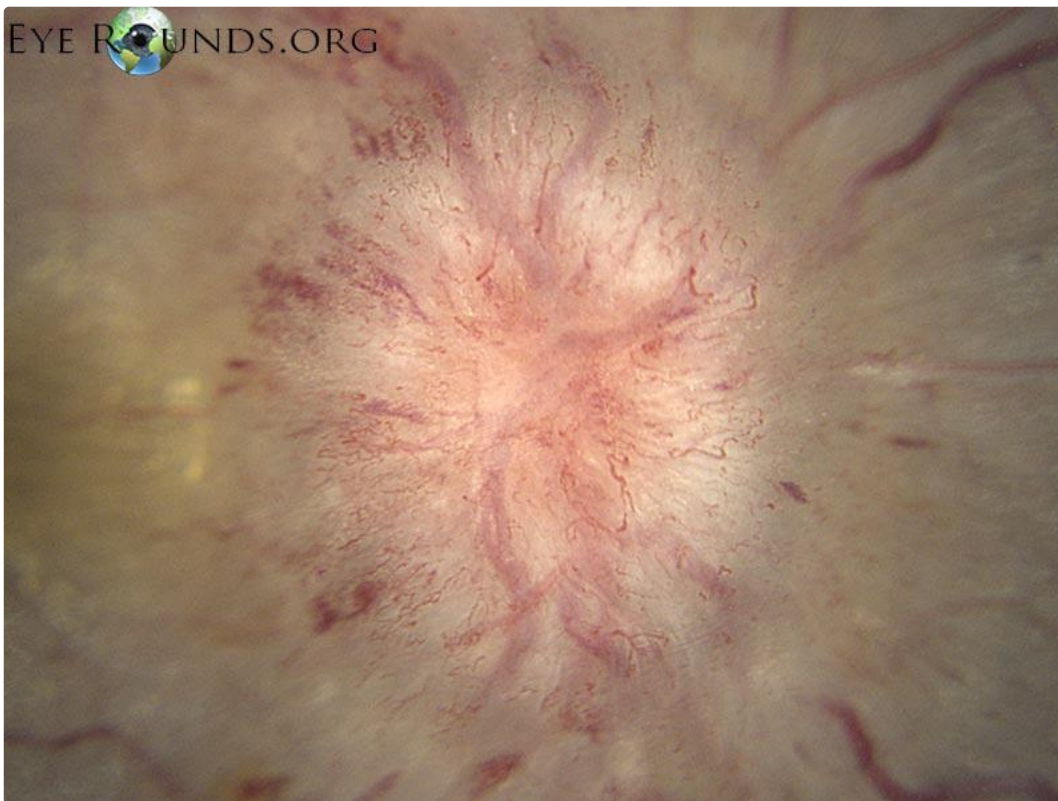[Enlarge](#) [Download](#)



Left eye

[Enlarge](#)

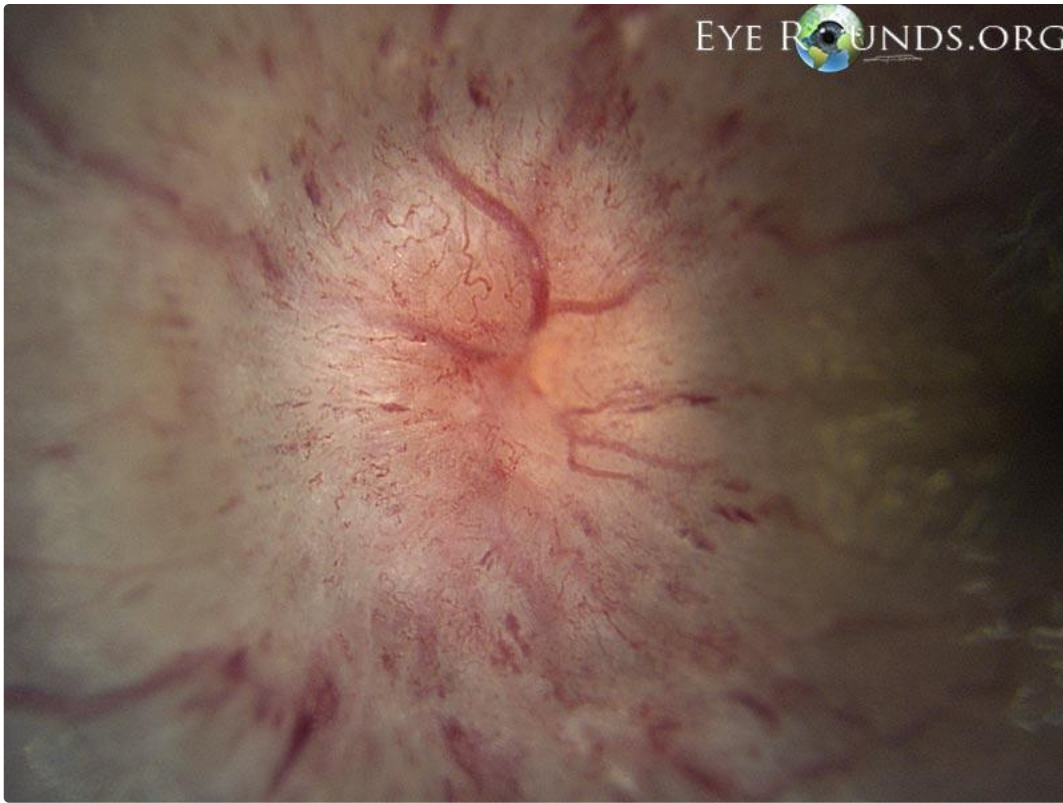[Download](#)



Right eye

[Enlarge](#)

[Download](#)



Left eye

[Enlarge](#) [Download](#)

### Image Permissions:



Ophthalmic Atlas Images by [EyeRounds.org](http://EyeRounds.org), [The University of Iowa](http://The University of Iowa) are licensed under a [Creative Commons Attribution-NonCommercial-NoDerivs 3.0 Unported License](http://creativecommons.org/licenses/by-nc-nd/3.0/).

### Address

University of Iowa  
Roy J. and Lucille A. Carver College  
of Medicine  
Department of Ophthalmology and  
Visual Sciences  
200 Hawkins Drive  
Iowa City, IA 52242

[Support Us](#)

### Legal

Copyright © 2019 The University of  
Iowa. All Rights Reserved  
[Report an issue with this page](#)  
[Web Privacy Policy](#) |  
[Nondiscrimination Statement](#)

### Related Links

[Cataract Surgery for Greenhorns](#)  
[EyeTransillumination](#)  
[Gonioscopy.org](#)  
[Iowa Glaucoma Curriculum](#)  
[Iowa Wet Lab](#)  
[Patient Information](#)  
[Stone Rounds](#)  
[The Best Hits Bookshelf](#)

### EyeRounds Social Media

Follow



Receive notification of new cases,  
sign up here  
[Contact Us](#)  
[Submit a Suggestion](#)