

Intrapapillary Hemorrhage

Category(ies): Glaucoma, Neuro-ophthalmology

Contributor: [Heather A. Stiff, MD](#); [David A. Ramirez, MD](#); [Nathaniel C. Sears, MD](#)

Photographer: Antoinette Venckus

A 62-year-old female with primary open angle glaucoma was seen in the glaucoma clinic for follow-up and was incidentally found to have an intrapapillary hemorrhage in her right eye as shown below (figure 1). Intrapapillary hemorrhages are more common near the nasal border of the nerve in myopic eyes with tilted discs, and may be spontaneous or precipitated by acute disc edema, valsalva maneuver, or vitreopapillary traction [1]. The patient in this scenario was not myopic, and underwent echography to rule out optic nerve drusen or a vascular tumor. It was later revealed that she had been coughing recently, possibly leading to a valsalva maneuver. These hemorrhages generally have a good prognosis and resolve spontaneously [1,2]. Of note, this hemorrhage is different than the typical peripapillary hemorrhage seen in normal tension glaucoma, which is located on the border of the border of the optic disc (see [Optic Disc Hemorrhage in Normal Tension Glaucoma](#)).

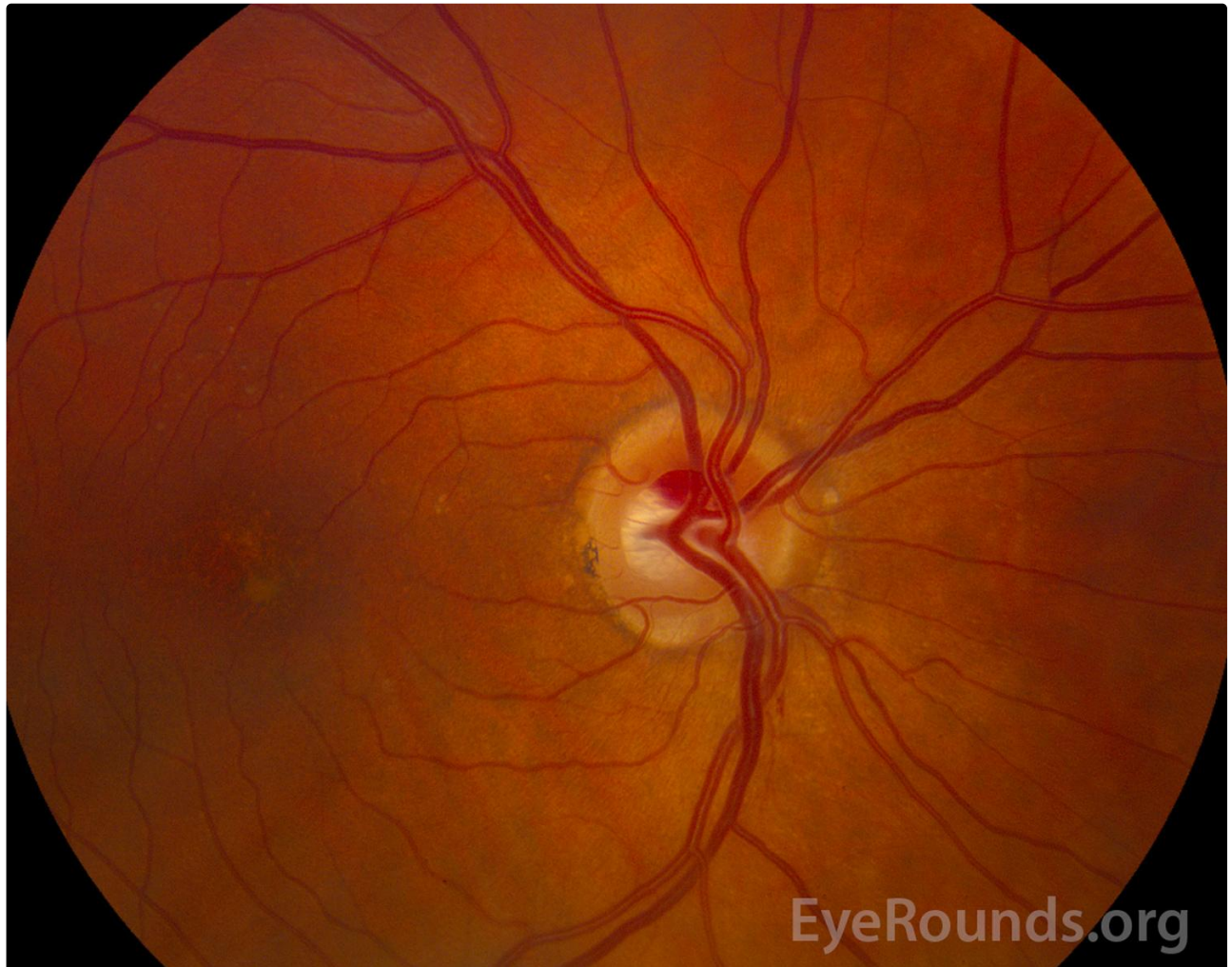


Figure 1. Color fundus photography of the right eye shows an intrapapillary hemorrhage of the superior portion of the optic nerve extending from 11:30-1:00 with adjacent hyperemia of the optic disc.

Reference:

- Kokame GT, Yamamoto I, Kishi S, Tamura A, Drouilhet JH. Intrapapillary hemorrhage with adjacent peripapillary subretinal hemorrhage. *Ophthalmology* 2004;111(5):926-930. <https://PubMed.gov/15121370>. DOI: 10.1016/j.optha.2003.08.040
- Moon IH, Lee SC, Kim M. Intrapapillary hemorrhage with concurrent peripapillary and vitreous hemorrhage in two healthy young patients. *BMC Ophthalmol* 2018;18(1):172. <https://PubMed.gov/30005697>. DOI: 10.1186/s12886-018-0833-z

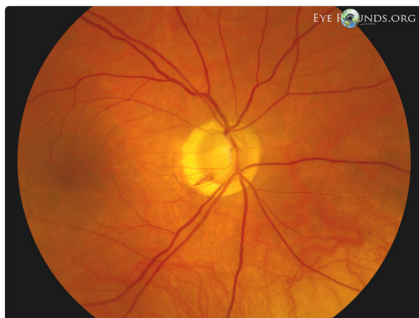Image Permissions:



Ophthalmic Atlas Images by [EyeRounds.org](https://www.eyerounds.org), [The University of Iowa](https://www.theuniversityofiowa.edu) are licensed under a [Creative Commons Attribution-NonCommercial-NoDerivs 3.0 Unported License](https://creativecommons.org/licenses/by-nc-nd/3.0/).



Related Articles



[Related Atlas Entry: Optic disc hemorrhage in normal tension glaucoma](#)

Address

University of Iowa
Roy J. and Lucille A. Carver College
of Medicine
Department of Ophthalmology and
Visual Sciences
200 Hawkins Drive
Iowa City, IA 52242

[Support Us](#)

Legal

Copyright © 2019 The University of
Iowa. All Rights Reserved
[Report an issue with this page](#)
[Web Privacy Policy](#) |
[Nondiscrimination Statement](#)

Related Links

[Cataract Surgery for Greenhorns](#)
[EyeTransillumination](#)
[Gonioscopy.org](#)
[Iowa Glaucoma Curriculum](#)
[Iowa Wet Lab](#)
[Patient Information](#)
[Stone Rounds](#)
[The Best Hits Bookshelf](#)

EyeRounds Social Media

Follow



[Receive notification of new cases,
sign up here](#)
[Contact Us](#)
[Submit a Suggestion](#)