

Morgagnian cataract with absent cortex

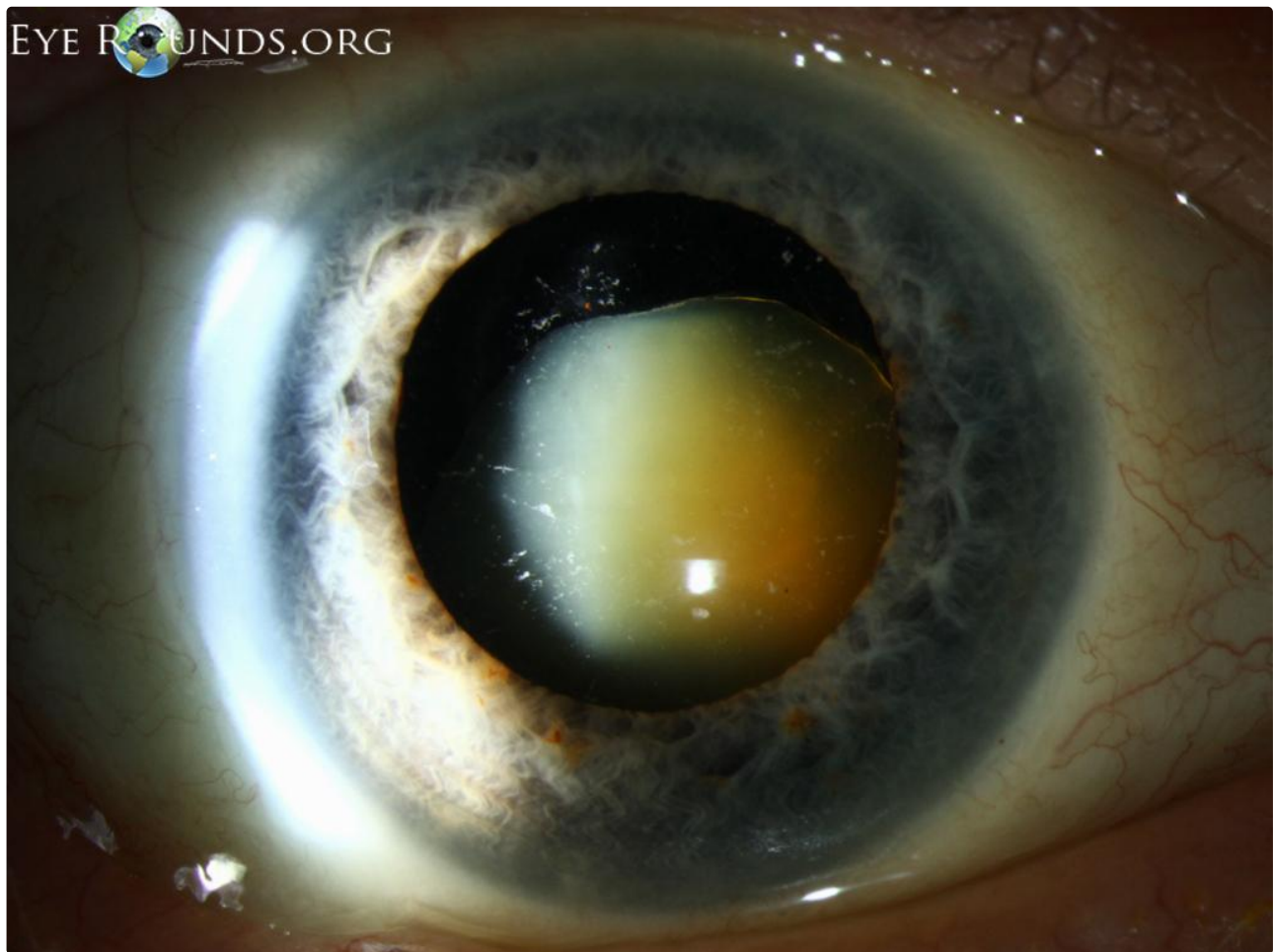Category(ies): [Cataract, Lens](#)

Contributor: [Christopher A. Kirkpatrick, MD](#) and Anna Kitzmann, MD

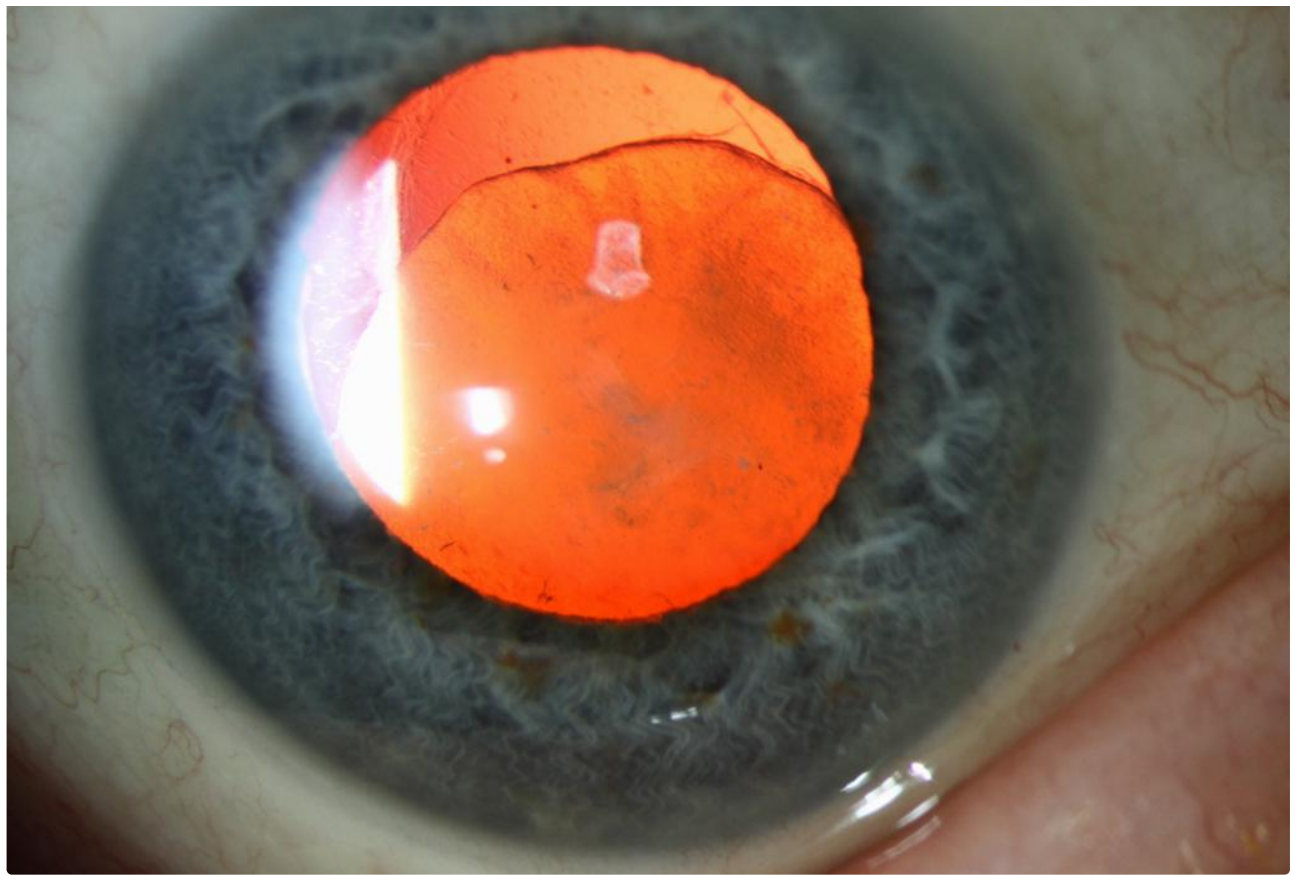
Photographer: [Brice Critser, CRA](#)



A Morgagnian cataract is a hypermature cataract in which there is typically liquefaction of the lens cortex with dense sclerosis of the nucleus. This presentation is typical for the brunescient lens nucleus that is inferiorly displaced within the capsule, but atypical in that there is no lens cortex remaining, the previously liquified cortex has migrated through the intact capsule, leaving only a sunken, hard nucleus in an empty capsular bag



[🔍 Enlarge](#) [📄 Download](#)



[Enlarge](#) [Download](#)

Image Permissions:



Ophthalmic Atlas Images by EyeRounds.org, The University of Iowa are licensed under a [Creative Commons Attribution-NonCommercial-NoDerivs 3.0 Unported License](https://creativecommons.org/licenses/by-nc-nd/3.0/).

Address

University of Iowa
Roy J. and Lucille A. Carver College
of Medicine
Department of Ophthalmology and
Visual Sciences
200 Hawkins Drive
Iowa City, IA 52242

[Support Us](#)

Legal

Copyright © 2019 The University of
Iowa. All Rights Reserved
[Report an issue with this page](#)
[Web Privacy Policy](#) |
[Nondiscrimination Statement](#)

Related Links

[Cataract Surgery for Greenhorns](#)
[EyeTransillumination](#)
[Gonioscopy.org](#)
[Iowa Glaucoma Curriculum](#)
[Iowa Wet Lab](#)
[Patient Information](#)
[Stone Rounds](#)
[The Best Hits Bookshelf](#)

EyeRounds Social Media

Follow



Receive notification of new cases,
sign up here
[Contact Us](#)
[Submit a Suggestion](#)