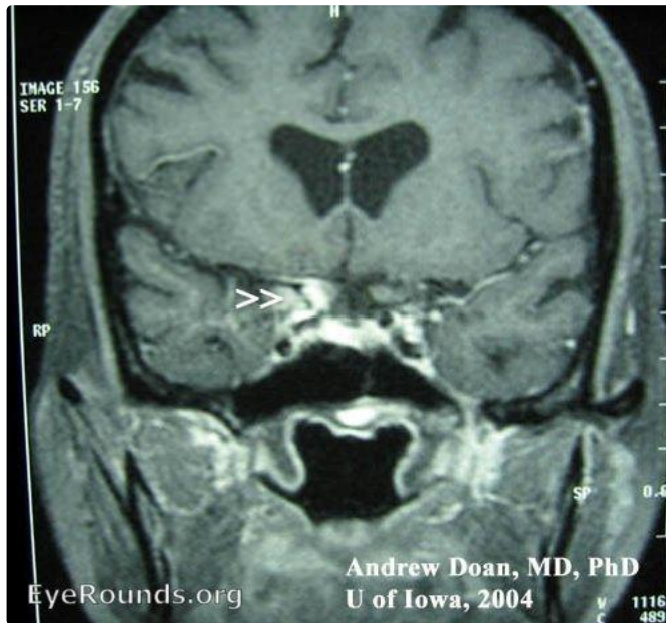


EyeRounds.org

Neurosarcoidosis

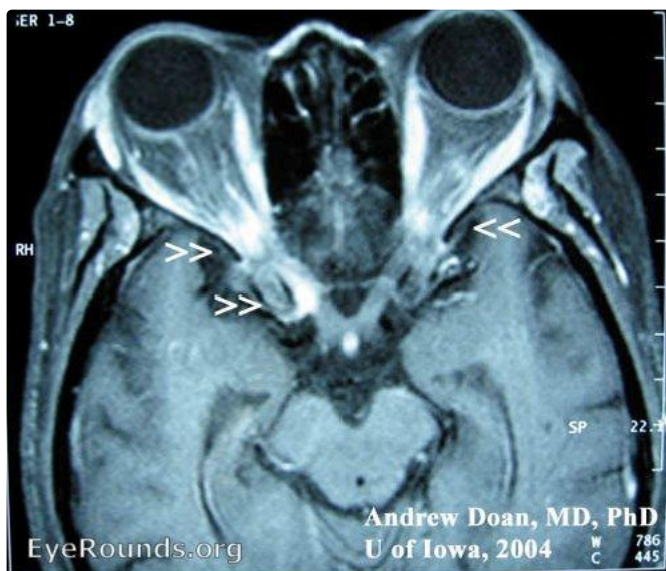
Category(ies): Neuro-ophthalmology

Contributor: [Andrew Doan, MD, PhD](#)



MRI scans with optic nerve enhancement

[Enlarge](#) [Download](#)



MRI scans with optic nerve enhancement

[Enlarge](#) [Download](#)

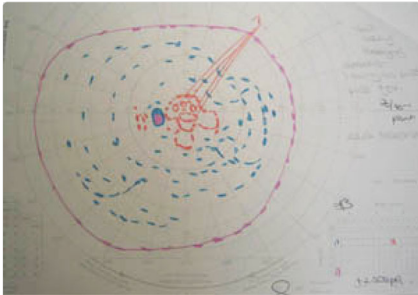
Image Permissions:



Ophthalmic Atlas Images by [EyeRounds.org](https://www.eyerounds.org), [The University of Iowa](https://www.theuniversityofiowa.edu) are licensed under a [Creative Commons Attribution-NonCommercial-NoDerivs 3.0 Unported License](https://creativecommons.org/licenses/by-nc-nd/3.0/).



Related Articles



[Related Case: Sarcoidosis](#)

Address

University of Iowa
Roy J. and Lucille A. Carver College
of Medicine
Department of Ophthalmology and
Visual Sciences
200 Hawkins Drive
Iowa City, IA 52242

[Support Us](#)

Legal

Copyright © 2019 The University of
Iowa. All Rights Reserved
[Report an issue with this page](#)
[Web Privacy Policy](#) |
[Nondiscrimination Statement](#)

Related Links

[Cataract Surgery for Greenhorns](#)
[EyeTransillumination](#)
[Gonioscopy.org](https://www.gonioscopy.org)
[Iowa Glaucoma Curriculum](#)
[Iowa Wet Lab](#)
[Patient Information](#)
[Stone Rounds](#)
[The Best Hits Bookshelf](#)

EyeRounds Social Media

Follow



Receive notification of new cases,
[sign up here](#)
[Contact Us](#)
[Submit a Suggestion](#)