

Ocular Hypertension, dilated episcleral vessels, blood in Schlemm's canal

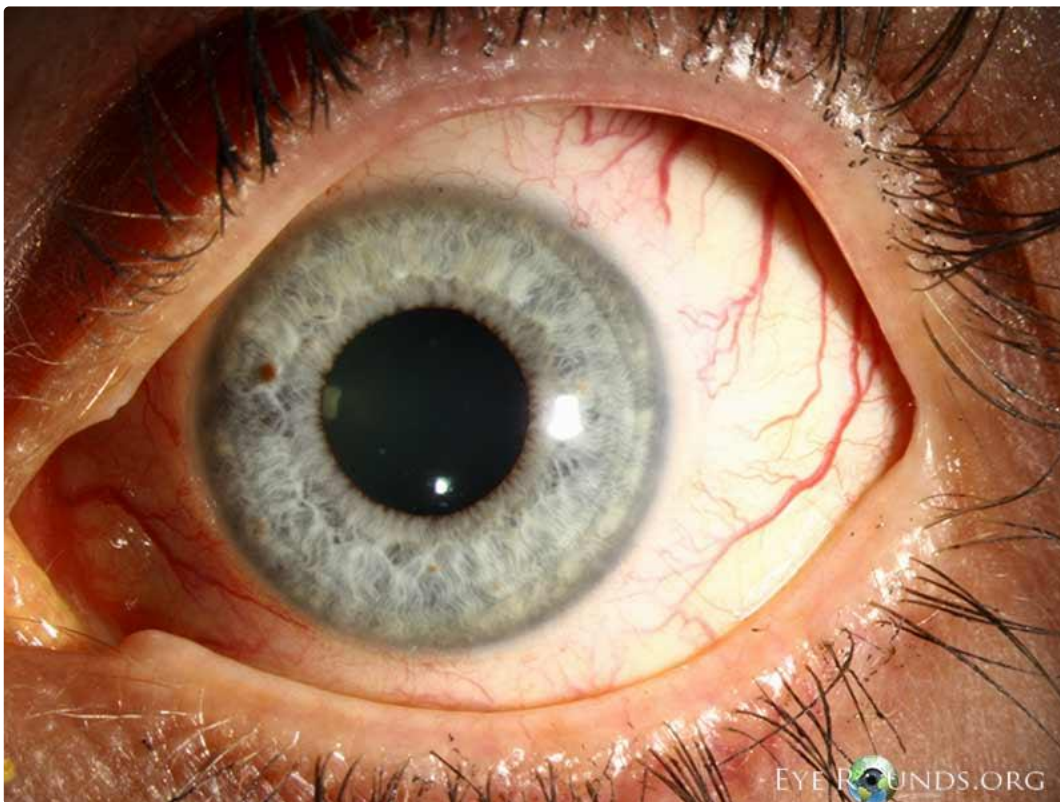
Category(ies): [Glaucoma](#), [Iris](#)

Contributor: [Kimberly Wings, MD](#)

Photographer: [D. Brice Critser, CRA](#)

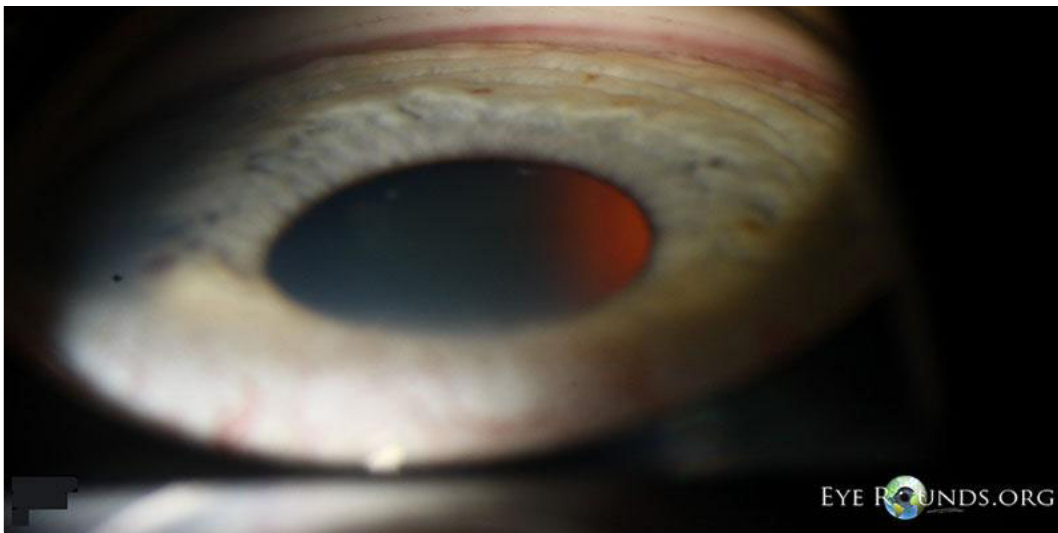


The patient is a 46-year-old Female with ocular hypertension who has had long-standing dilated episcleral vessels and blood in Schlemm's canal in the left eye but no evidence for carotid-cavernous fistula on intracranial imaging.



[Enlarge](#) [Download](#)





[🔍 Enlarge](#) [📄 Download](#)

Image Permissions:



Ophthalmic Atlas Images by [EyeRounds.org](#), [The University of Iowa](#) are licensed under a [Creative Commons Attribution-NonCommercial-NoDerivs 3.0 Unported License](#).

Address

University of Iowa
Roy J. and Lucille A. Carver College
of Medicine
Department of Ophthalmology and
Visual Sciences
200 Hawkins Drive
Iowa City, IA 52242

[Support Us](#)

Legal

Copyright © 2019 The University of
Iowa. All Rights Reserved
[Report an issue with this page](#)
[Web Privacy Policy I](#)
[Nondiscrimination Statement](#)

Related Links

[Cataract Surgery for Greenhorns](#)
[EyeTransillumination](#)
[Gonioscopy.org](#)
[Iowa Glaucoma Curriculum](#)
[Iowa Wet Lab](#)
[Patient Information](#)
[Stone Rounds](#)
[The Best Hits Bookshelf](#)

EyeRounds Social Media

Follow



Receive notification of new cases,
[sign up here](#)
[Contact Us](#)
[Submit a Suggestion](#)