

Polypoidal choroidal vasculopathy (PCV)

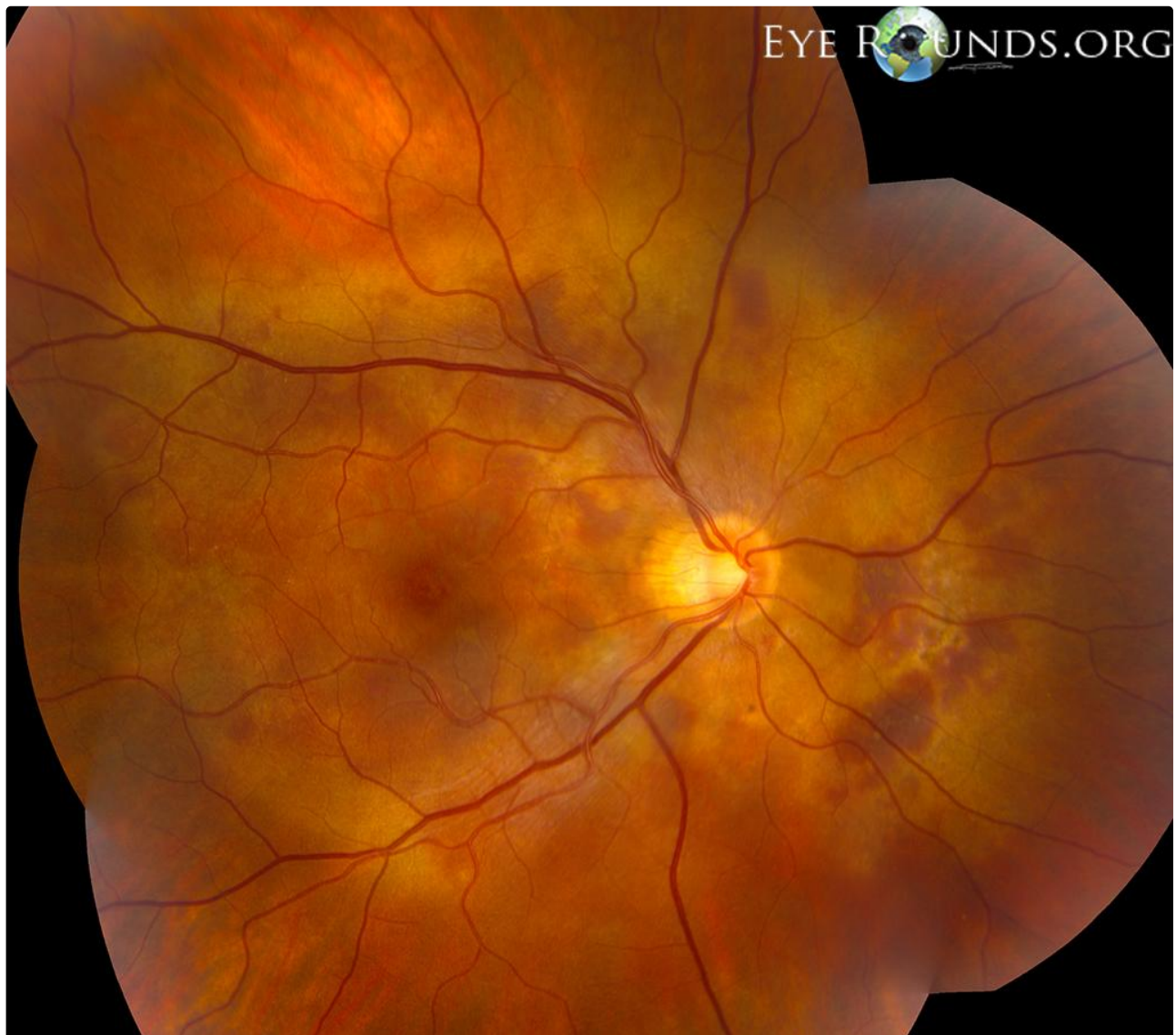
Category(ies): Retina, Vitreous

Contributor: [Jesse Vislisel, MD](#)

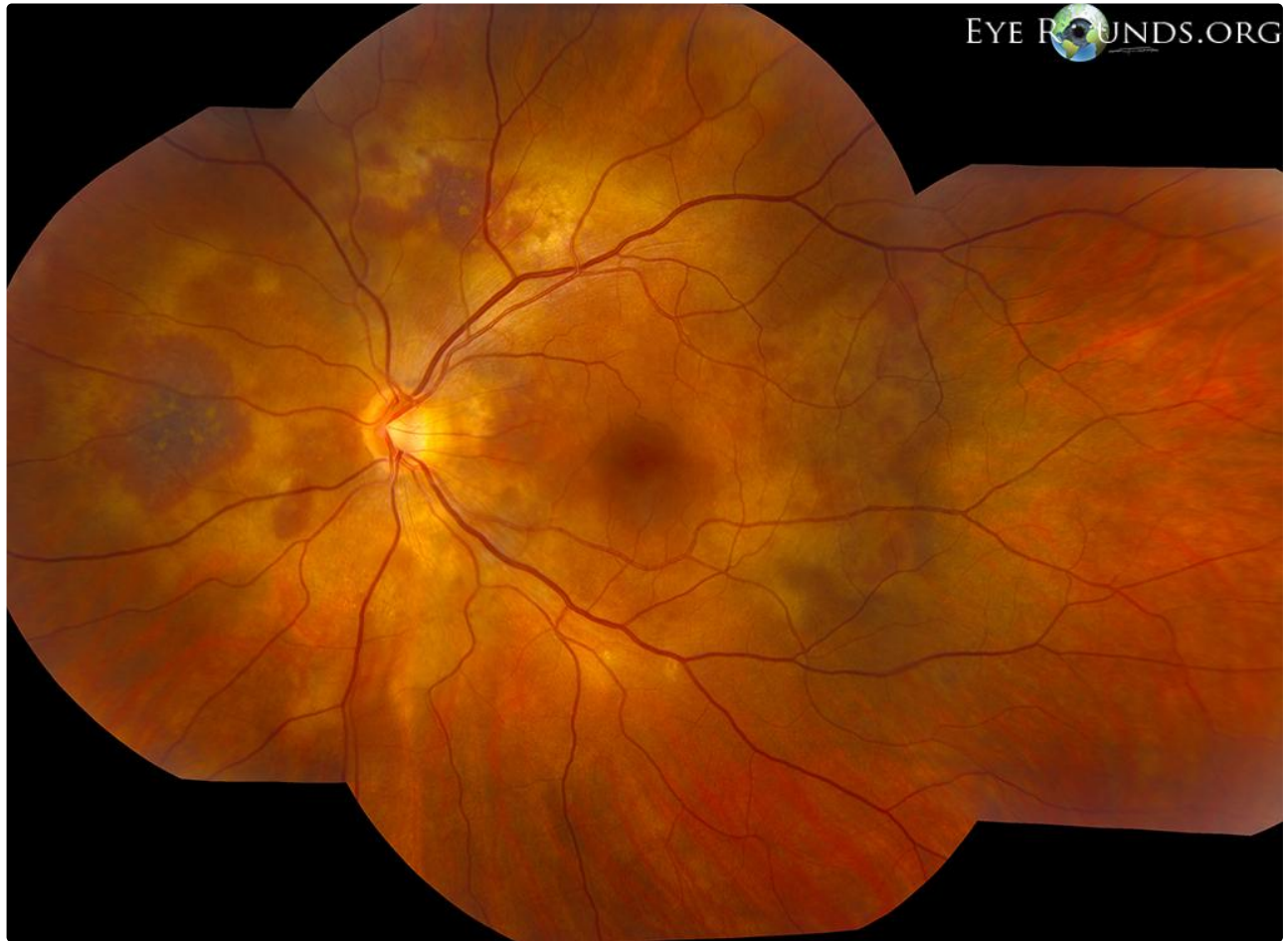Photographer: Brice Critser, CRA



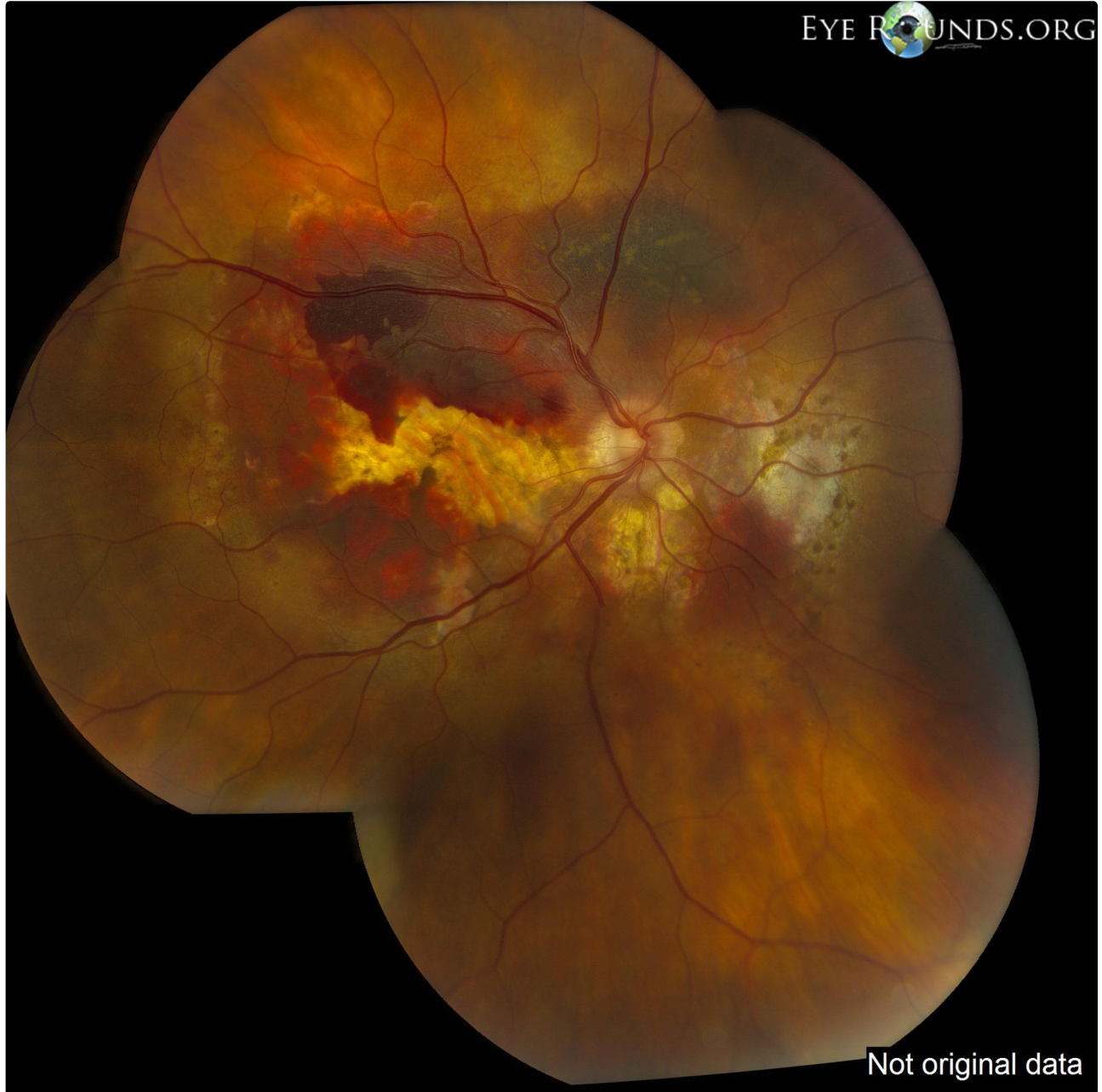Polypoidal choroidal vasculopathy (PCV), also known as posterior uveal bleeding syndrome, is a condition characterized by chronic, multiple, recurrent serosanguinous retinal pigment epithelium detachments secondary to an abnormal network of underlying choroidal vessels. Multiple areas of subretinal hemorrhage are visible in these photos. They are surrounded by areas of yellow subretinal material which likely represents old hemorrhage.



Right Eye



Left Eye



The photograph shows the fundus appearance after the patient later presented with an acute subretinal hemorrhage in the right eye.

[Enlarge](#) [Download](#)

Image Permissions.



Ophthalmic Atlas Images by EyeRounds.org, The University of Iowa are licensed under a [Creative Commons Attribution-NonCommercial-NoDerivs 3.0 Unported License](https://creativecommons.org/licenses/by-nc-nd/3.0/).

Address

University of Iowa
Roy J. and Lucille A. Carver College
of Medicine
Department of Ophthalmology and
Visual Sciences
200 Hawkins Drive
Iowa City, IA 52242

[Support Us](#)

Legal

Copyright © 2019 The University of
Iowa. All Rights Reserved
[Report an issue with this page](#)
[Web Privacy Policy |](#)
[Nondiscrimination Statement](#)

Related Links

[Cataract Surgery for Greenhorns](#)
[EyeTransillumination](#)
[Gonioscopy.org](#)
[Iowa Glaucoma Curriculum](#)
[Iowa Wet Lab](#)
[Patient Information](#)
[Stone Rounds](#)
[The Best Hits Bookshelf](#)

**EyeRounds Social
Media**

Follow



Receive notification of new cases,
[sign up here](#)
[Contact Us](#)
[Submit a Suggestion](#)