

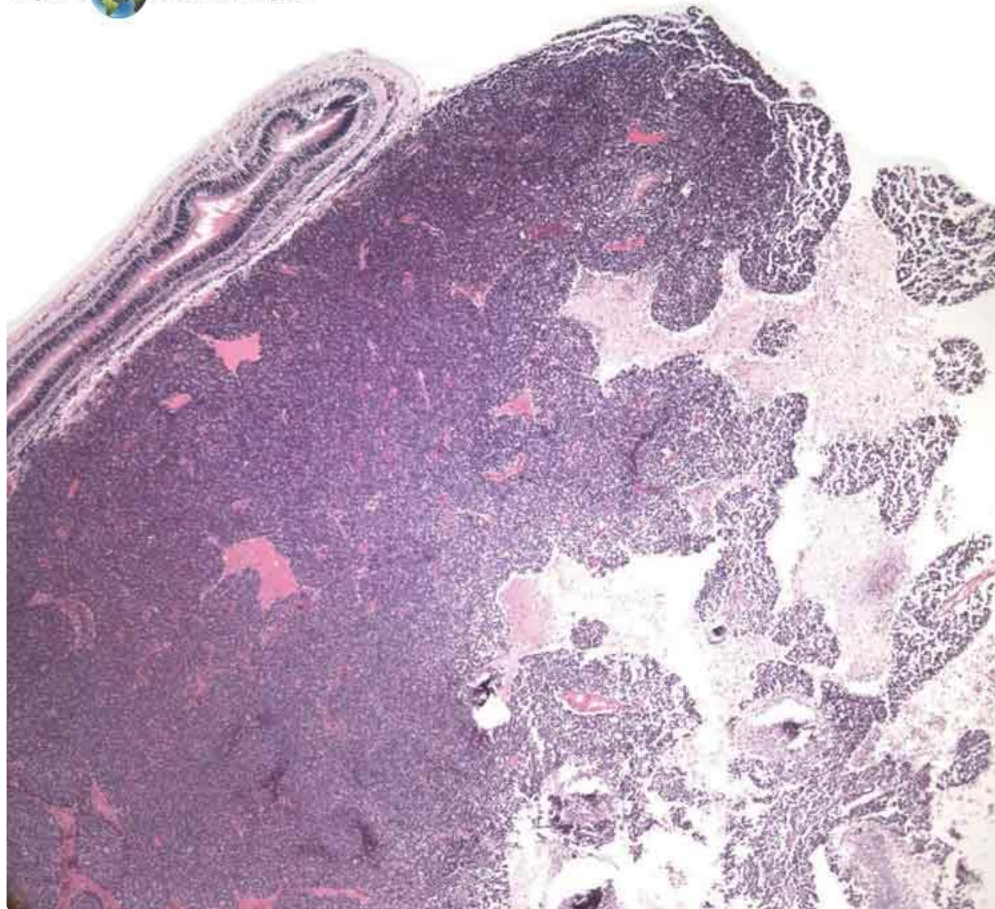
EyeRounds.org

Retinoblastoma

Category(ies): Pathology

Contributor: [Meagan Seay, DO](#) and [Nasreen Syed, MD](#)

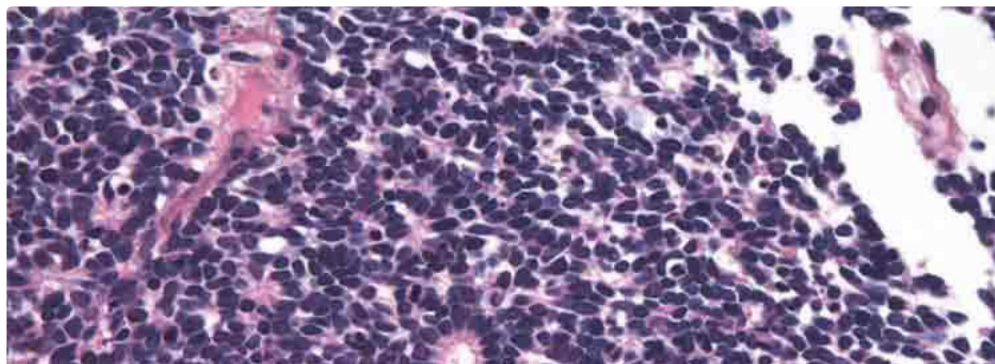
EYE ROUNDS.ORG

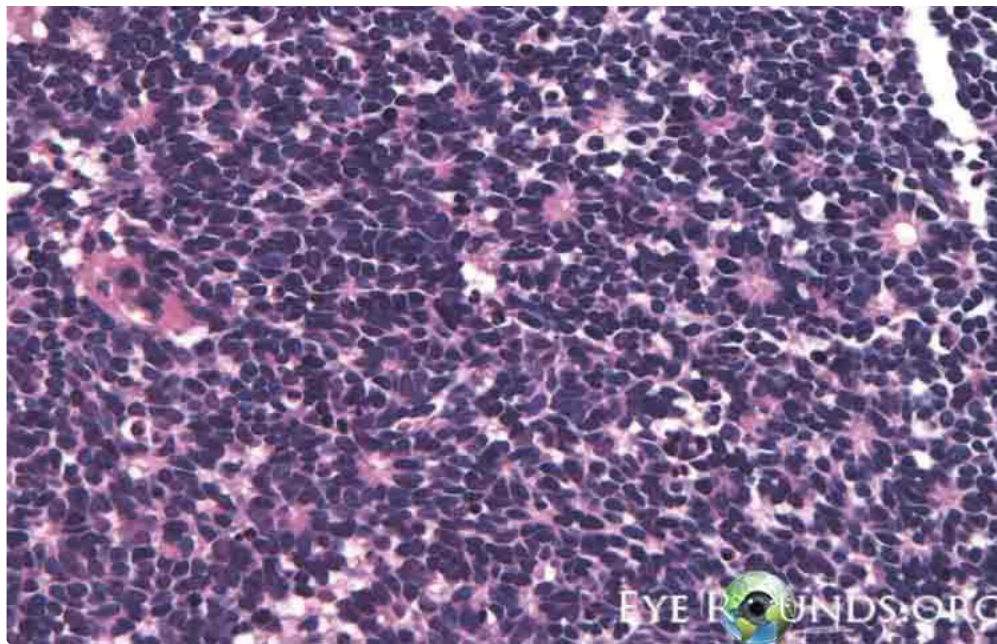


Retinoblastoma is a small, round, blue cell tumor. The pink areas are necroses.

[Enlarge](#)

[Download](#)





Flexner-Wintersteiner rosettes contain a central lumen. Homer Wright rosettes contain neurofibrillary tangles in the center.

[Enlarge](#)

[Download](#)

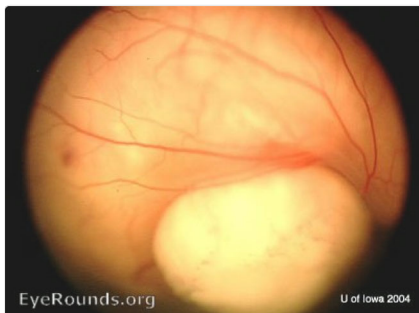
Image Permissions:



Ophthalmic Atlas Images by EyeRounds.org, The University of Iowa are licensed under a [Creative Commons Attribution-NonCommercial-NoDerivs 3.0 Unported License](https://creativecommons.org/licenses/by-nc-nd/3.0/).



Related Articles



[Related Atals Entry: Retinoblastoma](#)

University of Iowa
Roy J. and Lucille A. Carver College
of Medicine
Department of Ophthalmology and
Visual Sciences
200 Hawkins Drive
Iowa City, IA 52242

[Support Us](#)

Copyright © 2019 The University of
Iowa. All Rights Reserved
[Report an issue with this page](#)
[Web Privacy Policy](#) |
[Nondiscrimination Statement](#)

[EyeTransillumination](#)
[Gonioscopy.org](#)
[Iowa Glaucoma Curriculum](#)
[Iowa Wet Lab](#)
[Patient Information](#)
[Stone Rounds](#)
[The Best Hits Bookshelf](#)

Follow



Receive notification of new cases,
[sign up here](#)
[Contact Us](#)
[Submit a Suggestion](#)