

Spontaneous Phakic Lens Dislocation in Pseudoexfoliation Syndrome

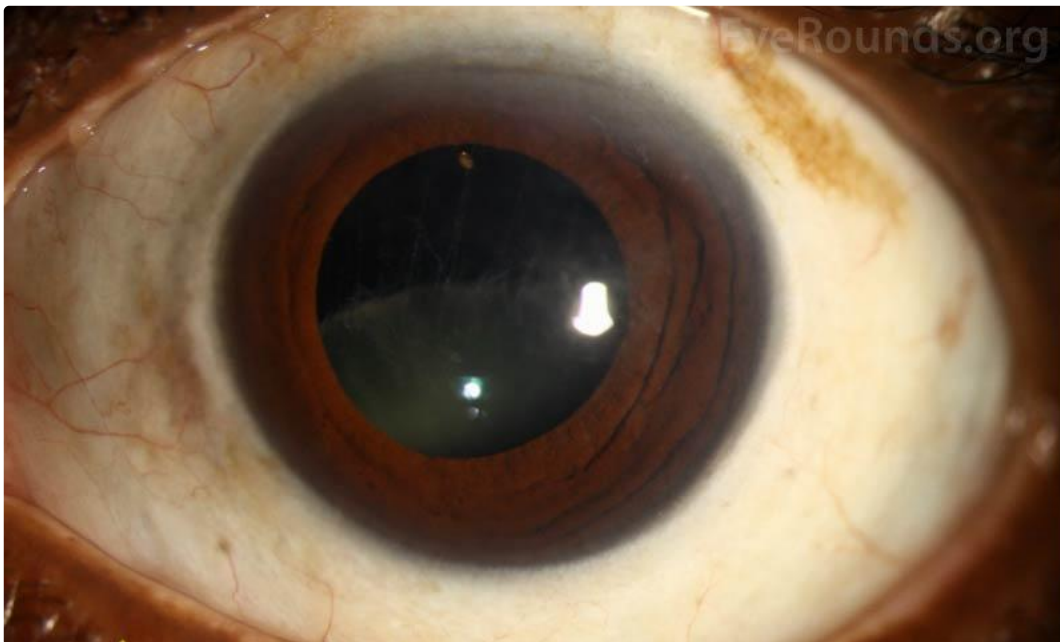Category(ies): Cataract

Contributor: [Mahsaw Motlagh, MD](#) and [Ryan Diel, MD](#)


Photographer: Sarah Skiles



An 81-year-old female with a known history of pseudoexfoliation glaucoma presented for cataract evaluation of the left eye. On examination, her natural crystalline lens had dislocated inferiorly with zonular dehiscence and dialysis superiorly. The zonules were densely coated in white fibrillar material characteristic of pseudoexfoliation syndrome.

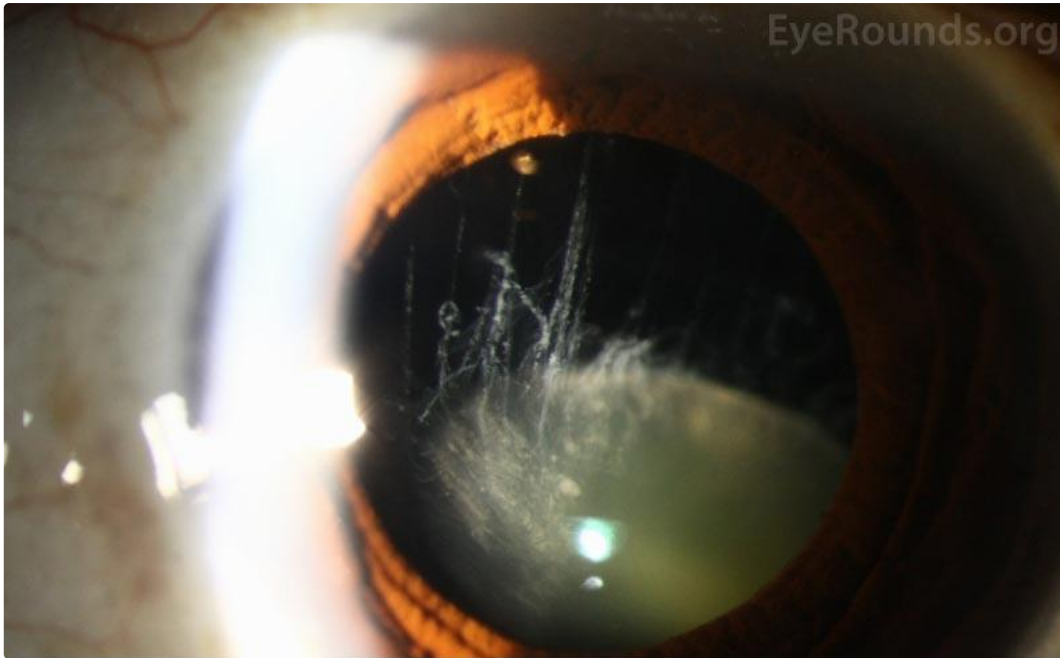


[Enlarge](#) [Download](#)





[Enlarge](#) [Download](#)



[Enlarge](#) [Download](#)

Image Permissions:



Ophthalmic Atlas Images by [EyeRounds.org](#), [The University of Iowa](#) are licensed under a [Creative Commons Attribution-NonCommercial-NoDerivs 3.0 Unported License](#).

Address

University of Iowa
Roy J. and Lucille A. Carver College
of Medicine
Department of Ophthalmology and
Visual Sciences
200 Hawkins Drive
Iowa City, IA 52242

[Support Us](#)

Legal

Copyright © 2019 The University of
Iowa. All Rights Reserved
[Report an issue with this page](#)
[Web Privacy Policy](#) |
[Nondiscrimination Statement](#)

Related Links

[Cataract Surgery for Greenhorns](#)
[EyeTransillumination](#)
[Gonioscopy.org](#)
[Iowa Glaucoma Curriculum](#)
[Iowa Wet Lab](#)
[Patient Information](#)
[Stone Rounds](#)
[The Best Hits Bookshelf](#)

EyeRounds Social Media

Follow



Receive notification of new cases,
[sign up here](#)
[Contact Us](#)
[Submit a Suggestion](#)

