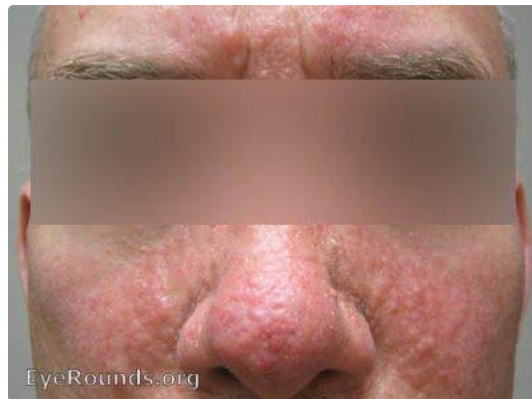

## Tuberous sclerosis

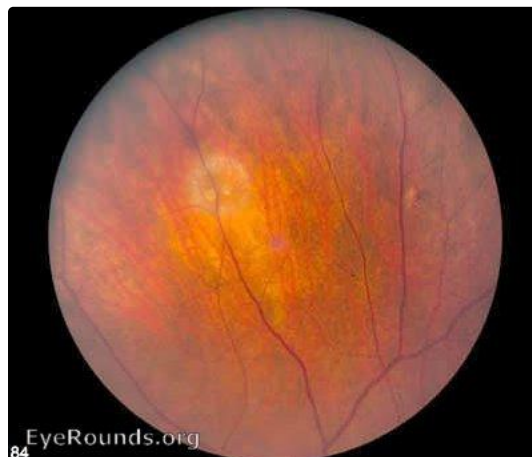Category(ies): External Eye Disease

Contributor: [Andrew Doan, MD, PhD](#)



Adenoma sebaceum: yellow-red papules in butterfly pattern on the face. Other systemic lesions: Subungual angiofibromas, ash-leaf sign, renal angiomyolipoma, cardiac rhabdomyoma, pleural cysts, cystic bone lesions, hamartomas of the liver, thyroid, pancreas, and/or testes.

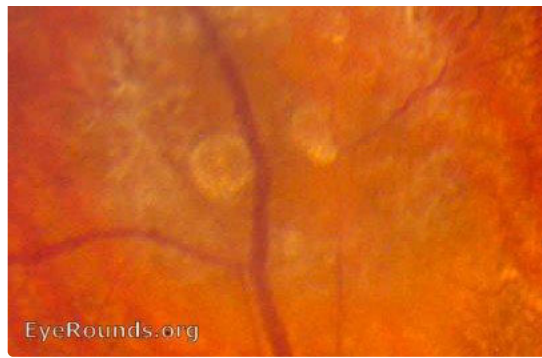
[Enlarge](#) [Download](#)



Fundus Photo Astrocytic hamartoma: white, semitransparent, mulberry-appearing tumor of retina or ON. Calcification with age. Occurs in the CNS.

[Enlarge](#) [Download](#)

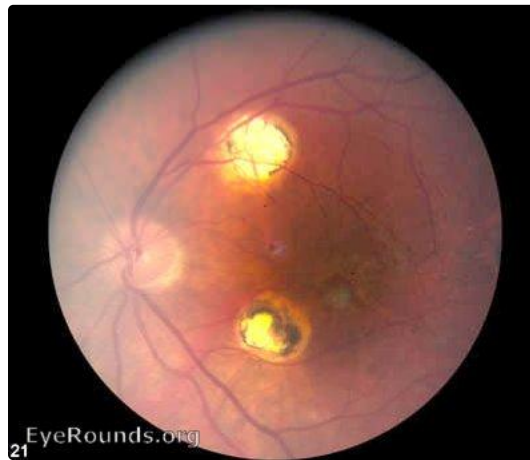



Fundus Photo Closeup Astrocytic hamartoma: white, semitransparent, mulberry-appearing tumor of retina or ON. Calcification with age. Occurs in the CNS.

[Enlarge](#)

[Download](#)



Retinal astrocytomas usually require no treatment, unless small non-calcified, parafoveal retinal astrocytic hamartomas cause macular retinal detachment. Patient had PRP laser to destroy macular lesions.

[Enlarge](#)

[Download](#)

## Image Permissions:



Ophthalmic Atlas Images by [EyeRounds.org](#), [The University of Iowa](#) are licensed under a [Creative Commons Attribution-NonCommercial-NoDerivs 3.0 Unported License](#).

## Address

University of Iowa  
Roy J. and Lucille A. Carver College  
of Medicine  
Department of Ophthalmology and  
Visual Sciences  
200 Hawkins Drive  
Iowa City, IA 52242

Support Us

## Legal

Copyright © 2019 The University of  
Iowa. All Rights Reserved  
Report an issue with this page  
Web Privacy Policy |  
Nondiscrimination Statement

## Related Links

Cataract Surgery for Greenhorns  
EyeTransillumination  
Gonioscopy.org  
Iowa Glaucoma Curriculum  
Iowa Wet Lab  
Patient Information  
Stone Rounds  
The Best Hits Bookshelf

## EyeRounds Social Media

Follow



Receive notification of new cases,  
sign up here  
Contact Us  
Submit a Suggestion

