

## Hydroxychloroquine (Plaquenil) Toxicity and Recommendations for Screening

John J. Chen, MD, PhD; Ryan M. Tarantola, MD; Christine N. Kay, MD; Vinit B. Mahajan, MD, PhD

August 30, 2011

**Chief complaint:** Whirling and flashing lights

### **History of Present Illness:**

A 57-year-old female presented to the Ophthalmology clinic at UIHC complaining bilateral central photopsias for the past two years. She suffered from Sjogren syndrome and inflammatory arthritis and was currently treated with prednisone and methotrexate. She was previously treated with hydroxychloroquine (Plaquenil) 200mg bid (6.5mg/kg) for 10 years, which was stopped one year prior to presentation.

**Past Ocular History:** None

**Past Medical History:** Sjogren syndrome and inflammatory arthritis, supraventricular tachycardia, anxiety, depression, peptic ulcer disease

**Medications:** prednisone, methotrexate, amitriptyline, ranitidine, estradiol, tizanidine, diltiazem, Restasis

**Allergies:** codeine, droperidol

**Family History:** heart disease, arthritis, cancer

**Social History:** occasional alcohol but no tobacco or intravenous drug use.

### **Review of systems:**

Blurred vision, halos, dry eye, dry mouth, gastroesophageal reflux, joint pain

### **Ocular exam:**

#### **Visual Acuity:**

- Right eye (OD): 20/30
- Left eye (OS): 20/25

**Pupils:** Reactive to light in each eye from 5 mm in the dark to 2 mm in the light. No relative afferent pupillary defect (RAPD).

**Extraocular movements:** Full, both eyes (OU)

**Confrontation visual fields:** Full OU

#### **Intra-ocular pressure:**

- OD: 15 mmHg
- OS: 15 mmHg

#### **External:**

#### **Slit Lamp Exam:**

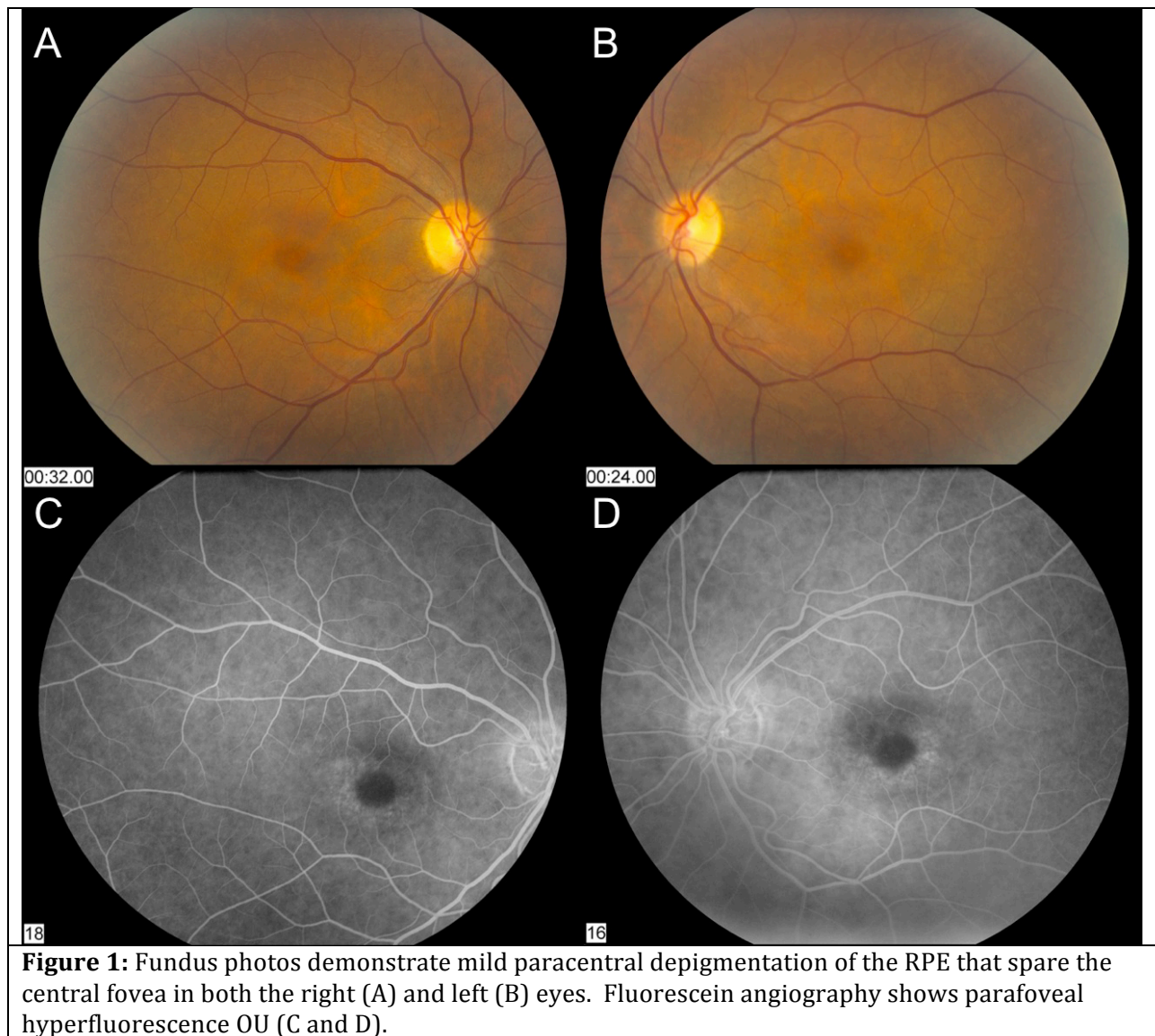
- Lid/Lashes: normal

- Conjunctiva/Sclera: normal
- Cornea: clear, no verticillata
- Anterior Chamber: deep and quiet
- Iris: normal
- Lens: 1+ NS
- Vitreous: normal

**Dilated Fundus Exam:**

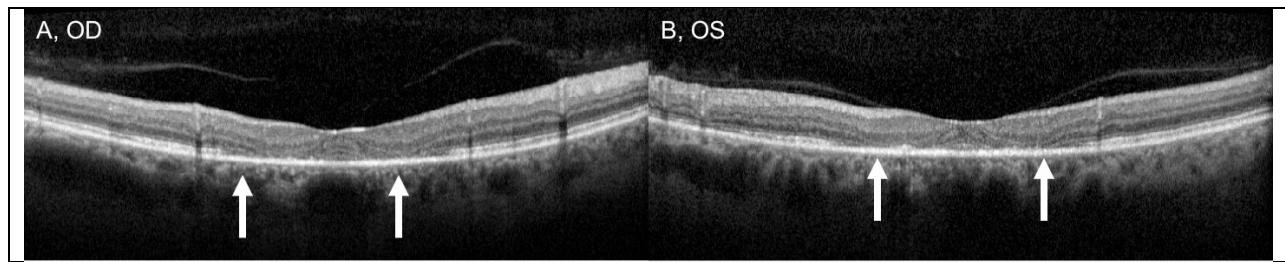
The optic nerves appeared healthy with a 0.3 cup-to-disc ratio. There was mild paracentral depigmentation of the RPE in the macula that spared the central fovea OU. The vessels and peripheral exam were normal OU (Figure 1). There was no posterior vitreous detachment, retinal tears, or retinal detachments.

**Ancillary Tests:**

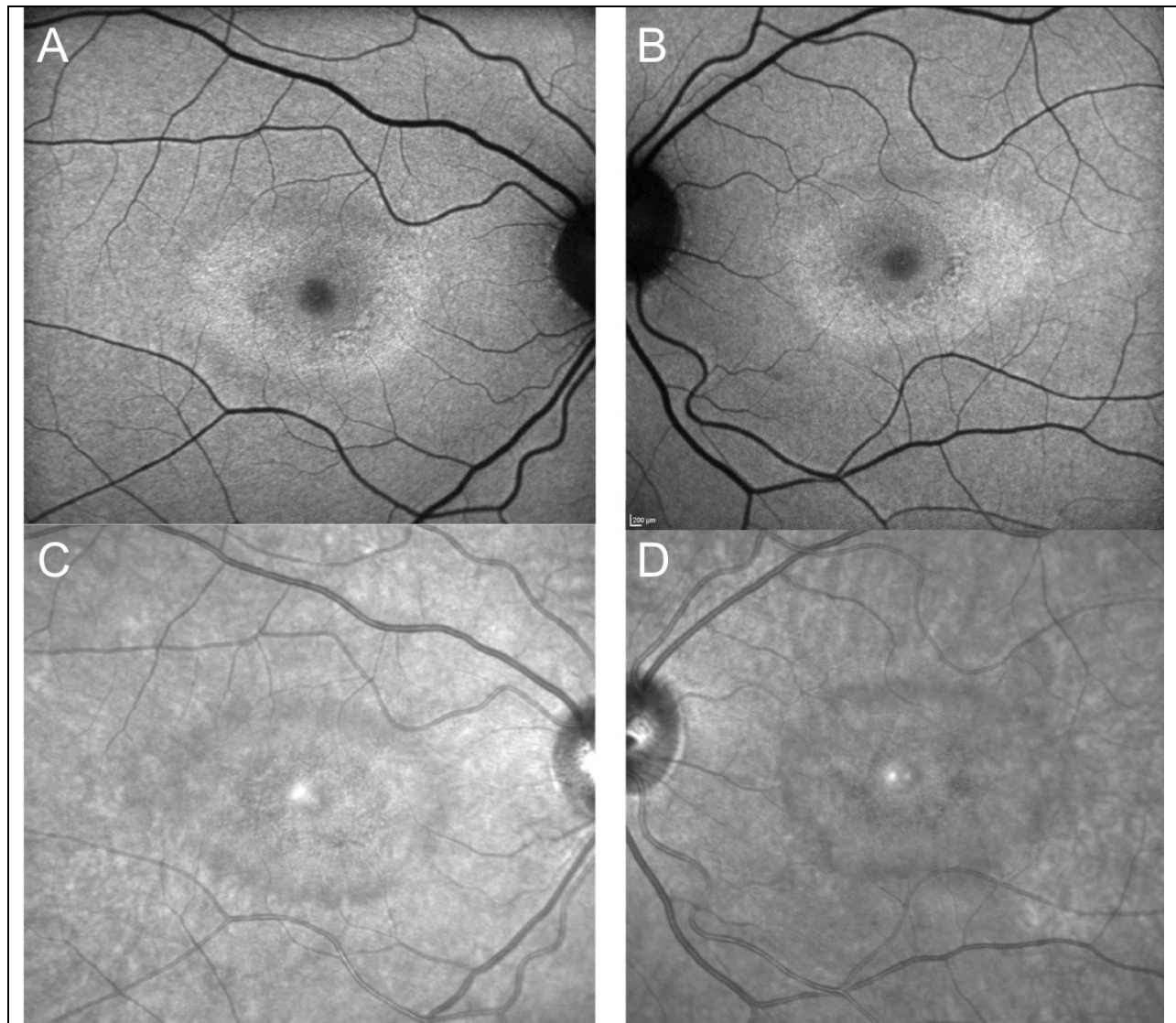


**Figure 1:** Fundus photos demonstrate mild paracentral depigmentation of the RPE that spare the central fovea in both the right (A) and left (B) eyes. Fluorescein angiography shows parafoveal hyperfluorescence OU (C and D).



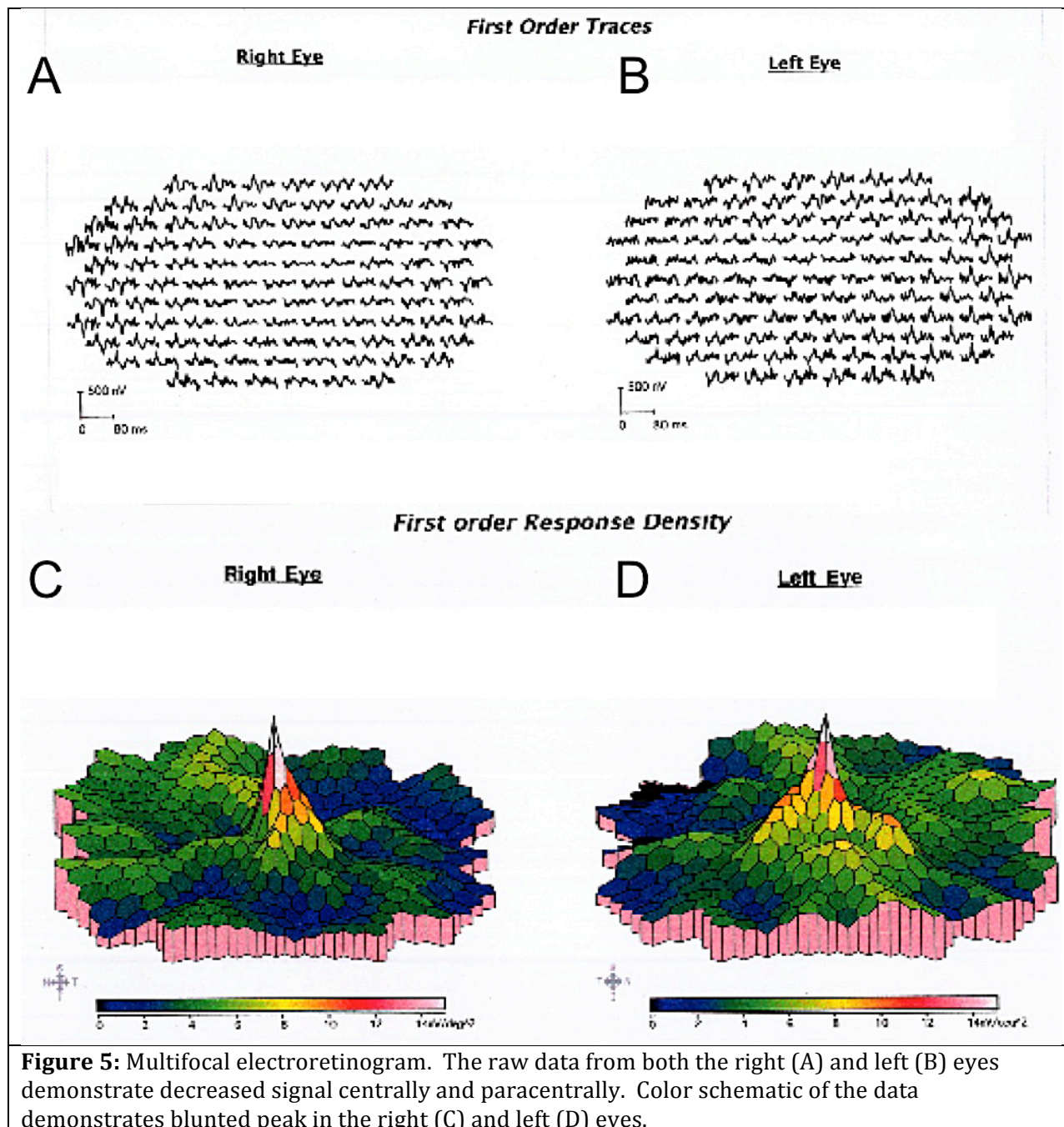


**Figure 3:** Spectral domain optical coherence tomography demonstrates loss of the IS/OS junction and thinning of the outer retina in the parafoveal region (arrows), with preservation of these structures in the fovea of both the right (A) and left (B) eyes.



**Figure 4:** Autofluorescence imaging shows an increase in signal in the parafoveal region of both the right (A) and left (B) eyes. Near-infrared autofluorescence imaging shows increased signal at the fovea OU (C and D).





**Diagnosis:** Hydroxychloroquine-induced retinal toxicity

**Discussion:**

Chloroquine and hydroxychloroquine (Plaquenil) have been used for many years, initially for the treatment of malaria and now more commonly for the treatment of inflammatory diseases, such as rheumatoid arthritis and lupus [1]. Chloroquine and hydroxychloroquine both belong to the quinolone family and share similar clinical indications and side effects, including retinal toxicity. Chloroquine-induced retinal toxicity was first described in 1959 and the retinal toxic effects of hydroxychloroquine were later described in 1967 [2, 3]. Hydroxychloroquine has significantly less

retinal toxicity, and it has largely replaced chloroquine as a treatment of inflammatory disease. Unfortunately, the retinal damage from these medications is largely irreversible, so it is critical to detect early retinal toxicity in the hopes of limiting the extent of visual loss.

Ocular manifestations of hydroxychloroquine include corneal verticillata and retinal toxicity. Verticillata are cornea deposits of salts within the corneal epithelium, which are mostly asymptomatic and reversible with cessation of the medication. The finding of corneal verticillata bares no correlation with retinal toxicity and is not an indication to stop the medication [1]. The hallmark of hydroxychloroquine toxicity is bilateral pigmentary retinopathy [1]. Early in hydroxychloroquine-induced retinal disease, patients will often be asymptomatic despite having subtle paracentral scotomas. Later in the disease, patients can develop a bull's eye maculopathy, characterized by a ring of retinal pigment epithelium (RPE) depigmentation in the macula sparing the fovea, which is often accompanied by paracentral and central scotomas [4]. End stage hydroxychloroquine toxicity leads to widespread RPE and retinal atrophy with a loss of central vision, peripheral vision, and night vision.

Although hydroxychloroquine retinal toxicity is thought to be rare, recent studies suggest it may have a higher prevalence than previously recognized. A recent study of 4000 patients found a prevalence of 6.8/1000 patients [5]. Risk factors that increase the chance of hydroxychloroquine retinopathy include daily dosage, cumulative dose, renal or liver disease, age, and previous retinal disease [6]. A daily dose of  $>6.5\text{mg/kg}$  (ideal body weight) puts patients at higher risk, but a daily dose below this level does not preclude the patient from developing toxicity after many years of treatment. A cumulative dose of  $>1000\text{g}$  of hydroxychloroquine or  $460\text{g}$  of chloroquine is likely the largest risk factor, which is typically achieved after 5-7 years of a typical dosage [5, 7]. However, there have been case reports of patients with hydroxychloroquine toxicity as early as 1.9 months of treatment [8]. Hydroxychloroquine is cleared by both the kidney and liver, and therefore any renal and hepatic impairment can increase the risk for retinal toxicity. Elderly patients ( $>60$  years old) may be at increased risk for retinal toxicity. Lastly, previous retinal and macular disease may place patients at higher risk and may mask signs of early toxicity.

Fundus changes on biomicroscopy, including bull's eye maculopathy, is indicative of fairly advanced hydroxychloroquine-induced retinal toxicity that is largely irreversible despite cessation of the offending medication. Continued deterioration in visual function can occur after discontinuing hydroxychloroquine, possibly due to slow clearance from the retina and body [6, 9]. Screening must be aimed at detecting early retinal toxicity before notable fundusoscopic changes in order to limit the amount of visual loss.

The American Academy of Ophthalmology has recently provided revised recommendations for screening that incorporates new advances in technology allowing for earlier detection of the disease [6]. These recommendations include a baseline examination when the drug is initiated, with annual screening starting after five years of use because toxicity is rare within the first five years of treatment. Earlier screening is recommended for patients with any of the previously mentioned risk factors. Hydroxychloroquine baseline and annual screening examinations include biomicroscopy, 10-2 Humphrey visual field (HVF), and further testing with either spectral domain optical coherence tomography (SD-OCT), fundus autofluorescence, or multifocal electroretinogram (mfERG). 10-2 HVF is sensitive at detecting subtle paracentral visual field defects and is recommended during all screening visits. SD-OCT, unlike time domain optical coherence tomography, has the resolution to detect localized thinning of the retina in the parafoveal region. On SD-OCT, loss of the parafoveal and perifoveal inner/outer segment junction and thinning of the outer retina, with variable loss of the normal foveal depression are characteristic of

hydroxychloroquine retinal toxicity= [10]. These changes on SD-OCT can be seen before fundoscopic abnormalities are present. Early hydroxychloroquine toxicity can also be detected on autofluorescence as an increased ring of signal within the parafoveal and perifoveal regions, which is indicative of photoreceptor dysfunction and RPE abnormalities. More advanced disease will lead to loss of autofluorescence within these regions due to photoreceptor and RPE loss, often with surrounding hyperfluorescence. [11]. Finally, mfERG allows the detection of localized paracentral ERG depression in early hydroxychloroquine retinopathy [7, 12].

Tests now suggested as inadequate for screening include biomicroscopy alone, fundus photography, time-domain optical coherence tomography, fluorescein angiography, full-field electroretinogram, Amsler grid, color vision testing, and electro-oculogram [6]. All of these tests are thought to have inadequate sensitivity to detect hydroxychloroquine toxicity at an early enough stage to prevent significant vision loss.

In summary, hydroxychloroquine-induced retinal toxicity is likely more prevalent than previously believed. Once thought to be safe at a daily dose of <6.5mg/kg/day [13], newer studies show that many years of hydroxychloroquine treatment at a “safe dose” can still lead to toxicity [6]. Retinal toxicity is irreversible and can progress after cessation of hydroxychloroquine, thus early screening is important to limit potential visual loss. Baseline screening and annual screening after five years is recommended. New testing modalities, such as SD-OCT, mfERG, and autofluorescence provide sensitive screening tools that complement the 10-2 HVF in detection of early hydroxychloroquine toxicity and limit retinal damage.

#### **Full clinical history and course:**

Our patient highlights some of the new findings in hydroxychloroquine retinal toxicity, including the importance of early screening with the appropriate tools described above, the lack of sensitivity of some of the outdated tests, and the potential for worsening despite cessation of the offending medication. When our patient initially presented with haloes and swirling light to an outside provider, she had normal visual acuity and no defects on Amsler grid, color vision testing, or on dilated fundus examination. In addition, her 24-2 HVF one-year prior demonstrated non-specific paracentral changes and was considered full. One year later, a 10-2 HVF was obtained that showed dense paracentral scotomas bilaterally (Figure 2), despite normal visual acuity, Amsler grid, and color vision testing. Upon the detection of the visual field defects, the hydroxychloroquine was stopped. Although she was taking hydroxychloroquine at or below the recommended dosage of 6.5 mg/kg/day, she had taken the medication for 10 years with a cumulative dose of 1460g, which is higher than 1000g and therefore put her at increased risk for hydroxychloroquine retinal toxicity.

Despite cessation of hydroxychloroquine, one-year follow-up revealed a mild worsening visual acuity to 20/30 OD and 20/25 OS, with new abnormalities on Amsler grid and deficits on color vision testing. Subtle parafoveal RPE depigmentation could be seen on biomicroscopy, which was highlighted by hyperfluorescence on fluorescein angiography (Figure 1). Repeat 10-2 HVF testing demonstrated the dense paracentral scotomas. SD-OCT showed loss of the parafoveal inner/outer segment junction, thinning of the parafoveal outer nuclear layer, and a loss of the normal foveal depression, which is characteristic for hydroxychloroquine retinal toxicity (Figure 3). Autofluorescence imaging showed a ring of hyperautofluorescence in the parafoveal region corresponding to photoreceptor damage and RPE dysfunction (Figure 4). mfERG demonstrated decreased signal centrally in both eyes (Figure 5). Our patient demonstrates the importance of using the new recommended screening tools for the detection of early hydroxychloroquine toxicity. 10-2 HVF, SD-OCT, autofluorescence, or mfERG might have detected the hydroxychloroquine retinal

toxicity on the day of her presenting symptoms and possibly earlier, potentially limiting the amount of visual loss.

**Differential Diagnosis** age-related macular degeneration, central areolar choroidal dystrophy, Stargardt disease, cone-rod dystrophy, benign concentric annular dystrophy.

<p><b>SYMPTOMS:</b></p> <ul style="list-style-type: none"> <li>• decreased vision</li> <li>• photopsias</li> <li>• glare</li> <li>• metamorphopsia</li> <li>• paracentral scotomas</li> <li>• decreased night vision</li> <li>• decreased color vision</li> </ul>	<p><b>SIGNS:</b></p> <ul style="list-style-type: none"> <li>• <b>Early signs:</b> visual field defects on 10-2 HVF (usually paracentral), perifoveal and parafoveal thinning of the retina with loss of the inner/outer segment junction on SD-OCT, increased or decreased signal on autofluorescence, central/paracentral ERG depression on mfERG, +/- changes on Amsler grid, +/- subtle RPE changes, +/- decreased color vision</li> <li>• <b>Late signs:</b> decreased visual acuity, bull's eye maculopathy, paracentral hyperfluorescence on fluorescein angiography, thinning of the paracentral outer retina on time-domain OCT, 24-2 HVF paracentral VF defects, decreased signal on full-field ERG.</li> <li>• <b>Risk factors:</b> daily dosage &gt;6.5mg/kg (ideal body weight), cumulative dose &gt; 1000g for hydroxychloroquine and &gt;460g for chloroquine, renal or liver disease, age &gt;60 yo, underlying retinal disease or maculopathy</li> </ul>
<p><b>TREATMENT:</b></p> <ul style="list-style-type: none"> <li>• No treatment to reverse hydroxychloroquine toxicity.</li> <li>• Recommend cessation of the medication, but visual function rarely recovers, especially in the later stages of the disease. Continued deterioration in visual function can occur for a year after discontinuing hydroxychloroquine, possibly due to slow clearance of the medication from the retina and body.</li> </ul>	<p><b>RECOMMENDED SCREENING:</b></p> <ul style="list-style-type: none"> <li>• Baseline screening and then annual screening after five years</li> <li>• Biomicroscopy, 10-2 HVF, plus one of the following: <ul style="list-style-type: none"> <li>○ SD-OCT</li> <li>○ auto-fluorescence</li> <li>○ mfERG.</li> </ul> </li> <li>• Early annual screening for patients that have risk factors for developing hydroxychloroquine toxicity.</li> </ul>



## References:

1. Tehrani R, Ostrowski RA, Hariman R, Jay WM: Ocular toxicity of hydroxychloroquine. *Semin Ophthalmol* 2008, 23(3):201-209.
2. Hobbs HE, Sorsby A, Freedman A: Retinopathy following chloroquine therapy. *Lancet* 1959, 2(7101):478-480.
3. Shearer RV, Dubois EL: Ocular changes induced by long-term hydroxychloroquine (plaquenil) therapy. *Am J Ophthalmol* 1967, 64(2):245-252.
4. Gass JDM: Stereoscopic atlas of macular diseases : diagnosis and treatment, 4th edn. St. Louis: Mosby; 1997.
5. Wolfe F, Marmor MF: Rates and predictors of hydroxychloroquine retinal toxicity in patients with rheumatoid arthritis and systemic lupus erythematosus. *Arthritis Care Res (Hoboken)* 2010, 62(6):775-784.
6. Marmor MF, Kellner U, Lai TY, Lyons JS, Mieler WF: Revised recommendations on screening for chloroquine and hydroxychloroquine retinopathy. *Ophthalmology* 2011, 118(2):415-422.
7. Lyons JS, Severns ML: Detection of early hydroxychloroquine retinal toxicity enhanced by ring ratio analysis of multifocal electroretinography. *Am J Ophthalmol* 2007, 143(5):801-809.
8. Yam JC, Kwok AK: Ocular toxicity of hydroxychloroquine. *Hong Kong Med J* 2006, 12(4):294-304.
9. Michaelides M, Stover NB, Francis PJ, Weleber RG: Retinal toxicity associated with hydroxychloroquine and chloroquine: risk factors, screening, and progression despite cessation of therapy. *Arch Ophthalmol* 2011, 129(1):30-39.
10. Chen E, Brown DM, Benz MS, Fish RH, Wong TP, Kim RY, Major JC: Spectral domain optical coherence tomography as an effective screening test for hydroxychloroquine retinopathy (the "flying saucer" sign). *Clin Ophthalmol* 2010, 4:1151-1158.
11. Kellner U, Renner AB, Tillack H: Fundus autofluorescence and mfERG for early detection of retinal alterations in patients using chloroquine/hydroxychloroquine. *Invest Ophthalmol Vis Sci* 2006, 47(8):3531-3538.
12. Lai TY, Chan WM, Li H, Lai RY, Lam DS: Multifocal electroretinographic changes in patients receiving hydroxychloroquine therapy. *Am J Ophthalmol* 2005, 140(5):794-807.
13. Bernstein HN: Ocular safety of hydroxychloroquine. *Ann Ophthalmol* 1991, 23(8):292-296.

**Suggested citation format:** Chen JJ, Tarantola, RM, Kay CN, Mahajan VB. Hydroxychloroquine (Plaquenil) Toxicity and Recommendations for Screening. EyeRounds.org. August 30, 2011. Available from: <http://EyeRounds.org/cases/139-plaquenil-toxicity.htm>.