

Retinopathy of Prematurity

Anthony P. Mai, BS; [Brittini A. Scruggs, MD, PhD](#); [Pavlina S. Kemp, MD](#)

Posted June 24, 2019



INITIAL PRESENTATION

Chief Complaint

Prematurity and low birth weight

History of Present Illness

A 770-gram male infant was born at 25 weeks gestational age and was admitted to the neonatal intensive care unit (NICU). His hospital course was complicated by bronchopulmonary dysplasia, patent ductus arteriosus, feeding difficulties, and apnea. Due to his prematurity and low birth weight, pediatric ophthalmology was consulted when the infant's post-conceptual age was 31 weeks to screen for retinopathy of prematurity (ROP).

Past Ocular History

- No history of trauma or ocular surgery
- Artificial tears started in the NICU
- The patient had no other ocular history and was on oxygen supplementation at initial presentation

Medications

- Acetaminophen
- Beclomethasone
- Dexamethasone
- Theophylline
- Glycerin
- Potassium chloride
- Sodium citrate-citric acid
- Tetracaine
- Bifidobacterial
- Lactobacillus

Past Medical History

- Anemia
- Apnea
- Bronchopulmonary dysplasia
- Feeding difficulties
- Patent ductus arteriosus
- Prematurity
- Right inguinal hernia

Allergies

None

Family History

Non-contributory

Social History

Non-contributory

Review of Systems

As provided in the history of present illness

OCULAR EXAMINATION

Visual Acuity

Winces to light in each eye

Visual Fields

Unable to assess due to patient's age

Ocular Motility

Fully horizontal to doll's head maneuver

Intraocular Pressure

Soft to palpation in both eyes (OU)

Penlight Examination (OU)

- Adnexa/lids: Normal for age
- Conjunctiva: Normal for age
- Cornea: Clear
- Anterior Chamber: Formed
- Iris/pupils: No rubeosis, pharmacologically dilated
- Lens: Clear

Dilated Fundus Examination

- Disc: Normal for age
- Vessels: Vascularized in zone I-II OU, no plus disease

Oxygen Supplementation

Jet ventilator, pressures 23/7, rate 360 breaths per minute with fraction of inspired O₂ (FiO₂) 0.23-0.27, 97% O₂ saturation

RETINOPATHY OF PREMATURITY COURSE

According to protocol, the patient's first retinal exams performed at a post-conceptual age of 31 weeks and 1 day. At the first screen, the patient's ROP status was Zone I-II, Stage 0; therefore, the patient was seen two weeks later. The progression of the patient's ROP over the following five months is displayed in Table 1, below. The worst ROP status was at 46 weeks post-conceptual age, at zone II, stage three, pre-plus disease in right eye (OD, Figure 1) and zone II, stage 3, plus disease in the left eye (OS, Figures 1 and 2). At this time, the decision was made to treat the avascular retina with ROP laser indirect ophthalmoscopy (LIO) photocoagulation in both eyes (OU), leading to regression over the next 2-3 months. There were no incidences of retinal detachment. He was discharged home with a nasal cannula providing 1.5 liters per minute (LPM) oxygen at a FiO₂ of 1.0, which was gradually stopped at 10 months of age. He continued to follow-up with the pediatric ophthalmology team. His parents noted that he did not have crossing or drifting, and was able to look at the television 15 feet away. He has been growing and developing well since then.

Post-conceptual age (weeks)	Right Eye				Left Eye			
	Zone I-II	Stage	plus	Notes	Zone I-II	Stage	plus	Notes
31	Zone I-II	Stage 0	no plus	immature	Zone I-II	Stage 0	no plus	immature
33 - 36	Zone II	Stage 1	no plus		Zone II	Stage 1	no plus	
37	Zone II	Stage 2	pre-plus		Zone II	Stage 2	no plus	
38 - 40	Zone II	Stage 2	no plus		Zone II	Stage 2	no plus	
41	Zone II	Stage 3	pre-plus		Zone II	Stage 2	pre-plus	
42	Zone II	Stage 3	no plus		Zone II	Stage 2	pre-plus	
43	Zone II	Stage 3	pre-plus		Zone II	Stage 2	no plus	
44 - 45	Zone II	Stage 2	no plus		Zone II	Stage 2	no plus	
46, laser OU	Zone II	Stage 2-3	pre-plus		Zone II	Stage 3	+ plus	
47	Zone II	Stage 2	pre-plus		Zone II	Stage 3	+ plus	
48	Zone II	Stage 2	pre-plus		Zone II	Stage 1	no plus	
49	Zone II	Stage 1	no plus	regressing	Zone II	Stage 1	no plus	regressing
50	Zone II		no plus		Zone II		no plus	
52	Zone II	Stage 1	no plus			Stage 0	no plus	regressed, vascularized to laser
56		Stage 0	no plus	regressed, vascularized to laser		Stage 0	no plus	regressed, vascularized to laser

Table 1. Clinical course of premature infant showing the location, stage, and severity of ROP over time. The patient underwent LIO photocoagulation OU at post-conceptual age 46 weeks, at which time there was stage 3 ROP in zone II OU with bilateral dilatation and tortuosity of the posterior pole vessels, consistent with pre-plus OD and plus disease OS.

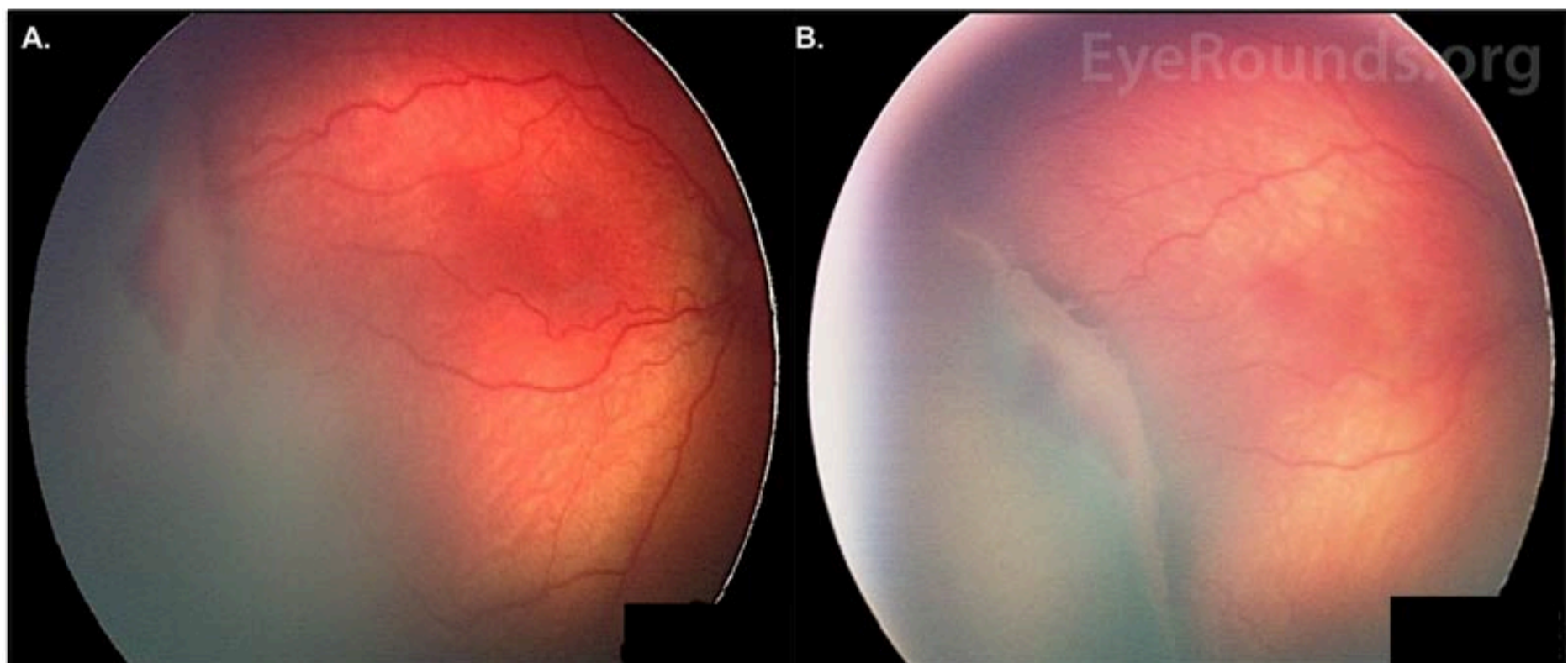


Figure 1: ROP with pre-plus disease, OD. Fundus photos of the patient taken at 46 weeks post-conceptual age. **A.** Stage 3 ROP is present temporally OD. A thick ridge separates the posterior vascularized retina from the avascular anterior. There is a section of hemorrhage immediately anterior to the ridge. **B.** A wider view of the ridge, offering a better depiction of its raised dimensions. There is fibrovascular proliferation on the posterior edge.

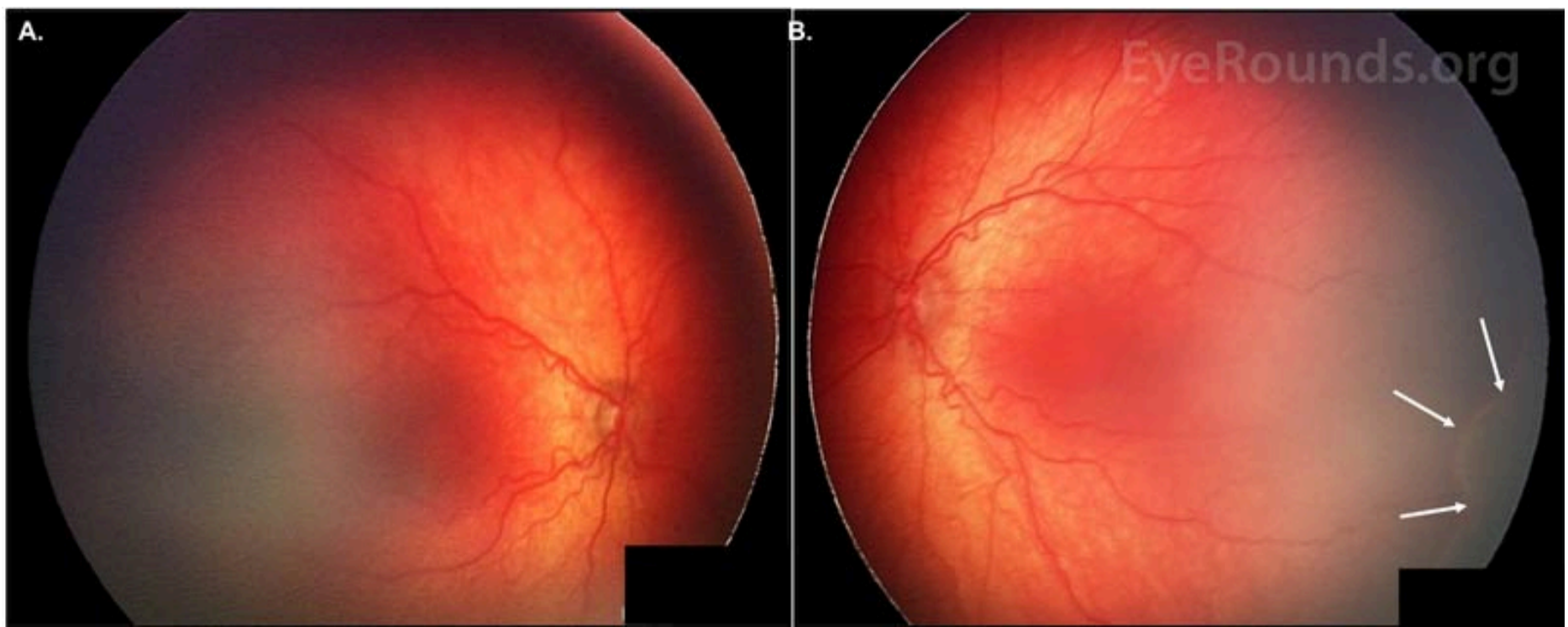


Figure 2: ROP with dilated veins and tortuous arteries in the posterior pole, OU. Fundus photos of the patient, taken at 46 weeks post-conceptual age. **A.** Pre-plus disease is present OD. **B.** Plus disease is present OS. A ridge can be seen inferotemporally (white arrows).

Differential Diagnosis [1]

- Retinopathy of prematurity
- [Familial exudative vitreoretinopathy](#) (FEVR)
- [Persistent fetal vasculature](#)
- [Retinoblastoma](#)
- [Norrie Disease](#)

DIAGNOSIS

Retinopathy of prematurity (ROP)

DISCUSSION

History and Epidemiology

ROP is the leading cause of childhood blindness worldwide. For industrialized countries, the first ROP epidemic occurred in the 1940s and 1950s. The primary risk factor for ROP in the USA and Western Europe was excessive oxygen supplementation. As a result, oxygen supplementation was harshly curtailed in the late 1950s and 1960s, leading to a decreased incidence of ROP, yet an increase in premature infant morbidity and mortality rates. The second ROP epidemic in industrialized countries began in the 1970s because of higher survival rates of extremely premature infants. The 1980s and early 1990s saw progress in ROP complication reduction and the development of new therapeutic options. The third ROP epidemic started in the early 2000s, mainly in Latin America and in Eastern Europe. These developing countries with moderate infant mortality rates (IMR) – rather than high or low IMRs – currently appear to have the highest incidence of ROP. The contributing factors in these middle-income countries include high preterm birth rates, high proportion of NICU admissions despite ongoing barriers (e.g., inadequate equipment and training, personnel shortages), and inconsistent screening and/or treatment [1, 2].

ROP continues to be a vision-threatening global issue over the past decade. In 2008, at least 50,000 children were blinded by ROP [2]. By 2010, approximately 16% of surviving infants born under 32 gestational weeks had some degree of ROP, with 3% having associated visual impairment [3]. That same meta-analysis population study revealed that 184,700 preterm babies worldwide developed ROP, of whom 20,000 became blind or severely visually impaired and 12,300 developed mild/moderate visual impairment [3]. Sixty percent of these ROP cases were thought to occur predominantly in middle-income regions of Latin America, East Asia/Pacific, and North Africa/Middle East. The Global Burden of Disease study corroborated these findings by estimating that 257,000 years lived with disability worldwide in 2010 were associated with visual impairment secondary to ROP [4]. The ROP incidence in the United States was found to have increased from 15% to 20% between 2000 and 2012, likely related to the national decline in newborn mortality rate [3, 5] at an increasingly younger gestational age. Although industrialized countries may have adopted rigorous screening and treatment guidelines that have reduced their incidences of ROP, it is probable that the worldwide incidence will increase due to increasing NICU services and infant survival rates.

Etiology and Risk Factors

Low gestational age and low birth weight are the two strongest risk factors for the development of ROP [1, 6, 7]. Both factors are associated with the extent of retinal vascular immaturity at birth and, therefore, the vulnerability to insult. The lower the birth weight and gestational age, the higher the exposure to postnatal stresses and the longer the absence of protective maternal factors [8]. This relationship has also been shown in the landmark multicenter trial, Cryotherapy for Retinopathy of Prematurity (CRYO-ROP),

which includes several studies performed throughout the 1990s [9, 10]. The CRYO-ROP study found that 65.8% of infants born below 1251 grams developed some form of ROP. This increased to 90% for those born below 750 grams [10]. Despite the debate on which factor is stronger than the other, the overall literature agrees that gestational age and birthweight are both closely related to the development of ROP.

Oxygen supplementation has also been recognized as a risk factor after its excessive use in the first ROP epidemic; however, defining the association in terms of duration and concentration of oxygen supplementation is elusive [1, 6]. Certain past studies have failed to find an association, while others have confirmed a significant association or have even shown ROP development without O₂ supplementation in infants with cyanotic heart disease and anencephaly [11-14]. A study in 2001 suggested that oxygen supplementation targeting the 83-90% O₂ saturation range significantly reduced ROP incidence [15]. A meta-analysis in 2017 reported that targeting O₂ saturation levels below 90% decreased the incidence of ROP requiring treatment but increased the risk of death and necrotizing enterocolitis, concluding that the benefits and harms of oxygen saturation target ranges must be weighed within the local setting [16]. A 2017 study by Colaizy, et al. showed that ROP progression and active proliferation were significantly decreased after implementation of an oxygen therapy protocol [17]. Overall, these studies suggest that oxygen supplementation has a role in both ROP development and treatment. The exact management, however, continues to be unclear and remains up for debate.

Numerous other risk factors have been proposed. Some of these include low insulin-like growth factor-1 (IGF-1) levels, poor postnatal weight gain, hyperglycemia, apnea, severe illness (e.g., sepsis), blood transfusions, xanthine administration, indomethacin usage, intraventricular hemorrhage, respiratory distress syndrome, and maternal factors like poor nutrition, limited prenatal care, and bleeding [6, 8, 18-22]. Several recent meta-analyses found a protective effect of human milk on development of ROP [22]. The CRYO-ROP study also cited white race and multiple births as risk factors [23]. The proposal that hospital-associated ambient light may be a risk factor [24] was debunked by the multi-center Light Reduction in Retinopathy of Prematurity (Light-ROP) trial [25]. The risk of developing ROP was decreased in African Americans, mothers with pre-eclampsia, and infants with betamethasone administration or vitamin E therapy [1, 6].

Pathophysiology

Retinal vascular development begins at 16 weeks gestation with mesenchyme growing from the disc and reaching the ora nasally at 36 weeks gestation and temporally soon after full term birth at 40 weeks gestation. A primitive and immature capillary network lies on the posterior edge of the advancing mesenchyme. This capillary network undergoes absorption and remodeling to form mature retinal arteries and veins. The physiologic level of vascular endothelial growth factor (VEGF), necessary for normal retinal vascular development, is inversely proportional to the oxygen content.

In phase 1 of the development of ROP, hyperoxia, postnatal stressors, and lack of protective *in utero* factors contribute to the arrest of retinal vascular development. Because the partial pressure of oxygen (PaO₂) of a fetus ranges between 22 to 24 mmHg *in utero* (made possible due to placental oxygen exchange), the post-natal atmospheric and ventilatory oxygen content necessary for oxygenation of the immature infant lungs may cause hyperoxia. This high oxygen content then halts retinal vessel growth by decreasing VEGF production. Prolonged hyperoxia leads to vasoconstriction and ends with vaso-obliteration, resulting in an anterior avascular zone of retina (Figure 1). This avascular retina becomes progressively ischemic over the following weeks.

The transition between phase 1 and 2 generally depends on the infant's post-menstrual age rather than the post-natal age, roughly starting at 30 weeks post-menstrual age. This may suggest an association between the programmed timing of development and the disease pathogenesis. In phase 2, the increasingly metabolically active but poorly vascularized retina begins secreting VEGF and erythropoietin. Small avascular regions produce VEGF levels close to physiologic amounts such that normal vessel growth may resume. If the region is large, however, excessive VEGF production leads to arteriovenous (AV) shunts at the border between the vascularized posterior and avascular anterior retina. Regression may occur if normal vessels can grow past the AV shunts while progression begins when nodules of endothelial proliferation arise next to the AV shunts, perforating through the internal limiting membrane to proliferate on the inner retinal surface. This neovascularization can lead to fibrovascular proliferation, scarring, tractional membranes, and retinal detachment. The high VEGF levels may also cause tortuosity and dilation of exiting posterior pole vessels, typically known as plus disease (Figure 2) [1, 8, 26].

Classification

ROP is classified according to the guidelines described by the International Classification of Retinopathy of Prematurity (ICROP) in 1984, 1987, and 2005 [27-29]. Three main parameters were considered: location, extent, and severity. The following ICROP guidelines are summarized from the 2014-2015 Basic and Clinic Science Course: Pediatric Ophthalmology and Strabismus [6], the Handbook of Pediatric Retinal Disease [1], and the 2005 ICROP guideline updates [27-29].

Location and Extent

Zone I	Small circle in the posterior pole centered on the optic nerve with a radius that is twice the distance from the macula to the optic disc
Zone II	Extends from zone I to a tangential point on the nasal ora serrata and to the temporal equator
Zone III	Residual crescent anterior to zone II

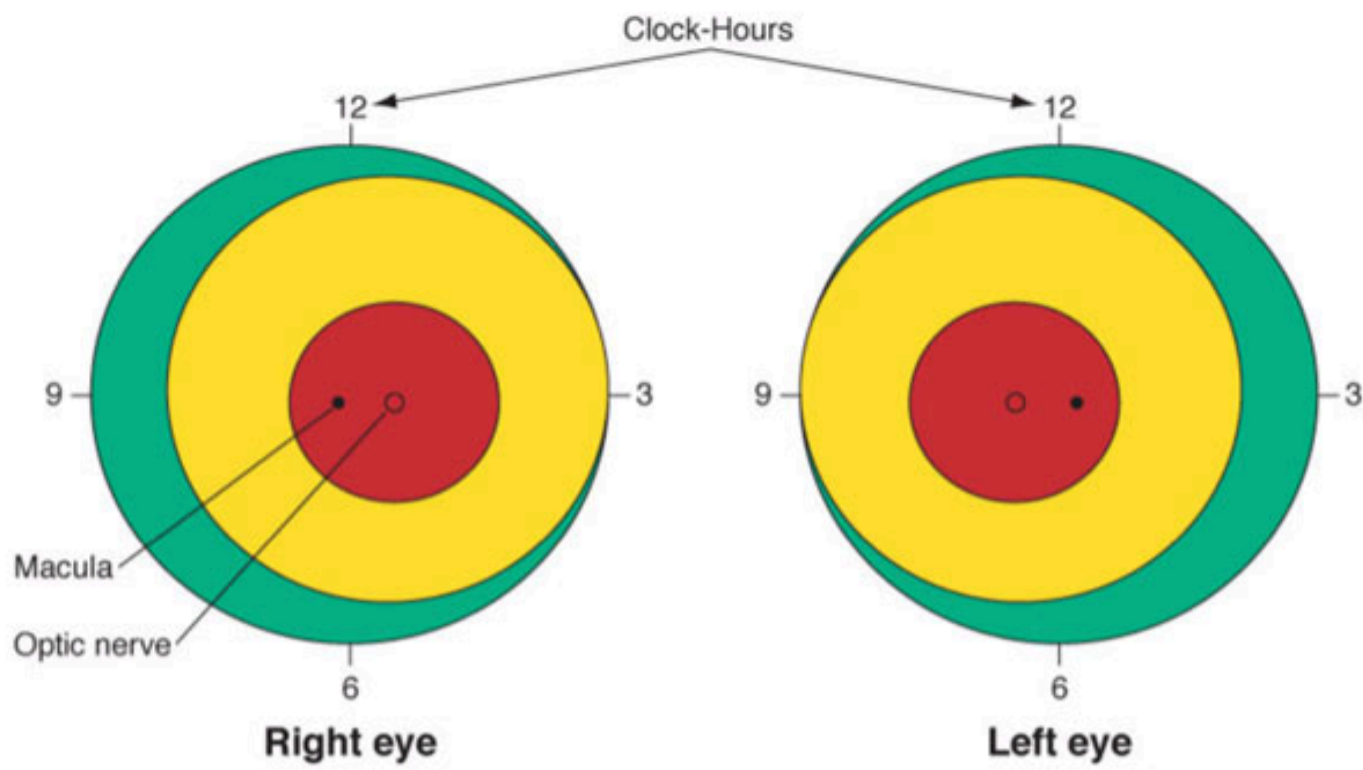
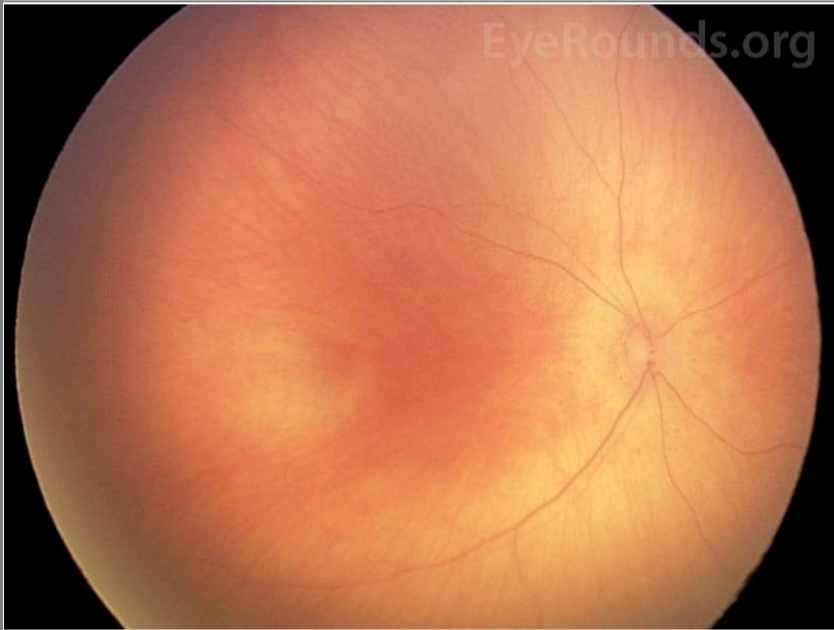

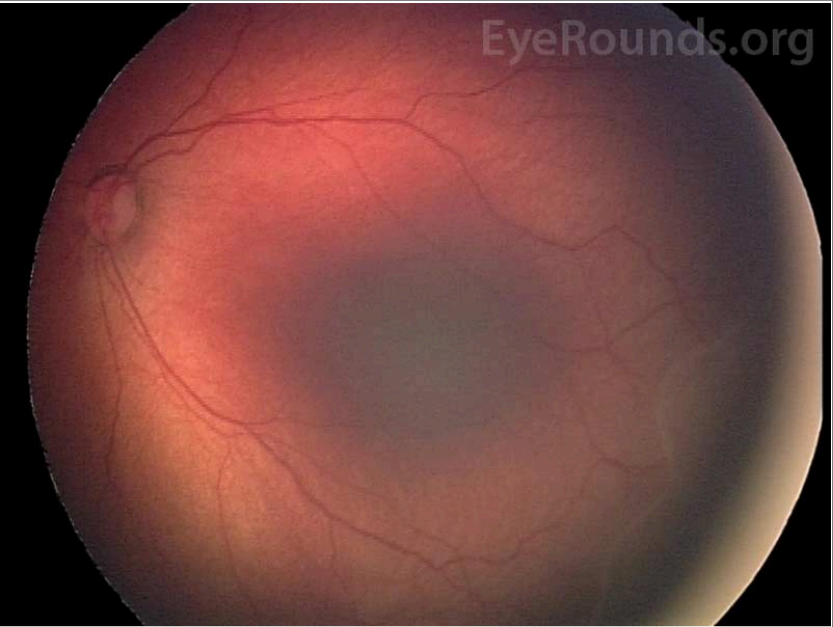
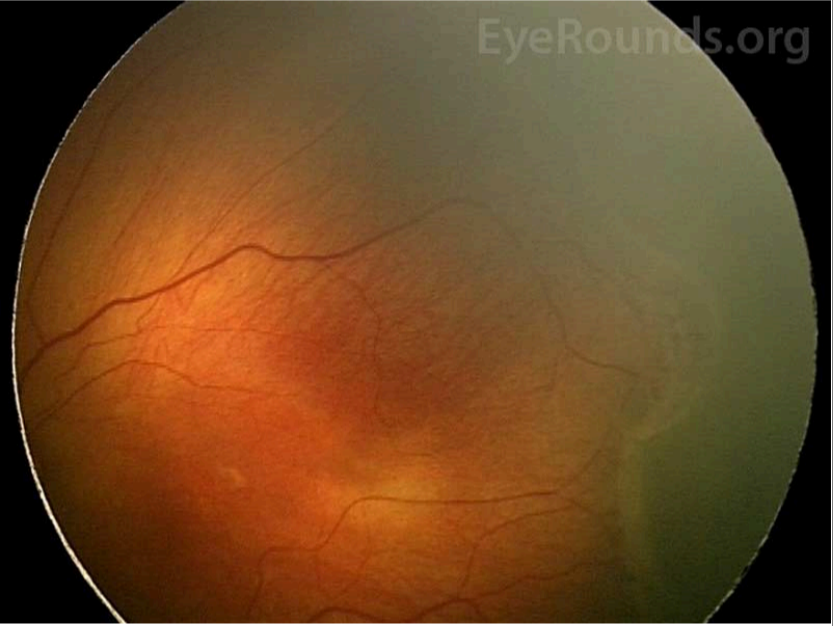
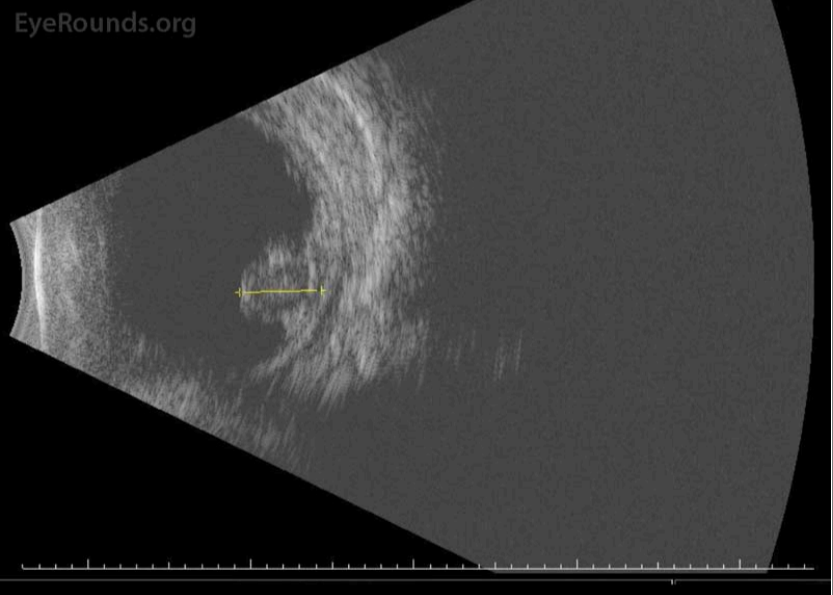


Figure 3: Depiction of zone I (red), zone II (yellow), and zone III (green), as well as clock-hours that describe extent of disease in ROP [6]. This figure is used with permission from the 2014-2015 Basic and Clinic Science Course: Pediatric Ophthalmology and Strabismus.

Staging	Description and Pathology	Imaging Examples
Stage 0	<p>Definition: Immature vessels without ROP</p>	 <p>Fundus photo of stage 0 shows immature vascularization.</p>
Stage 1	<p>Definition: Thin white demarcation line between vascular and avascular retina</p> <p>Pathology: Spindle-shaped cells, which are the precursors of vascular endothelium, compose the anterior part of the line. Differentiated endothelial cells of mesenchymal origin form a capillary meshwork making the posterior aspect of the line [1].</p>	 <p>Fundus photo of stage 1 shows thin demarcation line (white arrows) that lacks dimensions and separates vascular retina from the avascular anterior.</p>

<p>Stage 2</p>	<p>Definition: Ridge +/- posterior fibrovascular tufts</p> <p>Pathology: The demarcation line develops dimension due to both spindle-cell (anterior ridge) and endothelial cell (posterior ridge) proliferation [1].</p>	 <p>Fundus photo of stage 2 reveals a thickened ridge with dimension. There is vascular arcading of the retinal vessels immediately posterior to the ridge.</p>
<p>Stage 3</p>	<p>Definition: Ridge with extraretinal fibrovascular proliferation</p> <ul style="list-style-type: none"> • Mild fibrovascular proliferation • Moderate fibrovascular proliferation • Severe fibrovascular proliferation <p>Pathology: The ridge develops extraretinal fibrovascular proliferation that extends into the vitreous and appears velvety, frayed, or ragged. The placoid form is the most common compared to pedunculated and polypoid. It has a circumferential orientation. The infiltrating neovascularization is derived from proliferating endothelial cells. The vitreous humor also undergoes synchysis and condensation caused by lytic substances and depolymerization, respectively. The overall stage is determined by the individual clock hour with the worse stage [1].</p>	 <p>Fundus photo of stage 3 depicts a ridge with fibrovascular proliferation.</p>
<p>Stage 4</p>	<p>Definition: Sub-total retinal detachment</p> <ul style="list-style-type: none"> • Stage 4A: Extrafoveal involvement • Stage 4B: Foveal involvement <p>Pathology: Vitreous condensation creates traction that pulls the retina anteriorly and makes folds at the ridge. This creates a subtotal, concave, and tractional retinal detachment. Nasal retina is often pulled temporally due to predominant radial forces in the temporal region [1].</p>	 <p>B-scan of a retinal detachment in stage 4 ROP.</p>

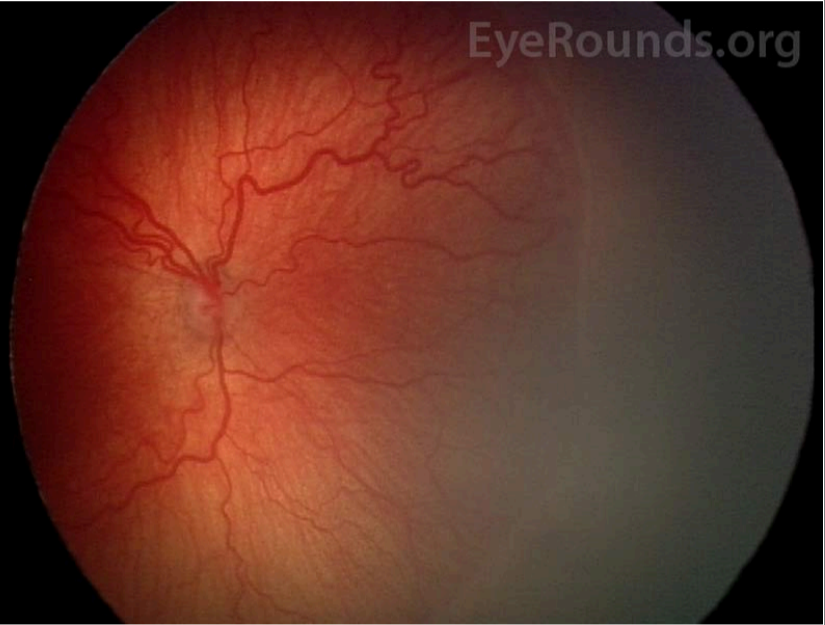
Stage 5	<p>Definition: Total retinal detachment</p> <p>Sub-divided based on anterior and posterior funnel configuration:</p> <ul style="list-style-type: none"> • Anterior-posterior: open-open (most common) • Anterior-posterior: open-closed • Anterior-posterior: closed-open • Anterior-posterior: closed-closed <p>Pathology: The retina continues to be pulled forward, creating a funnel-shaped total detachment. The anterior and posterior parts of the funnel may be open or closed, as described above. Extraretinal proliferation of nonvascular tissue is common at this stage [1].</p>	<p>Fundus photo of a stage 5 retinal detachment with open anterior and open posterior funnel regions. Used with permission from the International Classification of Retinopathy of Prematurity Revisited, 2005 [29].</p> <p>Fundus photo of a stage 5 retinal detachment with open anterior and closed posterior funnel regions. Used with permission from the International Classification of Retinopathy of Prematurity Revisited, 2005 [29].</p>
Plus Disease	<p>Definition: Dilated veins and tortuous arteries in posterior pole</p> <ul style="list-style-type: none"> • Pre-plus disease: vascular abnormalities that are insufficient for diagnosis of plus disease • Plus disease: At least two quadrants of dilation and tortuosity of posterior pole vessels [30] <p>Pathology: Increased angiogenic factors facilitate shunting effects that cause venous dilatation and arteriolar tortuosity of the posterior retinal vessels. This may worsen to include poor pupillary dilation, iris vascular engorgement, and vitreous haze [29].</p>	 <p>Fundus photo of plus disease showing tortuous arteries and dilated veins.</p>
Aggressive Posterior (AP) ROP	<p>Definition: Ill-defined and rapidly progressive ROP predominantly in the posterior region with marked plus disease</p> <p>Pathology: AP-ROP is most commonly located in zone I. The posterior pole vessels become rapidly dilated and tortuous out of proportion to the peripheral retinopathy. Shunting occurs not only at the junction between vascularized and avascular retina but also within the retina. Hemorrhages may also be present at this junction [29].</p> <p><i>*Previously known as Rush Disease</i></p>	<p>Fundus photo of aggressive posterior ROP showing disease in the posterior location, prominence of plus disease, and proliferative retinopathy (arrows). Used with permission from the International Classification of Retinopathy of Prematurity Revisited, 2005 [29].</p>

Table 2. Staging of ROP.

Threshold and type

The CRYO-ROP study defined threshold ROP as five or more contiguous or eight total clock-hours of stage three in zone I or II in the presence of plus disease [31], the level at which there was a 50% reduction in adverse visual outcomes when there was intervention with laser. In an effort to further reduce vision loss, prethreshold ROP was defined as zone I with less than threshold ROP; stage 2+, stage 3, or stage 3+ with less than required clock-hours of involvement in zone II [1, 30].

The Multicenter Study of Early Treatment for Retinopathy of Prematurity (ET-ROP) trial further classified ROP into type 1 and type 2 to guide the treatment of infants before the development of threshold ROP [32]. Type 1 was defined as any stage with plus disease in zone I, stage 3 without plus in zone I, and stage 2+ or 3+ in zone II, indicating the need for treatment within 48-72 hours. Type 2 was defined as stage 1 or 2 without plus in zone I and stage 3 without plus in zone II (Table 3) [32], indicating close observation with 1 week or sooner follow-up.

Threshold ROP	Prethreshold Type 1 ROP	Prethreshold Type 2 ROP
---------------	-------------------------	-------------------------

Zones I or II	Zone I	Zone I
<ul style="list-style-type: none"> • Stage 3 across 5 contiguous clock-hours with plus • Stage 3 in total of 8 clock-hours with plus 	<ul style="list-style-type: none"> • Any stage with plus • Stage 3 without plus 	<ul style="list-style-type: none"> • Stage 1 or 2 without plus
	Zone II	Zone II
	<ul style="list-style-type: none"> • Stage 2 or 3 with plus 	<ul style="list-style-type: none"> • Stage 3 without plus

Table 3. Threshold and Prethreshold Classification of ROP as defined by the CRYO-ROP (31) and ET-ROP Studies (32).

Practically, the terminology of Threshold disease is no longer commonly used. The treatment of ROP is indicated in any eye with type 1 ROP32, defined as any eye with:

- Zone I, any stage ROP with plus disease
- Zone I, stage 3 ROP with or without plus disease
- Zone II, stage 2 or 3 ROP with plus disease

Screening and Guidelines

ROP screening guidelines were recommended by a joint statement from the American Academy of Pediatrics, the American Association for Pediatric Ophthalmology and Strabismus, and the American Academy of Ophthalmology in the "Screening examination of premature infants for retinopathy of prematurity" article published in 2001 [33]. The guidelines were then updated by the American Academy of Pediatrics in 2013 [34] and again in 2018 [35]; these guidelines are summarized below.

1. Screen infants born at ≤ 1500 grams or gestational age of ≤ 30 weeks and selected infants with a birth weight between 1500 and 2000 grams or gestational age of >30 weeks with an unstable clinical course (e.g., cardiorespiratory support or high ROP risk determined by attending provider). Screening should be performed after pupillary dilation with binocular indirect ophthalmoscopy, lid speculum, and scleral depressor as needed. Pretreatment with a topical anesthetic agent such as proparacaine is recommended to minimize discomfort. The care team should use sterile instruments and take care not to over administer dilating eye drops.
2. The retinal examinations should be performed by an ophthalmologist with sufficient knowledge and experience regarding ROP screening. The International Classification of Retinopathy of Prematurity Revisited (29) should be used to classify, diagram, and record these retinal findings at the time of examination.
3. The following table, based on analysis of the CRYO-ROP and Light-ROP trials, proposes a screening schedule with 99% confidence of detecting potentially damaging ROP. Initial screening should be performed at 31 weeks post-menstrual age in infants at or under 26 6/7 weeks at birth, and screenings should be performed at four weeks chronological age in infants with gestational ages of 27 weeks or more. Children born before 25 weeks should be considered for screening earlier than a postmenstrual age of 31 weeks based on severity of comorbidities.

Gestational Age at birth (Weeks)	Age at Initial Examination	
	Post-Menstrual Age (Weeks)	Chronologic (Weeks)
22	31	9
23	31	8
24	31	7
25	31	6
26	31	5
27	31	4
28	32	4
29	33	4
30	34	4
>30 with high risk factors		4

Table 4. Proposed ROP screening schedule adapted from updated 2018 guidelines (35).

4. The examining ophthalmologist will recommend a follow-up schedule based on the ROP classification [35]:

Follow-up Time	Classification
1 week or less	<ul style="list-style-type: none"> ◦ Zone I, any stage ◦ Zone II, stage 3 ◦ Immature retina in zone II near zone I border ◦ Suspected or confirmed aggressive posterior ROP
1 to 2 weeks	<ul style="list-style-type: none"> ◦ Zone II, stage 2 ◦ Immature vascularization in posterior zone II, regressing ROP in zone I

2 weeks	<ul style="list-style-type: none"> ◦ Zone II, stage 1 ◦ Immature vascularization in zone II ◦ Unequivocally regressing ROP in zone II
2 to 3 weeks	<ul style="list-style-type: none"> ◦ Zone III, stage 1 or 2 ◦ Unequivocally regressing ROP in zone III

5. Examinations will be stopped based on age and ophthalmoscopy findings such as zone III vascularization without previous zone I or II ROP, full retinal vascularization near the ora for 360 degrees, postmenstrual age of 50 weeks without prethreshold disease (defined in Table 3) or worse ROP, and full ROP regression.
6. If remote interpretation of digital photographic retinal images is used for ROP screening, the providers should still comply with the timing and other recommendations outlined previously. Photographs and their interpretations should be recorded into the permanent medical record. Indirect ophthalmoscopy should still be physically performed by a qualified ophthalmologist before treatment or termination of acute phase screening.

Telemedicine Screening

The use of telemedicine techniques for ROP screening has become increasingly popular over the past two decades. Digital photographs of the retina taken by a RetCam are sent to a remote location for analysis by a trained professional. The photography and analysis may be performed by an ophthalmologist or a qualified non-physician. The Stanford University Network for Diagnosis of Retinopathy of Prematurity (SUNDROP) trial evaluated 1022 eyes with treatment warranted ROP using analyses from a remote ROP specialist. SUNDROP found that telemedicine had 100% sensitivity, 99.8% specificity, 93.8% positive predictive value, and 100% negative predictive value for detection of treatment warranted ROP [36]. Telemedicine correctly detected prethreshold, threshold, stage 4, or stage 5 ROP in 89% of eyes and plus disease in 95% of eyes according to an earlier study [37]. Results were also consistent amongst different readers analyzing the same photographs. The intrareader reliability for detection of low-risk prethreshold ROP or worse was 100% for all 3 readers from a 2006 study [38]. The image quality was rated as "adequate" or "possibly adequate" for diagnosis in 93-100% of eyes [39]. Overall, these studies suggest that ROP screening using telemedicine has high accuracy, reliability, and validity. It may be a viable option to supplement indirect ophthalmoscopy, especially in situations where certain resources, like pediatric ophthalmologists, are scarce.

Treatment and Management Guidelines

Ablative therapy

Cryotherapy and laser photocoagulation are the two main types of ablative therapy for ROP. The treatment is directed at the anterior avascular retina, which produces high amounts of VEGF in ROP. Ablation of carefully selected avascular regions is thought to lower the angiogenic factor (*i.e.*, VEGF) production, which slows neovascularization [1].

Cryotherapy can be applied transconjunctivally under topical or local anesthesia with a probe to cause ablation of the avascular regions. The CRYO-ROP study was designed to evaluate the safety and efficacy of cryotherapy for ROP. In that study, cryotherapy treatment was performed only when the ROP reached threshold status, as discussed in the *Classification* section above. The one-year follow-up showed that 25.7% of cryotherapy-treated eyes developed an unfavorable outcome – defined as retinal fold involving the macula, retinal detachment in zone I, or retrolental mass obscuring posterior pole – compared to 47.4% of eyes in the control group [31]. At the 10-year follow up, CRYO-ROP found that both functional (*e.g.*, visual acuity) and structural (*e.g.*, fundus status) outcomes were improved in the treatment group versus the control group [40]. Cryotherapy-treated eyes only had a 5% visual field reduction compared to the fellow eye [41]. Overall, the CRYO-ROP studies support the long-term efficacy and safety of cryotherapy treatment [1].

More commonly, ablation is performed by laser application using indirect ophthalmoscopy. The benefits are increased convenience, ease of administration, less need for anesthesia, and better patient tolerance [42]. The risks, however, include corneal haze, intraocular burns, choroidal hemorrhage, and cataracts [1]. A number of studies, such as the meta-analysis conducted by the Laser ROP Study group in 1994 proposed that laser treatment was as effective as cryotherapy [42, 43]. Laser-treated eyes were even found to have better structural (retinal dragging) and functional (visual acuity) outcomes compared with cryotherapy treated eyes at the 10-year follow-up after treatment [44]. The ET-ROP trial recommended early treatment of high-risk prethreshold ROP (*i.e.*, type 1 ROP) with ablative therapy to reduce unfavorable outcomes; observation of type 2 ROP for detection of further progression was recommended [32]. Overall, these studies not only support the use of laser photocoagulation as a viable cryotherapy alternative but also encourage the early treatment of ROP with either laser or cryotherapy before progression to threshold status.

Anti-angiogenic Treatment

Ablative treatments, namely laser photocoagulation, may lead to permanent peripheral visual field loss, induction of myopia, intraocular burns, cataract formation, vitreous hemorrhage, strabismus, among others. Concern with these issues led to the proposal that non-destructive anti-VEGF factors, such as bevacizumab, could be used as a treatment alternative. The Bevacizumab Eliminates the Angiogenic Threat of Retinopathy of Prematurity (BEAT-ROP) study was a randomized, controlled trial that compared intravitreal bevacizumab monotherapy to conventional laser therapy for stage 3+ in zone I and II ROP [45]. BEAT-ROP found that

bevacizumab therapy produced significantly better benefit for zone I, but not zone II, and allowed peripheral vessels to continue growing unlike laser-induced ablation [45]. Bevacizumab injection was also easier to administer at the bedside compared to laser treatment.

However, BEAT-ROP was not able to statistically assess bevacizumab's safety profile concerning mortality and toxicity [45]. ROP recurrence and retinal detachments have been reported after bevacizumab treatment at a later onset compared to laser treatment, raising the concern that BEAT-ROP may have not fully captured recurrence and complication data [46]. The Pediatric Eye Disease Investigator Group (PEDIG) studied various doses of bevacizumab for treatment of type I ROP; this dose de-escalation study demonstrated that a lower dose of bevacizumab (e.g., 0.031mg) may reduce the risk for neurodevelopmental disability or detrimental effects on other organs while maintaining efficacy [47]. A Cochrane meta-analysis in 2018 reviewed six clinical trials using intravitreal anti-VEGF for treatment of type I ROP; a total of 383 infants were included in the combined dataset [48]. These data showed that anti-VEGF monotherapy reduces the risk of refractive errors but does not reduce the risk of retinal detachment or recurrence of ROP. Further, this monotherapy potentially increases the risk of recurrence in zone II ROP, and the long-term systemic adverse effects of the drugs are not known [48].

Supplemental Oxygen

The Supplemental Therapeutic Oxygen for Prethreshold Retinopathy of Prematurity (STOP-ROP) tested the hypothesis that oxygen supplementation would downregulate VEGF to cause regression of neovascularization in eyes with prethreshold ROP. STOP-ROP found that supplemental oxygen targeting O₂ saturation range of 96-99% did not exacerbate prethreshold ROP but did not significantly reduce the number of infants requiring peripheral ablative therapy. The risks, however, included adverse pulmonary events, like pneumonia or exacerbations of chronic lung disease [30]. In a more recent study, biphasic oxygen targets (e.g., 85% to 92% at younger than 34 weeks and > 95% at 34 weeks and older) have shown a decrease in ROP incidence and severity without increasing mortality [49]. One University of Iowa research team published an oxygen therapy protocol, based on the STOP-ROP Trial, that has been shown to inhibit further progression of stage 2 ROP or worse in premature infants [17]. The baseline target oxygen saturations in that study were set to 85-95% and increased to >97% after diagnosis of prethreshold or worse ROP [17]. This oxygen saturation protocol is currently used at the University of Iowa Hospitals & Clinics; please see Colaizy, *et al.* for protocol details. There is ongoing research for development of systemic therapies (e.g., hypoxia-inducible factor stabilization) to protect the premature retina from oxygen toxicity [50].

Surgical Management in Severe ROP

Retinal detachments associated with late stage ROP often require surgical intervention. The surgical techniques used in advanced ROP cases include scleral buckle (SB), pars plana vitrectomy (PPV) with or without lensectomy, or a combination of SB with PPV; however, the techniques and challenges of these procedures in pediatric populations are unique. A clinician must first identify the type of retinal detachment, as ROP can cause tractional retinal detachments (most common), rhegmatogenous retinal detachments, and, rarely, exudative detachments. SB is rarely performed alone if there is preoperative proliferative vitreoretinopathy (PVR), yet one study showed that >75% of advanced stage ROP patients have PVR [51]. Thus, PPV is often the preferred surgical procedure in ROP with or without a SB. Recurrence and reoperations are increased in this cohort with approximately 38.5% of advanced stage ROP patients requiring more than one surgery [51].

A study by Gusson, *et al.*, demonstrated long-term anatomic success in 58% of eyes undergoing PPV for ROP-related retinal detachments involving the macula [52]. However, once the macula is involved, such as in Stage 4B and Stage 5, the functional outcomes are, overall, poor even with anatomical success.

Retinopathy of Prematurity

EPIDEMIOLOGY OR ETIOLOGY	SIGNS
<ul style="list-style-type: none"> • Leading cause of childhood blindness • Associated with low birth weight and gestational age • Hyperoxia, postnatal stressors, and lack of protective <i>in utero</i> factors contribute to the arrest of retinal vascular development and/or neovascularization • Worldwide, there are approximately 184,700 new cases of ROP per year [3] 	<ul style="list-style-type: none"> • Immature vessels • White demarcation line and/or elevated ridge between avascular and vascular retina • Extraretinal fibrovascular proliferation • Dilatation of veins and tortuosity of arteries • Leukocoria • Partial or total retinal detachment(s)

RISK FACTORS FOR DEVELOPING ROP [22]	TREATMENT/MANAGEMENT
<ul style="list-style-type: none"> • Gestational age of ≤ 30 weeks • Birth weight ≤ 1500 grams • High oxygen levels and/or prolonged oxygen supplementation in addition to oxygen saturation fluctuations likely have a role in ROP development • Hyperglycemia, apnea, severe illness (e.g., sepsis), anemia, intraventricular hemorrhage, respiratory distress syndrome, and patent ductus arteriosus • Maternal factors, such as poor nutrition and limited prenatal care 	<ul style="list-style-type: none"> • See Table 4 for the recommended ROP screening schedule using 2018 guidelines [35] • Adhere to follow-up schedule based on the ROP classification (See above <i>Screening</i> section) • Ablative therapy: Cryotherapy and laser photocoagulation of anterior avascular retina recommended in threshold ROP, as defined in Table 3 • Anti-angiogenic treatment: Bevacizumab treatment is being used in increasing frequency as a substitute for ablative therapy in type I ROP but there are insufficient data on safety and long-term effects [48] • Supplemental oxygen management aimed to decrease exposure to high levels of oxygen while providing enough oxygen to minimize respiratory distress and other prematurity-related disorders

References

1. Ober RR, Palmer EA, Drack AV, Wright KW. Retinopathy of Prematurity. In: Wright KW, Spiegel PH, Thompson LS, editors. *Handbook of Pediatric Retinal Disease*. New York, NY: Springer New York; 2006; p. 284-349.
2. Gilbert C. Retinopathy of prematurity: A global perspective of the epidemics, population of babies at risk and implications for control. *Early Human Development* 2008;84(2):77-82. <https://pubmed.gov/WOS:000255580500003>. DOI: 10.1016/j.earlhumdev.2007.11.009
3. Blencowe H, Lawn JE, Vazquez T, Fielder A, Gilbert C. Preterm-associated visual impairment and estimates of retinopathy of prematurity at regional and global levels for 2010. *Pediatric Research* 2013;74:35-49. <https://pubmed.gov/WOS:000331157400004>. DOI: 10.1038/pr.2013.205
4. Vos T, Flaxman AD, Naghavi M, Lozano R, Michaud C, Ezzati M, Shibuya K, Salomon JA, Abdalla S, Aboyans V, Abraham J, Ackerman I, Aggarwal R, Ahn SY, Ali MK, Alvarado M, Anderson HR, Anderson LM, Andrews KG, Atkinson C, Baddour LM, Bahalim AN, Barker-Collo S, Barrero LH, Bartels DH, Basanez MG, Baxter A, Bell ML, Benjamin EJ, Bennett D, Bernabe E, Bhalla K, Bhandari B, Bikbov B, Bin Abdulhak A, Birbeck G, Black JA, Blencowe H, Blore JD, Blyth F, Bolliger I, Bonaventure A, Boufous S, Bourne R, Boussinesq M, Braithwaite T, Brayne C, Bridgett L, Brooker S, Brooks P, Brugha TS, Bryan-Hancock C, Bucello C, Buchbinder R, Buckle G, Budke CM, Burch M, Burney P, Burstein R, Calabria B, Campbell B, Canter CE, Carabin H, Carapetis J, Carmona L, Cella C, Charlson F, Chen H, Cheng AT, Chou D, Chugh SS, Coffeng LE, Colan SD, Colquhoun S, Colson KE, Condon J, Connor MD, Cooper LT, Corriere M, Cortinovis M, de Vaccaro KC, Couser W, Cowie BC, Criqui MH, Cross M, Dabhadkar KC, Dahiya M, Dahodwala N, Damsere-Derry J, Danaei G, Davis A, De Leo D, Degenhardt L, Dellavalle R, Delossantos A, Denenberg J, Derrett S, Des Jarlais DC, Dharmaratne SD, Dherani M, Diaz-Torne C, Dolk H, Dorsey ER, Driscoll T, Duber H, Ebel B, Edmond K, Elbaz A, Ali SE, Erskine H, Erwin PJ, Espindola P, Ewoigbokhan SE, Farzadfar F, Feigin V, Felson DT, Ferrari A, Ferri CP, Fevre EM, Finucane MM, Flaxman S, Flood L, Foreman K, Forouzanfar MH, Fowkes FG, Franklin R, Fransen M, Freeman MK, Gabbe BJ, Gabriel SE, Gakidou E, Ganatra HA, Garcia B, Gaspari F, Gillum RF, Gmel G, Gosselin R, Grainger R, Groeger J, Guillemin F, Gunnell D, Gupta R, Haagsma J, Hagan H, Halasa YA, Hall W, Haring D, Haro JM, Harrison JE, Havmoeller R, Hay RJ, Higashi H, Hill C, Hoen B, Hoffman H, Hotez PJ, Hoy D, Huang JJ, Ibeanusi SE, Jacobsen KH, James SL, Jarvis D, Jasrasaria R, Jayaraman S, Johns N, Jonas JB, Karthikeyan G, Kassebaum N, Kawakami N, Keren A, Khoo JP, King CH, Knowlton LM, Kobusingye O, Koranteng A, Krishnamurthi R, Laloo R, Laslett LL, Lathlean T, Leasher JL, Lee YY, Leigh J, Lim SS, Limb E, Lin JK, Lipnick M, Lipshultz SE, Liu W, Loane M, Ohno SL, Lyons R, Ma J, Mabweijano J, MacIntyre MF, Malekzadeh R, Mallinger L, Manivannan S, Marcenes W, March L, Margolis DJ, Marks GB, Marks R, Matsumori A, Matzopoulos R, Mayosi BM, McAnulty JH, McDermott MM, McGill N, McGrath J, Medina-Mora ME, Meltzer M, Mensah GA, Merriman TR, Meyer AC, Miglioli V, Miller M, Miller TR, Mitchell PB, Mocumbi AO, Moffitt TE, Mokdad AA, Monasta L, Montico M, Moradi-Lakeh M, Moran A, Morawska L, Mori R, Murdoch ME, Mwaniki MK, Naidoo K, Nair MN, Naldi L, Narayan KM, Nelson PK, Nelson RG, Nevitt MC, Newton CR, Nolte S, Norman P, Norman R, O'Donnell M, O'Hanlon S, Olives C, Omer SB, Ortblad K, Osborne R, Ozgediz D, Page A, Pahari B, Pandian JD, Rivero AP, Patten SB, Pearce N, Padilla RP, Perez-Ruiz F, Perico N, Pesudovs K, Phillips D, Phillips MR, Pierce K, Pion S, Polanczyk GV, Polinder S, Pope CA, 3rd, Popova S, Porrini E, Pourmalek F, Prince M, Pullan RL, Ramaiah KD, Ranganathan D, Razavi H, Regan M, Rehm JT, Rein DB, Remuzzi G, Richardson K, Rivara FP, Roberts T, Robinson C, De Leon FR, Ronfani L, Room R, Rosenfeld LC, Rushton L, Sacco RL, Saha S, Sampson U, Sanchez-Riera L, Sanman E, Schwebel DC, Scott JG, Segui-Gomez M, Shahraz S, Shepard DS, Shin H, Shivakoti R, Singh D, Singh GM, Singh JA, Singleton J, Sleet DA, Sliwa K, Smith E, Smith JL, Stapelberg NJ, Steer A, Steiner T, Stolk WA, Stovner LJ, Sudfeld C, Syed S, Tamburlini G, Tavakkoli M, Taylor HR, Taylor JA, Taylor WJ, Thomas B, Thomson WM, Thurston GD, Tleyjeh IM, Tonelli M, Towbin JA, Truelsen T, Tsilimbaris MK, Ubeda C, Undurraga EA, van der Werf MJ, van Os J, Vavilala MS, Venketasubramanian N, Wang M, Wang W, Watt K, Weatherall DJ, Weinstock MA, Weintraub R, Weisskopf MG, Weissman MM, White RA, Whiteford H, Wiersma ST, Wilkinson JD, Williams

- HC, Williams SR, Witt E, Wolfe F, Woolf AD, Wulf S, Yeh PH, Zaidi AK, Zheng ZJ, Zonies D, Lopez AD, Murray CJ, AlMazroa MA, Memish ZA. Years lived with disability (YLDs) for 1160 sequelae of 289 diseases and injuries 1990-2010: a systematic analysis for the Global Burden of Disease Study 2010. *Lancet* 2012;380(9859):2163-2196. <https://pubmed.gov/23245607>. DOI: 10.1016/S0140-6736(12)61729-2
5. Ludwig CA, Chen TA, Hernandez-Boussard T, Moshfeghi AA, Moshfeghi DM. The Epidemiology of Retinopathy of Prematurity in the United States. *Ophthalmic Surg Lasers Imaging Retina* 2017;48(7):553-562. <https://pubmed.gov/28728176>. DOI: 10.3928/23258160-20170630-06
 6. Lueder GT. Disorders of the Retina and Vitreous. *2014-2015 Basic and Clinical Science Course, Section 06: Pediatric Ophthalmology and Strabismus*. San Francisco, CA: American Academy of Ophthalmology; 2014; chapter 25.
 7. Flynn JT, Bancalari E, Bachynski BN, Buckley EB, Bawol R, Goldberg R, Cassady J, Schiffman J, Feuer W, Gillings D, et al. Retinopathy of prematurity. Diagnosis, severity, and natural history. *Ophthalmology* 1987;94(6):620-629. <https://pubmed.gov/3627710>
 8. Hellstrom A, Smith LEH, Dammann O. Retinopathy of prematurity. *Lancet* 2013;382(9902):1445-1457. <https://pubmed.gov/WOS:000326237500029>. DOI: 10.1016/s0140-6736(13)60178-6
 9. Multicenter trial of cryotherapy for retinopathy of prematurity. 3 1/2-year outcome--structure and function. Cryotherapy for Retinopathy of Prematurity Cooperative Group. *Arch Ophthalmol* 1993;111(3):339-344. <https://pubmed.gov/8447743>
 10. Palmer EA, Flynn JT, Hardy RJ, Phelps DL, Phillips CL, Schaffer DB, Tung B. Incidence and early course of retinopathy of prematurity. The Cryotherapy for Retinopathy of Prematurity Cooperative Group. *Ophthalmology* 1991;98(11):1628-1640. <https://pubmed.gov/1800923>
 11. Flynn JT, Bancalari E, Bawol R, Goldberg R, Cassady J, Schiffman J, Feuer W, Roberts J, Gillings D, Sim E, et al. Retinopathy of prematurity. A randomized, prospective trial of transcutaneous oxygen monitoring. *Ophthalmology* 1987;94(6):630-638. <https://pubmed.gov/3627711>
 12. Flynn JT, Bancalari E, Snyder ES, Goldberg RN, Feuer W, Cassady J, Schiffman J, Feldman HI, Bachynski B, Buckley E, et al. A cohort study of transcutaneous oxygen tension and the incidence and severity of retinopathy of prematurity. *N Engl J Med* 1992;326(16):1050-1054. <https://pubmed.gov/1549150>. DOI: 10.1056/nejm199204163261603
 13. Shohat M, Reisner SH, Krikler R, Nissenkorn I, Yassur Y, Ben-Sira I. Retinopathy of prematurity: incidence and risk factors. *Pediatrics* 1983;72(2):159-163. <https://pubmed.gov/6408596>
 14. Lucey JF, Dangman B. A reexamination of the role of oxygen in retrolental fibroplasia. *Pediatrics* 1984;73(1):82-96. <https://pubmed.gov/6419199>
 15. Tin W, Milligan DW, Pennefather P, Hey E. Pulse oximetry, severe retinopathy, and outcome at one year in babies of less than 28 weeks gestation. *Arch Dis Child Fetal Neonatal Ed* 2001;84(2):F106-110. <https://pubmed.gov/11207226>. DOI: 10.1136/fn.84.2.f106
 16. Askie LM, Darlow BA, Davis PG, Finer N, Stenson B, Vento M, Whyte R. Effects of targeting lower versus higher arterial oxygen saturations on death or disability in preterm infants. *Cochrane Database of Systematic Reviews* 2017;10.1002/14651858.CD011190.pub2(4):80. <https://pubmed.gov/WOS:000400759700041>. DOI: 10.1002/14651858.CD011190.pub2
 17. Colaizy TT, Longmuir S, Gertsch K, Abramoff MD, Klein JM. Use of a Supplemental Oxygen Protocol to Suppress Progression of Retinopathy of Prematurity. *Invest Ophthalmol Vis Sci* 2017;58(2):887-891. <https://pubmed.gov/28159975>. DOI: 10.1167/iovs.16-20822
 18. Charles JB, Ganthier R, Jr., Appiah AP. Incidence and characteristics of retinopathy of prematurity in a low-income inner-city population. *Ophthalmology* 1991;98(1):14-17. <https://pubmed.gov/2023725>
 19. Darlow BA, Horwood LJ, Clemett RS. Retinopathy of prematurity: risk factors in a prospective population-based study. *Paediatr Perinat Epidemiol* 1992;6(1):62-80. <https://pubmed.gov/1553319>
 20. Gunn TR, Easdown J, Outerbridge EW, Aranda JV. Risk factors in retrolental fibroplasia. *Pediatrics* 1980;65(6):1096-1100. <https://pubmed.gov/6892851>
 21. Hammer ME, Mullen PW, Ferguson JG, Pai S, Cosby C, Jackson KL. Logistic analysis of risk factors in acute retinopathy of prematurity. *Am J Ophthalmol* 1986;102(1):1-6. <https://pubmed.gov/3728608>
 22. Kim SJ, Port AD, Swan R, Campbell JP, Chan RVP, Chiang MF. Retinopathy of prematurity: a review of risk factors and their clinical significance. *Surv Ophthalmol* 2018;63(5):618-637. <https://pubmed.gov/29679617>. DOI: 10.1016/j.survophthal.2018.04.002
 23. Schaffer DB, Palmer EA, Plotsky DF, Metz HS, Flynn JT, Tung B, Hardy RJ. Prognostic factors in the natural course of retinopathy of prematurity. The Cryotherapy for Retinopathy of Prematurity Cooperative Group. *Ophthalmology* 1993;100(2):230-237. <https://pubmed.gov/8437832>
 24. Glass P, Avery GB, Subramanian KN, Keys MP, Sostek AM, Friendly DS. Effect of bright light in the hospital nursery on the incidence of retinopathy of prematurity. *N Engl J Med* 1985;313(7):401-404. <https://pubmed.gov/3839567>. DOI: 10.1056/nejm198508153130701
 25. Reynolds JD, Hardy RJ, Kennedy KA, Spencer R, van Heuven WA, Fielder AR. Lack of efficacy of light reduction in preventing retinopathy of prematurity. Light Reduction in Retinopathy of Prematurity (LIGHT-ROP) Cooperative Group. *N Engl J Med* 1998;338(22):1572-1576. <https://pubmed.gov/9603794>. DOI: 10.1056/nejm199805283382202
 26. Hartnett ME. Pathophysiology and mechanisms of severe retinopathy of prematurity. *Ophthalmology* 2015;122(1):200-210. <https://pubmed.gov/25444347>. DOI: 10.1016/j.ophtha.2014.07.050
 27. An international classification of retinopathy of prematurity. The Committee for the Classification of Retinopathy of Prematurity. *Arch Ophthalmol* 1984;102(8):1130-1134. <https://pubmed.gov/6547831>

28. An international classification of retinopathy of prematurity. II. The classification of retinal detachment. The International Committee for the Classification of the Late Stages of Retinopathy of Prematurity. *Arch Ophthalmol* 1987;105(7):906-912. <https://PubMed.gov/3606449>
29. The International Classification of Retinopathy of Prematurity revisited. *Arch Ophthalmol* 2005;123(7):991-999. <https://PubMed.gov/16009843>. DOI: 10.1001/archophth.123.7.991
30. Phelps DL, Lindblad A, Bradford JD, Wood NE, Oden NL, Cole C, MacKinnon B, Yaffe A, Everett DF, Wright L, Krulewicz C, Brozanski BS, Young T, Scott M, Hawkins BS, Begg CB, Bell EF, Buckley EG, Hay WW, Kushner BJ, Snouck-Hurgronje L, Taylor CR, Oden NL, Lindblad AS, Bachy C, Berlin SH, Brandt D, Guzzey M, Henson L, Jolles B, Stine E, Thomas-Sharp C, Van Lare J, Yaffe A, Cole C, Stewart J, MacKinnon B, Alexander T, Anderson C, Ashrafzadeh M, Baumal C, Bhatt A, Blocker R, Brown E, Cordova M, Dacey MP, Duker J, Eagle J, Eichenwald E, Faherty C, Fujii A, Gray J, Hartnett ME, Harvey-Wilkes K, Hetrick J, Hughes M, Ip M, Izatt S, Lacy R, Levy J, Margolis T, McAlmon KR, McCabe O, Moore M, Niffenegger J, Nikou S, Petersen R, Petit K, Pierce EA, Powers B, Pursley M, Reichel E, Remis L, Rivellese M, Shephard BA, Sorkin J, Stark A, Struzik S, Tran T, VanderVeen DK, Vreeland P, Wilker R, Wright J, Kim V, Desai V, Rutledge B, McClead RE, Fellows R, Biel M, Bremer DL, Maddox R, Mann B, McGregor ML, Nye C, Peterman P, Rogers GL, Rosenberg EM, Seguin J, Stephen S, Anderson CW, Cordero L, Spitzer AR, Corcoran L, Cullen J, Fosnot J, Desai S, Fricko J, Giannetta J, Harris MC, Hepps D, Hertle R, Holt B, Leef K, McNamara JA, Miller D, Mooney K, Naidoff M, Pleasure JR, Porat R, Quinn G, Saunders T, Schaffer D, Spear M, Spinner S, Tasman W, Vander JF, Wilson M, Zirin S, Bradford JD, Ables P, Bonner C, Brodsky M, Davis E, Frost K, Hall RW, Harper R, Thomas BR, Barr CC, Adamkin D, Douglas CH, Fishman PH, Hamlyn-Forti N, Hilbert T, Roberts J, Whittington G, Wright J, Oh W, Adams N, Andrews D, Geltzer AI, Hensman A, Philo-Heroux S, Rothstein RW, Snady-McCoy L, Stoll B, Capone A, Critz AD, Drack AV, Goulding CH, Martin DF, Olsen TW, Sternberg P, White MB, Lemons JA, Appel DD, Denne SC, Ellis F, Helveston E, McKee A, Neely D, Plager D, Sprunger D, Wilson D, Wright LD, Stevenson DK, Alcorn DM, Ball MB, Bone D, Fleisher BE, Gaynon MW, Good WV, Inguillo D, Burke M, Carden S, Colegate S, Good WV, Grisby C, Hitchcock B, Hutchins RK, Khan AO, Kotagal U, Mersmann M, Munson K, Sheppard RW, West C, Korones S, Bada H, Borirak S, Brewer B, Camp G, Dempsey S, Devine C, Downie A, Faber DW, Grimes S, Hairston R, Hensley B, Hudson T, Johnson V, Katz A, Manejwala L, Schwartz J, Zocchi K, Landers M, Jewart B, Tyson JE, Kennedy K, Anand R, Hensley G, Metrikin D, Spencer R, Warner S, Weakley D, Wilson CA, Burchfield J, Bedard M, Baker JD, Bara R, Casabar R, Liang KC, Lucas W, Muran G, O'Malley E, Pulkin JE, Roarty J, Shankaran S, Trese M, Ehrenkranz RA, Bartley C, Gettner PA, Juliano G, Konstantino M, Moylan S, Peterec SM, Sears J, Sherwonit E, Stoessel K, Easa D, Drouilhet JH, Ash K, Atebara N, Balaraman V, Debuque L, Douglas J, Fritz E, Hirai C, Iwamoto L, Kau S, Kokame G, Liao P, Loo S, Meister J, Murai D, Nakamura KT, Patrinos ME, Pelke S, Post G, Sood S, Sroat DA, Tinsley L, Wong B, Wong V, Brozanski BS, Cheng KP, Bergren RL, Biglan AW, Davis JS, Doft B, Hoffman ME, Jones J, Laneri G, Lobes LA, Olsen KR, Rinkoff J, Vazquez RL, Phelps DL, Wood N, Brown K, Mansfield LR, Markowitz GD, Guillet E, Morris J, Nicoletta K, Rose S, Sinkin R, Tingley D, Vanderlinde R, Shutts S, Carrion V, Cummings J, Awner S, Marano D, Olitsky S, Reynolds J, Terpin M, Gordon R, Diamond JG, Hasty-Voelkel B, Neff D, Reynolds J, Storch TG, Weber PA, Barondes MJ, Browne L, Combs A, Elbaba F, Gallagher K, Gerontis CC, King K, Kleinman L, Kodsí S, LaGamma E, Lipsitz P, Marmor M, McGovern RV, Wilkens B, Kokomoor FW, Burton JE, Enlow MK, Feick HJ, Jaberg CE, Kelley A, Kisk MJ, Locastro AJ, Peter CA, Tsai TJ, Shapiro MJ, Holmes JM, Abbasi I, Adeni S, Aldana O, Alter D, Annerino KA, Arora S, Becker H, Bhat R, Bigger HR, Bunjapamai W, Cattamanchi G, Cohen JA, Collins JW, Cronin CM, Daily MJ, Davis CL, De Alba F, DeKowski SA, Deddish RB, Dorton A, Dray PB, Duffner LA, Dusek L, Dyer DS, Enger MC, Fisher JB, Fiumara A, Friedlander S, Ghai V, Gieser JP, Gieser RG, Greenwald MJ, Gunawardene NR, Gupta B, Guyer N, Hennessy AM, Hernandez G, Hyde DC, Illian M, Jain R, Jansen RD, Kaufman LM, Kling P, Kurtz RM, Lai C, Leamy MJ, Lukose A, Lyon AT, MacCumber M, McCulloch KTM, McDonnell JF, Menner C, Mets MB, Millard DD, Miller MT, Mockovak ME, Morose A, Naber M, Nitz P, Ogata ES, Palanpurwala KA, Paulin CA, Payton J, Phillipotts BA, Pyati S, Raju TNK, Resnick KI, Rugar B, Sajous C, Santiago NE, Dunseath-Shuman B, Simmons RA, Singh A, Skopec DL, Solomon MJ, Squires MA, Ticho BH, Vasan U, Vidyasagar D, Wall SN, Weinberg AB, Weinberg DV, Wilks A, Zikos E, Banagale RC, Aaby AA, Banta-Wright SA, Baxter LM, Bellant JK, Benda G, Binder ND, Brown WJ, Cheldelin L, Christensen L, DeVito V, Dolphin NG, Dunham S, Edwards A, Gilhooly JT, Goodman S, Huston R, Lewallen PK, McDonald J, Mischel R, Murphy DL, Newman V, Novack CM, Owen S, Palmer EA, Pillers DM, Powers M, Rimmer S, Robertson J, Smith SA, Tongue AC, Wallen LD, Wheeler DT, Stern ME, Auerbach R, Dorfman M, Poliak JG, Weinstein B, Wigton K, Preslan MW, Gewolb IH, Aristimuno B, Birenbaum HJ, Bristol B, Dulkerian S, Gutberlet RL, Hutcheson K, Palmer TW, Repka MX, Schoedel C, Steidl S, Tanbusch T, Waeltermann J, Wong RV, Feman SS, Cotton RB, Donahue S, Johnson DA, Law AB, Sinatra RB, Steele SD, Walsh WF, Kirk J, Stewart MW, Bolling JP, Bryan JS, Chapman-Shaw VL, Garrison RD, Hered RW, Higgison J, Hunter LR, Lambrou FH, Ott LA, Pogrebniak AE, Self M, Vargo V, Vaughn AJ, Young J, Young TL, Angel CS, Bendel CM, Brasel D, Chisholm K, Christiansen S, Cifuentes RF, Cook SM, Egbert JE, Engel RR, Fangman J, Geier P, Holleschau AM, Janda AM, Maxwell M, Miller C, Mills MM, Neely KA, Pier T, Rebertus KS, Rodman WP, Summers CG, Trower NL, McCaffree MA, Scott M, Bradford RH, Brown RD, Butcher J, Co E, Corff K, Grellner A, Henson L, King L, Lopez S, Shofner JM, Tolentino TA, Wlodaver AG, Satish M, Bradley B, Dabbs CK, Gall VM, Gunther K, Rosenthal JG, Troxell B, Droste PJ, Alexander C, Beaumont E, Glazer L, Johnson L, Margherio AR, Mesecar S, Pippenger CE, Spencer M, VanWesop G, Winslow C, Grp S-RMS. Supplemental therapeutic oxygen for prethreshold retinopathy of prematurity (STOP-ROP), a randomized, controlled trial. I: Primary outcomes. *Pediatrics* 2000;105(2):295-310. <https://PubMed.gov/WOS:000085106500013>
31. Multicenter trial of cryotherapy for retinopathy of prematurity. One-year outcome--structure and function. Cryotherapy for Retinopathy of Prematurity Cooperative Group. *Arch Ophthalmol* 1990;108(10):1408-1416. <https://PubMed.gov/2222274>
32. Good WV, Hardy RJ, Dobson V, Palmer EA, Phelps DL, Quintos M, Tung B, Madan A, Gaynon M, Ball MB, Hartsell P, Inguillo D, Alcorn D, Good WV, Ornitz D, Stevenson D, Good WV, Hubbard M, Lee J, Brinton D, Day S, Durand D, Fredrick D, Phibbs RH, Schwartz D, Slagle T, Smith G, Shapiro M, Garcia Y, Genio M, Parker J, Rugar B, Becker H, Bhat R, Bloom JN, Corsino JV, Kaufman L, Lai WW, Pulido J, Raju TNK, Shukla AK, Ticho B, Vidyasagar D, Lemons J, Neely D, Appel DD, Hynes E, Wright L,

Plager D, Sondhi N, Sprunger D, Barr CC, Whittington GK, Cowley M, Douglas CH, Fishman PH, Robinson T, Rychwalski PJ, Gordon A, Neff DS, Babel DB, Diamond JG, Gill WL, Gewolb IH, Hutcheson KA, Huynh L, Kalsi R, Liu XN, Smell J, Dulkerian SJ, Elman MJ, Jones E, Preslan MW, Steidl SM, Repka MX, Shepard JA, Donahue P, Aucott SW, Blechman T, Collins ML, Gilmore MM, Handa JT, Mudgil AV, Nguyen QD, Parsa CF, Pieramici D, Plotsky D, Pomerance JJ, Cole CH, Vanderveen D, Berman L, Faherty C, Hurley C, Mansfield T, McKinnon B, Moore M, Baumal C, Bhatt A, Dacey M, Duker J, Eagle J, Fraioli A, Greenberg P, Hughes M, Lacy R, McCabe O, Peterson R, Reichel E, Rogers A, Stinson W, Strominger M, Baker J, Cumming K, Kulak M, Manatrey P, Bedard M, Capone A, Casabar R, O'Malley E, Rao R, Roarty J, Trese M, Williams G, Christiansen SP, Cook S, Holleschau A, Maxwell M, Mills M, Miller C, Rebertus K, Trower N, Bennett S, Brasel D, Couser R, Dev S, Jensen A, Lussky R, Miller G, Mitra R, Olsen T, Ramsey R, Rosen W, Ryan E, Springer S, Steuer E, Summers CG, Williams D, Davitt BV, Breuer J, Breuer L, Cruz O, Feman S, Keenan W, Mantych G, Freedman S, Wallace D, Camp E, Clark S, Hutchins L, Lake L, Buckley E, Enyedi L, Reynolds JD, Gordon DC, Kuppel B, Awner S, Ryan R, Weber PA, Combs A, Dweck N, Charles H, Chou T, DeCristofaro J, Gerontis C, Horowitz M, Koty R, LaGamma E, Marmor M, Flynn J, Lee T, Coki O, Chiang M, Kane S, Krauss A, Lopez R, Polin R, Phelps DL, Gross SJ, Hakanson D, Dodge M, Horihan C, Parker P, Phillips J, Asselin D, Chang SHW, Guillet E, Hampton R, Markowitz G, Merriam W, Noel LP, Olsen R, Pesce S, Rose S, Rutledge B, Simon R, Spalding S, Tingley D, Torrisi P, Vanderlinde R, Rogers GL, Bremer D, Fellows R, Klamfoth S, Mann B, Cordero L, Hertle R, Letson A, McClead R, McGregor ML, Wall P, Siatkowski RM, Corff KE, Fuhr M, Bradford RH, Leonard RE, Scott MH, Wheeler DT, Davis K, Dolphin N, Dunham S, Aaby A, Goodman S, Lauer A, Newman V, Palmer EA, Pillers DA, Robertson J, Stout A, Stout T, Tongue A, Quinn GE, Koh JG, Letterio ME, McDaniel M, Abbasi S, Edmond JC, Forbes BJ, Maguire AM, Mills MD, Pierce EA, Young TL, Cheng K, Jones J, Bergren R, Brozanski B, Doft B, Fineman M, Lobes L, Olsen K, Saunders RA, Langdale L, Hutchinson A, Peterseim MM, Purohit D, Coats DK, Gonzalez L, Kazymyrko N, Sanchez A, Steward M, Brady-McCreery K, Garcia-Prats J, Holz E, Jarriel S, Johnson K, Mandy G, Paysee EA, Rainey AM, Yen KG, van Heuven WAJ, Gong AK, Drummond MH, Cleland TP, MacDonald JC, Marouf LM, Rubio JE, Hoffman R, Bracken S, Bernstein P, Dries D, King J, Olson R, Teske M, Yen K, Redford M, Mowery RL, Everett DF, Quintos B, Hardy RJ, Tung B, Cooper C, Tsai G, Wu MF, Minard C, Rather K, Dobson V, Quinn GE, Mohan KM, Baldwin MB, Delaney SM, Connett J, Donovan EF, Hillis A, Holmes JM, Miller JM, Taylor CR, Dobson V, Baldwin MB, Delaney SM, Connett J, Hillis A, Holmes JM, Miller JM, Taylor CR, Redford M, van Heuven WAJ, Barr C, Gaynon M, Shapiro M, Jones J, Cumming K, Neff DS, Results Early Treatment R. Revised indications for the treatment of retinopathy of prematurity - Results of the early treatment for retinopathy of prematurity randomized trial. *Archives of Ophthalmology* 2003;121(12):1684-1696.

<https://PubMed.gov/WOS:000187115200001>

33. American Academy of Pediatrics. Section on O. Screening examination of premature infants for retinopathy of prematurity. *Pediatrics* 2001;108(3):809-811. <https://PubMed.gov/11533356>
34. Fierson WM, Saunders RA, Good W, Palmer EA, Phelps D, Reynolds J, Chiang MF, Ruben JB, Granet DB, Blocker RJ, Bradford GE, Karr DJ, Lueder GT, Lehman SS, Siatkowski RM. Screening Examination of Premature Infants for Retinopathy of Prematurity. *Pediatrics* 2013;131(1):189-195. <https://PubMed.gov/WOS:000313012400068>. DOI: 10.1542/peds.2012-2996
35. Fierson WM, Ophthalmology AAOPSo, OPHTHALMOLOGY AAO, STRABISMUS AAFPOA, ORTHOPTISTS AAOC. Screening Examination of Premature Infants for Retinopathy of Prematurity. *Pediatrics* 2018;142(6). <https://PubMed.gov/30478242>. DOI: 10.1542/peds.2018-3061
36. Fijalkowski N, Zheng LL, Henderson MT, Wang SK, Wallenstein MB, Leng T, Moshfeghi DM. Stanford University Network for Diagnosis of Retinopathy of Prematurity (SUNDROP): Five Years of Screening With Telemedicine. *Ophthalmic Surgery Lasers & Imaging Retina* 2014;45(2):106-113. <https://PubMed.gov/WOS:000335980800003>. DOI: 10.3928/23258160-20140122-01
37. Schwartz SD, Harrison SA, Ferrone PJ, Trese MT. Telemedical evaluation and management of retinopathy of prematurity using a fiberoptic digital fundus camera. *Ophthalmology* 2000;107(1):25-28. <https://PubMed.gov/WOS:000084724900018>. DOI: 10.1016/s0161-6420(99)00003-2
38. Chiang MF, Keenan JD, Starren J, Du YLE, Schiff WM, Barile GR, Li J, Johnson RA, Hess DJ, Flynn JT. Accuracy and reliability of remote retinopathy of prematurity diagnosis. *Archives of Ophthalmology* 2006;124(3):322-327. <https://PubMed.gov/WOS:000235971300003>. DOI: 10.1001/archophth.124.3.322
39. Chiang MF, Wang L, Busuioc M, Du YE, Chan P, Kane SA, Lee TC, Weissgold DJ, Berrocal AM, Coki O, Flynn JT, Starren J. Telemedical retinopathy of prematurity diagnosis - Accuracy, reliability, and image quality. *Archives of Ophthalmology* 2007;125(11):1531-1538. <https://PubMed.gov/WOS:000250806300011>. DOI: 10.1001/archophth.125.11.1531
40. Multicenter Trial of Cryotherapy for Retinopathy of Prematurity: ophthalmological outcomes at 10 years. *Arch Ophthalmol* 2001;119(8):1110-1118. <https://PubMed.gov/11483076>
41. Effect of retinal ablative therapy for threshold retinopathy of prematurity: results of Goldmann perimetry at the age of 10 years. *Arch Ophthalmol* 2001;119(8):1120-1125. <https://PubMed.gov/11483077>
42. Hunter DG, Repka MX. DIODE-LASER PHOTOCOAGULATION FOR THRESHOLD RETINOPATHY OF PREMATURITY - A RANDOMIZED STUDY. *Ophthalmology* 1993;100(2):238-244. <https://PubMed.gov/WOS:A1993KM01300026>
43. Laser therapy for retinopathy of prematurity. Laser ROP Study Group. *Arch Ophthalmol* 1994;112(2):154-156. <https://PubMed.gov/8311759>
44. Ng EYJ, Connolly BP, McNamara JA, Regillo CD, Vander JF, Tasman W. A comparison of laser photocoagulation with cryotherapy for threshold retinopathy of prematurity at 10 years - Part 1. Visual function and structural outcome. *Ophthalmology* 2002;109(5):928-934. <https://PubMed.gov/WOS:000175474400045>. DOI: 10.1016/s0161-6420(01)01017-x
45. Mintz-Hittner HA, Kennedy KA, Chuang AZ, Grp B-RC. Efficacy of Intravitreal Bevacizumab for Stage 3+Retinopathy of Prematurity. *New England Journal of Medicine* 2011;364(7):603-615. <https://PubMed.gov/WOS:000287406000006>. DOI: 10.1056/NEJMoa1007374

46. Patel RD, Blair MP, Shapiro MJ, Lichtenstein SJ. Significant treatment failure with intravitreal bevacizumab for retinopathy of prematurity. *Arch Ophthalmol* 2012;130(6):801-802. <https://PubMed.gov/22801851>. DOI: 10.1001/archophthalmol.2011.1802
47. Wallace DK, Kraker RT, Freedman SF, Crouch ER, Hutchinson AK, Bhatt AR, Rogers DL, Yang MB, Haider KM, VanderVeen DK, Siatkowski RM, Dean TW, Beck RW, Repka MX, Smith LE, Good WV, Hartnett ME, Kong L, Holmes JM, (PEDIG) PEDIG. Assessment of Lower Doses of Intravitreal Bevacizumab for Retinopathy of Prematurity: A Phase 1 Dosing Study. *JAMA Ophthalmol* 2017;135(6):654-656. <https://PubMed.gov/28448664>. DOI: 10.1001/jamaophthalmol.2017.1055
48. Sankar MJ, Sankar J, Chandra P. Anti-vascular endothelial growth factor (VEGF) drugs for treatment of retinopathy of prematurity. *Cochrane Database Syst Rev* 2018;1:CD009734. <https://PubMed.gov/29308602>. DOI: 10.1002/14651858.CD009734.pub3
49. Shukla A, Sonnie C, Worley S, Sharma A, Howard D, Moore J, Rodriguez RJ, Hoppe G, Sears JE. Comparison of Biphasic vs Static Oxygen Saturation Targets Among Infants With Retinopathy of Prematurity. *JAMA Ophthalmol* 2019;10.1001/jamaophthalmol.2018.7021. <https://PubMed.gov/30763441>. DOI: 10.1001/jamaophthalmol.2018.7021
50. Hoppe G, Yoon S, Gopalan B, Savage AR, Brown R, Case K, VasANJI A, Chan ER, Silver RB, Sears JE. Comparative systems pharmacology of HIF stabilization in the prevention of retinopathy of prematurity. *Proc Natl Acad Sci U S A* 2016;113(18):E2516-2525. <https://PubMed.gov/27091985>. DOI: 10.1073/pnas.1523005113
51. Read SP, Aziz HA, Kuriyan A, Kothari N, Davis JL, Smiddy WE, Flynn HW, Murray TG, Berrocal A. RETINAL DETACHMENT SURGERY IN A PEDIATRIC POPULATION: Visual and Anatomic Outcomes. *Retina* 2018;38(7):1393-1402. <https://PubMed.gov/28858062>. DOI: 10.1097/IAE.0000000000001725
52. Gusson E, Bosello F, Allegrini F, Firolli L, Tomaello I, Marchini G, Micciolo R, Pignatto S, Capone A. Long-Term Anatomic and Visual Outcome Following Vitrectomy for Stage 4B and 5 Retinopathy of Prematurity. *Ophthalmic Surg Lasers Imaging Retina* 2019;50(4):208-214. <https://PubMed.gov/30998241>. DOI: 10.3928/23258160-20190401-02

Suggested citation format:


Mai AP, Scruggs BA, Kemp PS. Retinopathy of Prematurity. EyeRounds.org. Posted June 24, 2019; Available from <https://EyeRounds.org/cases/286-retinopathy-of-prematurity.htm>

last updated: 06/24/2019

Image Permissions:



Ophthalmic Atlas Images by EyeRounds.org, [The University of Iowa](https://www.uniowa.edu) are licensed under a [Creative Commons Attribution-NonCommercial-NoDerivs 3.0 Unported License](https://creativecommons.org/licenses/by-nc-nd/3.0/).



University of Iowa
Roy J. and Lucille A. Carver College of Medicine
Department of Ophthalmology and Visual Sciences
200 Hawkins Drive
Iowa City, IA 52242

Support Us

Copyright © 2019 The University of Iowa. All Rights Reserved
[Report an issue with this page](#)
[Web Privacy Policy](#) | [Nondiscrimination Statement](#)

Follow



[Receive notification of new cases, sign up here](#)

[Contact Us](#)

[Submit a Suggestion](#)