

## Commotio Retinae

**Authors:** Mahsaw Motlagh, MD, David A. Ramirez, MD, Elaine Binkley, MD

### INITIAL PRESENTATION

#### Chief Complaint

Loss of vision after trauma

#### History of Present Illness

A 29-year-old man was referred after sustaining a head injury during an altercation. He lost consciousness during the event, and when he awoke he reported an inability to see out of his left eye. He was evaluated at a local emergency department and was noted to have periorbital ecchymosis in addition to an inferior orbital wall fracture seen on head imaging. He was transferred to the University of Iowa for further evaluation.

#### Past Ocular History

- Refractive error

#### Past Medical History

- Bipolar disorder
- Post-traumatic stress disorder
- Anxiety

#### Medications

- Aripiprazole
- Venlafaxine
- Clonidine
- Hydroxyzine

#### Allergies

- No known drug allergies

#### Family History

- None

#### Social History

- Incarcerated
- Former smoker

## Review of Systems

- Positive for decreased vision, pain with eye movements, photophobia
- Otherwise negative

## OCULAR EXAMINATION

### Visual Acuity

- Right eye (OD): 20/30-2, pinhole 20/20
- Left eye (OS): 20/100+2, pinhole 20/70+2

### Ocular Motility/Alignment

- OD: Full extraocular motility
- OS: -1 limitation in supraduction

### Intraocular Pressure

- OD: 14 mm Hg
- OS: 12 mm Hg

### Pupils

- OD: 2 mm in dark, 1 mm in light, no relative afferent pupillary defect (RAPD)
- OS: 3.5 mm in dark, 3 mm in light, no RAPD by reverse

### Confrontational visual fields

- OD: Full
- OS: Central scotoma

### External

- OD: Normal
- OS: Normal

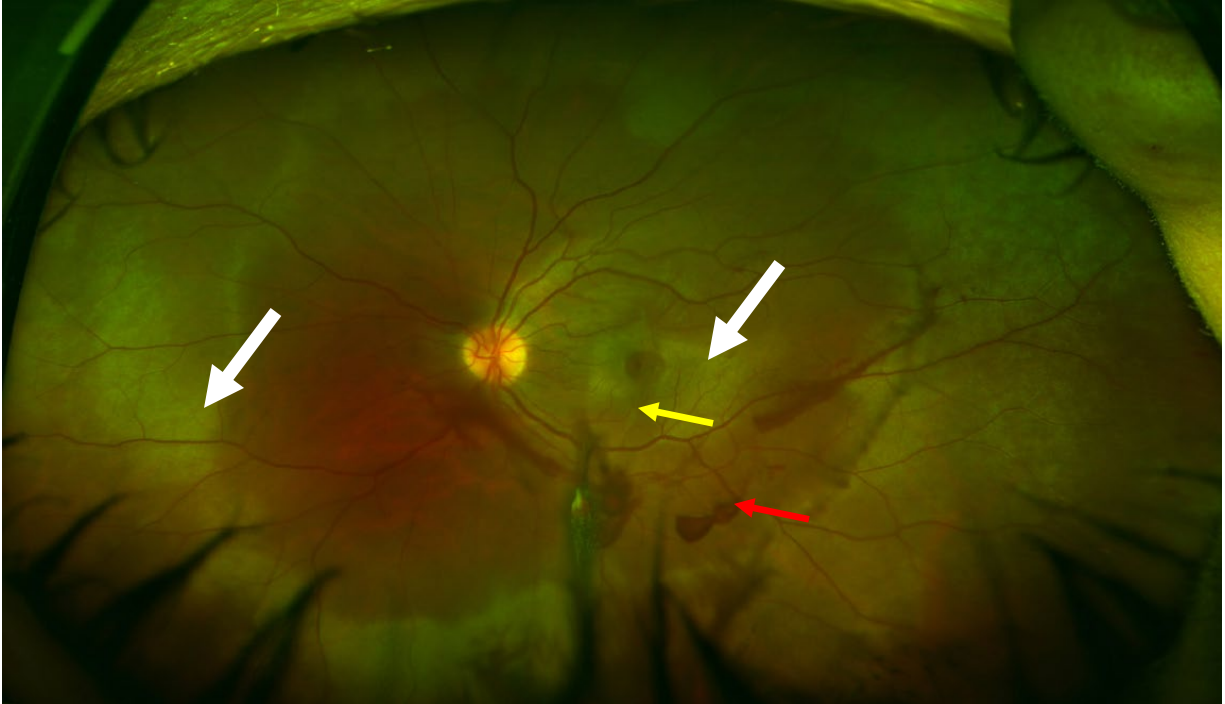
### Slit lamp exam

	OD	OS
Lids/Lashes:	Normal	Ecchymosis and mild edema, mild reactive ptosis, superficial lacerations above left brow and along inferior orbital rim
Conjunctiva/Sclera:	White and quiet	2+ diffuse injection, no abrasions
Cornea:	Clear and quiet	No epithelial defects
Anterior chamber:	Deep and quiet	Deep, 2+ pigmented cell, trace flare, small layered hyphema inferiorly

Iris:	Normal architecture	Normal architecture
Lens:	Clear	Clear, no traumatic cataract

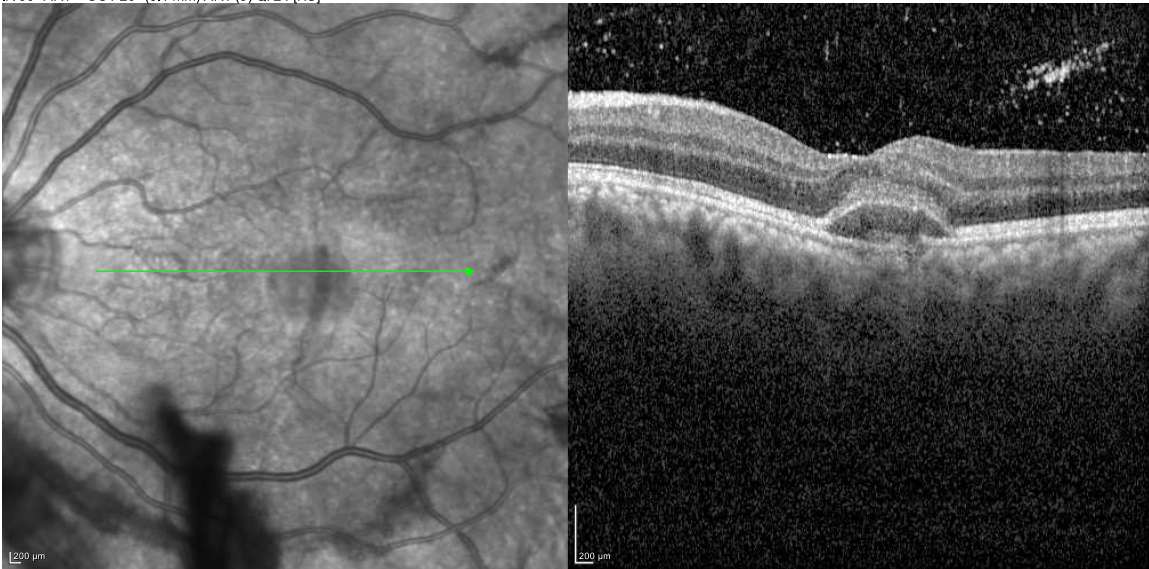
Dilated fundus examination (DFE)

	OD	OS
Vitreous:	Normal	2+ anterior vitreous red blood cells, moderate dispersed vitreous hemorrhage layering inferiorly, no PVD
Disc:	Normal	Normal
Cup-to-disc (C/D) ratio:	0.2	0.2
Macula:	Normal	Commotio with loss of foveal light reflex. Choroidal rupture extending through the fovea
Vessels:	Normal	Pre-retinal hemorrhage along the inferotemporal arcade
Periphery:	Normal	Peripheral commotio most pronounced temporally. Retinal dialysis without associated subretinal fluid from 8:00 clockwise to 11:00 with hemorrhage at the vitreous base. No other retinal breaks



**Figure 1: Color fundus photograph, left eye.** The media are hazy due to vitreous hemorrhage. There is pre-retinal hemorrhage along the arcades (red arrow). There is a choroidal rupture involving the fovea (yellow arrow) with surrounding macular and peripheral commotio (white arrows).

IR 30° ART + OCT 20° (6.1 mm) ART (9) Q: 24 [HS]



**Figure 2: Optical coherence tomography of the macula, left eye.** There is subfoveal, turbid subretinal fluid. There is a break in Bruch's membrane that involves the fovea. Vitreous hyperreflective deposits.

## Differential Diagnosis

- Commotio retinae
- Retinal detachment (<https://webeye.ophth.uiowa.edu/eyeforum/tutorials/retinal-detachment-med-students/index.htm>)
- Retinal dialysis (<https://webeye.ophth.uiowa.edu/eyeforum/cases/272-retinal-dialysis.htm>)
- Macular hole (<https://webeye.ophth.uiowa.edu/eyeforum/cases/261-FTMH.htm>)
- Choroidal rupture (<https://webeye.ophth.uiowa.edu/eyeforum/cases/298-choroidal-rupture.htm>)
- Purtscher retinopathy (<https://webeye.ophth.uiowa.edu/eyeforum/atlas/pages/purtscher/index.htm>)
- Chorioretinitis sclopetaria (<https://webeye.ophth.uiowa.edu/eyeforum/cases/175-Sclopetaria-Chorioretinitis.htm>)
- Central retinal artery occlusion (<https://webeye.ophth.uiowa.edu/eyeforum/atlas/pages/CRAO/index.htm>)

## CLINICAL COURSE

After being seen in the emergency department, the patient was evaluated by the retina service. He was diagnosed with a retinal dialysis, choroidal rupture, vitreous hemorrhage, orbital fractures, hyphema, and commotio retinae in the left eye. He underwent laser barricade of the superonasal retinal dialysis and was started on prednisolone and cyclogyl drops for management of his traumatic iritis and hyphema. His vitreous hemorrhage and hyphema eventually resolved and he was tapered off of topical steroids. The retinal commotio resolved over time; however, his visual acuity remained limited by the injury to the fovea.

DIAGNOSIS: Commotio retinae

## DISCUSSION

### Etiology/Epidemiology

Commotio retinae is defined by an area of retinal whitening or opacification. It was first described by Berlin in 1873 as transient opacification of the retina following blunt trauma to the eye (also known as “Berlin’s edema”) [1]. Commotio retinae is preceded by blunt force or blast ocular trauma that results in a contrecoup injury to the neurosensory retina. It accounts for 0.4% of all civilian eye injuries and 15% of military eye injuries [2,3]. The prevalence of commotio varies and has been reported anywhere from 30% to upwards of 90% in association with ocular trauma [4]. It most commonly occurs in young males [4,5].

Comotio retinae can result from both direct and indirect mechanisms of orbital trauma [6]. Direct blunt ocular trauma results in direct displacement and deformation of the eye. Hydraulic forces can transmit posteriorly and cause direct mechanical disruption of the photoreceptors [7]. Indirect injuries, such as blast trauma, can transmit shockwaves that induce shearing forces. Secondary deformation can also occur as a result of distention of vitreoretinal attachments [8,9].

### Pathophysiology

Berlin initially postulated that areas of retinal opacification or whitening corresponded to regions of extracellular edema in the neurosensory retina [1]. However, this proved controversial in the years that followed as there were some who believed that the underlying mechanism was secondary to intracellular edema [10-14]. Photoreceptor outer segment disruption was another proposed etiology [7]. In both experimental models and *in vivo* studies, the primary injury was found to occur at the level of the photoreceptor outer segments. These regions of outer segment disruption corresponded to the areas of whitening visualized on exam,[7] and were thought to be secondary to increased scattering of light by photoreceptor disruption and disorientation [7,15,16].

There is controversy regarding disruption of the blood-retinal barrier (BRB) in commotio retinae. Studies suggest transient disruption of the BRB shortly after injury. By using horseradish peroxidase (HRP) as a proxy indicator for BRB disruption, HRP leakage was found to occur up to several days after initial injury in animal studies [15,17]. This leakage was found to resolve up to 7 days after injury [17].

Within the first week after trauma, damaged photoreceptor cells will undergo degeneration [10-13,15,16]. In the first forty-eight hours, phagocytic cells from the retinal pigment epithelium (RPE) leave Bruch's membrane and enter the retina to phagocytose damaged photoreceptors [15]. The spaces left behind by these migrating cells are then filled by proliferating, intact RPE cells – clinically, this corresponds to RPE changes and hyperpigmentation that may be present in some patients after resolution of commotio retinae [15]. Histologic studies demonstrate restoration of photoreceptor outer segments that begins within days and can continue for up to several months after initial injury [7].

### Signs/Symptoms

Patients with commotio retinae are typically asymptomatic but may complain of blurry vision, vision loss, a central or paracentral scotoma, or metamorphopsia. Additionally, other signs of trauma may be apparent in the anterior or posterior segment. These include hyphema, iridodialysis, vitreous hemorrhage, choroidal rupture, traumatic macular hole, orbital fracture, or globe rupture. The initial eye exam should therefore be carefully conducted to evaluate for other traumatic sequelae.

The diagnosis of commotio retinae is clinical and relies on funduscopic examination. The classic finding is retinal whitening or opacification that clinically resolves within four to

seven days [7]. Extramacular commotio retinae occur most commonly in an inferotemporal to temporal location [3]. The blood vessels are not disturbed, which is a unique identifier of commotio [1]. The posterior exam may also reveal a “pseudo-cherry red spot.” [5] Patients with severe commotio may have residual RPE changes, RPE atrophy, or hyperpigmentation [7, 15].

#### Testing/Imaging

Optical coherence tomography (OCT) serves as a useful tool in evaluation of commotio retinae. The major site of disruption visualized on OCT occurs at the level of the photoreceptor outer segment and RPE junction, which is consistent with histopathologic changes [18-22]. Transient hyperreflectivity of the outer retina may also be seen at the inner segment/outer segment junction on OCT [23-25]. Certain OCT findings, including foveal thickness at initial presentation and grade of outer retinal atrophy, have been identified as possible predictors of final visual outcome [20].

Multifocal electroretinogram (ERG) is an objective tool that can be used to evaluate retinal function though is seldom used in clinical practice. Similarly, laser speckle flowgraphy has demonstrated choroidal blood flow impairment in patients with commotio [26] but is not routinely indicated in these patients.

#### Treatment/Management/Guidelines

Treatment of commotio retinae is expectant. The majority of patients can expect full recovery with minimal sequelae. However, those with severe commotio or macula-involving injury can experience permanent visual loss or associated scotomata. Even in macula-involving commotio, one study demonstrated that the final visual acuity was better than 20/30 in the majority of patients [3].

There is some evidence that caspase activation is responsible for photoreceptor apoptosis and intravitreal injections of biologic caspase inhibitors may prove to be an effective treatment for patients with severe commotio retinae [27-29]. Fortunately, even without specific treatment the prognosis of commotio retinae is favorable. A recent study proposed prognosticating patients based on OCT analysis of the number of disrupted photoreceptor layers; [30] not surprisingly a higher grade of trauma was associated with greater photoreceptor disruption and worse visual outcome. Recovery can continue for several months and is also objectively demonstrated with return of normal architecture on OCT.



<p><i>EPIDEMIOLOGY OR ETIOLOGY</i></p> <ul style="list-style-type: none"> <li>• Caused by blunt ocular trauma or blast trauma</li> <li>• Accounts for 0.4% of all eye injuries</li> <li>• Most common in young males</li> </ul>	<p><i>SIGNS</i></p> <ul style="list-style-type: none"> <li>• Focal retinal whitening or opacification without disruption of blood vessels</li> <li>• Pseudo-cherry red spot</li> <li>• Other signs of trauma</li> </ul>
<p><i>SYMPTOMS</i></p> <ul style="list-style-type: none"> <li>• Usually asymptomatic</li> <li>• Blurry vision</li> <li>• Vision loss</li> <li>• Scotoma</li> <li>• Metamorphopsia</li> </ul>	<p><i>TREATMENT/MANAGEMENT</i></p> <ul style="list-style-type: none"> <li>• Expectant – resolution within weeks to months</li> </ul>

- Berlin R. Zur sogenannten commotio retinae. *Klin Monatsbl Augenheilkd.* 1873;(11):42-78.
- Weichel ED, Colyer MH, Ludlow SE, Bower KS, Eiseman AS. Combat ocular trauma visual outcomes during operations Iraqi and Enduring Freedom. *Ophthalmology.* 2008. doi:10.1016/j.ophtha.2008.08.033
- Blanch RJ, Good PA, Shah P, Bishop JRB, Logan A, Scott RAH. Visual outcomes after blunt ocular trauma. *Ophthalmology.* 2013. doi:10.1016/j.ophtha.2013.01.009
- Leshno A, Alhalel A, Fogel-Levin M, Zloto O, Moisseiev J, Vidne-Hay O. Pediatric retinal damage due to soccer-ball-related injury: results from the last decade. *Eur J Ophthalmol.* 2019. doi:10.1177/1120672119882332
- Bagheri N, Wajda BN, eds. *The Wills Eye Manual: Office and Emergency Room Diagnosis and Treatment of Eye Disease.* 7th Edition. Wolters Kluwer; 2017.
- Shakin JL, Yannuzzi LA. Posterior segment manifestations of orbital trauma. *Adv Ophthalmic Plast Reconstr Surg.* 1987.
- Mansour AM, Green WR, Hogge C. Histopathology of commotio retinae. *Retina.* 1992. doi:10.1097/00006982-199212010-00006
- Weidenthal DT, Schepens CL. Peripheral fundus changes associated with ocular contusion. *Am J Ophthalmol.* 1966. doi:10.1016/0002-9394(66)91326-2
- Delori F, Pomerantzeff O, Cox MS. Deformation of the globe under high-speed impact: its relation to contusion injuries. *Invest Ophthalmol.* 1969.
- Hart JCD, Blight R. Commotio retinae. *Arch Ophthalmol.* 1979. doi:10.1001/archopht.1979.01020020296025
- Blight R, Dean Hart JC. Histological changes in the internal retinal layers produced by concussive injuries to the globe. An experimental study. *Trans Ophthalmol Soc U K.* 1978.
- Blight R, Dean Hart JC. Structural changes in the outer retinal layers following blunt mechanical non-perforating trauma to the globe: an experimental study. *Br J Ophthalmol.* 1977. doi:10.1136/bjo.61.9.573
- Hart JCD, Blight R, Cooper R, Papakostopoulos D. Electrophysiological and



- pathological investigation of concussion injury: an experimental study. *Trans Ophthalmol Soc U K*. 1975.
14. Kohno T, Ishibashi T, Inomata H, Ikui H, Taniguchi Y. Experimental macular edema of commotio retinae: preliminary report. *Jpn J Ophthalmol*. 1983.
  15. Sipperley JO, Quigley HA, Gass JDM. Traumatic retinopathy in primates: the explanation of commotio retinae. *Arch Ophthalmol*. 1978. doi:10.1001/archopht.1978.03910060563021
  16. Liem ATA, Keunen JEE, Norren D Van. Reversible cone photoreceptor injury in commotio retinae of the macula. *Retina*. 1995. doi:10.1097/00006982-199515010-00011
  17. Gregor Z, Ryan SJ. Blood-retinal barrier after blunt trauma to the eye. *Graefe's Arch Clin Exp Ophthalmol*. 1982. doi:10.1007/BF00231236
  18. Meyer CH, Rodrigues EB, Mennel S. Acute commotio retinae determined by cross-sectional optical coherence tomography. *Eur J Ophthalmol*. 2003. doi:10.1177/1120672103013009-1017
  19. Mansour AM, Shields CL. Microvascular capillary plexus findings of commotio retinae on optical coherence tomography angiography. *Case Rep Ophthalmol*. 2018. doi:10.1159/000494916
  20. Chen H, Lu Y, Huang H, Zheng J, Hou P, Chen W. Prediction of visual prognosis with spectral-domain optical coherence tomography in outer retinal atrophy secondary to closed globe trauma. *Retina*. 2013. doi:10.1097/IAE.0b013e31827b63ba
  21. Sony P, Venkatesh P, Gadaginamath S, Garg SP. Optical coherence tomography findings in commotio retina. *Clin Exp Ophthalmol*. 2006. doi:10.1111/j.1442-9071.2006.01290.x
  22. Ismail R. Optical coherence tomography imaging of severe commotio retinae and associated macular hole. *Br J Ophthalmol*. 2002. doi:10.1136/bjo.86.4.473-a
  23. Itakura H, Kishi S. Restored photoreceptor outer segment in commotio retinae. *Ophthalmic Surg Lasers Imaging*. 2011. doi:10.3928/15428877-20110224-03
  24. Oh J, Jung JH, Moon SW, Song SJ, Yu HG, Cho HY. Commotio retinae with spectral-domain optical coherence tomography. *Retina*. 2011. doi:10.1097/IAE.0b013e31820f4bb4
  25. Souza-Santos F, Lavinsky D, Moraes NS, Castro AR, Cardillo JA, Farah ME. Spectral-domain optical coherence tomography in patients with commotio retinae. *Retina*. 2012. doi:10.1097/IAE.0b013e318227fd01
  26. Hashimoto R, Hirota A, Maeno T. Choroidal blood flow impairment demonstrated using laser speckle flowgraphy in a case of commotio retinae. *Am J Ophthalmol Case Reports*. 2016. doi:10.1016/j.ajoc.2016.08.002
  27. Blanch RJ, Ahmed Z, Thompson AR, *et al*. Caspase-9 mediates photoreceptor death after blunt ocular trauma. *Investig Ophthalmol Vis Sci*. 2014. doi:10.1167/iovs.13-13708
  28. Thomas CN, Berry M, Logan A, Blanch RJ, Ahmed Z. Caspases in retinal ganglion cell death and axon regeneration. *Cell Death Discov*. 2017. doi:10.1038/cddiscovery.2017.32
  29. Thomas CN, Thompson AM, McCance E, *et al*. Caspase-2 mediates site-specific retinal ganglion cell death after blunt ocular injury. *Investig Ophthalmol Vis Sci*.

2018. doi:10.1167/iovs.18-24045
30. Ahn SJ, Woo SJ, Kim KE, Jo DH, Ahn J, Park KH. Optical coherence tomography morphologic grading of macular commotio retinae and its association with anatomic and visual outcomes. *Am J Ophthalmol.* 2013. doi:10.1016/j.ajo.2013.06.023