

Intermediate uveitis associated with hidradenitis suppurativa

Mahsaw Mansoor, MD; Ryan J. Diel, MD; Michael D. Abramoff, MD, PhD

August 25, 2022



INITIAL PRESENTATION

Chief Complaint: Worsening floaters in the left eye

History of Present Illness:

A 40-year-old male was referred to the University of Iowa for worsening floaters in his left eye starting two months prior to presentation. Additionally, he reported a subjective decrease in visual acuity in his left eye during this time period. He otherwise denied flashes of light and eye pain, and denied symptoms in the right eye. His review of systems was significant for diffuse, scattered inflammatory skin nodules consistent with a known diagnosis of hidradenitis suppurativa (HS) managed with oral doxycycline.

Past Ocular History: None

Past Medical History:

- Type 2 diabetes mellitus
- Hidradenitis suppurativa

Medications: Doxycycline 50 mg once daily

Allergies: None

Family History: Non-contributory to current presentation

Social History: Denied tobacco and ethanol use

Review of Systems: As per noted in HPI, otherwise negative.

OCULAR EXAMINATION

- Visual Acuity with correction:
 - Right eye (OD): 20/20
 - Left eye (OS): 20/40, no improvement with pinhole
- Ocular Motility:
 - Both eyes (OU): Full
- Intraocular Pressure (IOP):
 - OD: 14 mmHg by Tonopen
 - OS: 16 mmHg by Tonopen
- Pupils:
 - OD: 6 mm in dark, 3 mm in light, no relative afferent pupillary defect (RAPD)
 - OS: 6 mm in dark, 3 mm in light, no RAPD
- Confrontation Visual Fields:

- OD: Full to finger counting
- OS: Full to finger counting
- External:
 - OU: Normal
- Slit Lamp Exam:
 - Lid/Lashes: Normal OU
 - Conjunctiva/Sclera: Clear and quiet OU
 - Cornea: Clear OU
 - Anterior Chamber: Deep and quiet OU
 - Iris: Normal architecture OU
 - Lens: Clear OU
 - Vitreous: Normal OU
- Dilated Fundus Examination (DFE):

	Left Eye	Right Eye
Vitreous	Clear, no cell or flare	2+ anterior vitreous cells, trace flare, inferior vitreous snowballs
Disc	Normal	Normal
Cup-to-disc ration	0.2	0.2
Macula	Normal	2-3+ cystoid macular edema
Vessels	Normal, no vascular sheathing	Normal, no vascular sheathing
Periphery	Normal	Normal

Table 1. Dilated Fundus Examination (DFE)

IMAGING

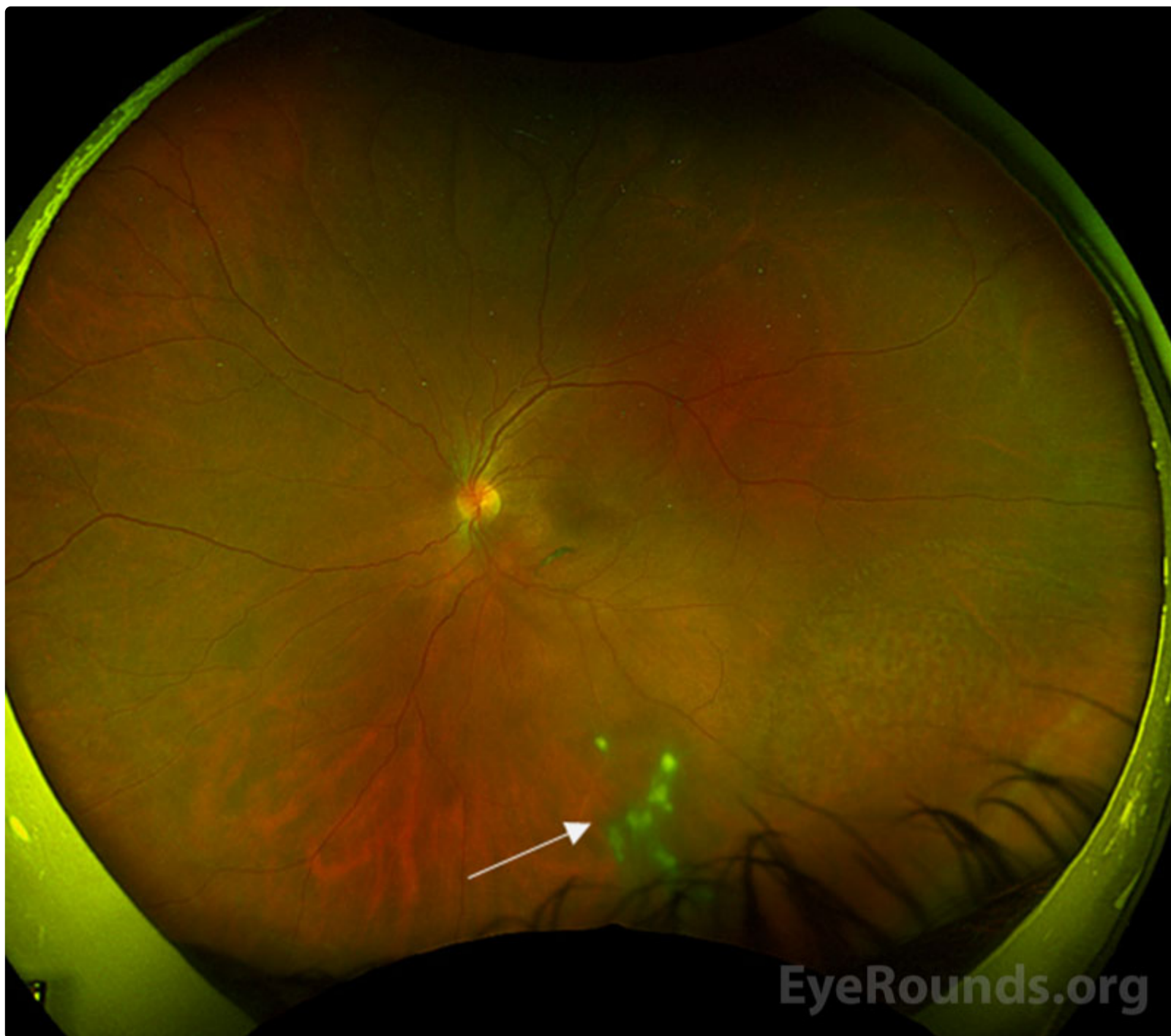

Figure 1: Color Fundus Photography. Color fundus photography of the left eye at presentation demonstrating vitreous cell and floaters with snowballs inferiorly (arrow).

[Enlarge](#) [Download](#)

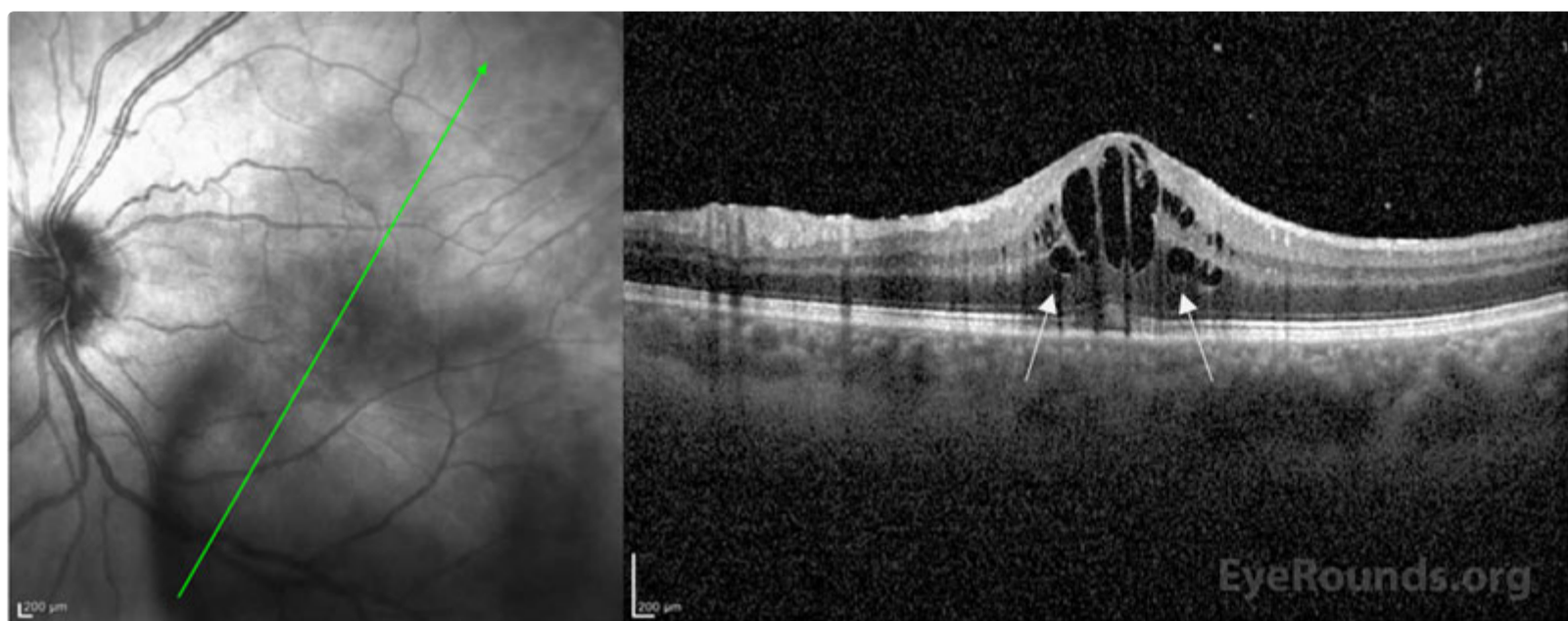


Figure 2: Optical Coherence Tomography (OCT). Optical coherence tomography of the left eye at presentation demonstrating well-defined cystic fluid pockets (white arrows) within the outer nuclear/outer plexiform layers and the inner nuclear layer.

[Enlarge](#) [Download](#)

Differential Diagnosis:

- Pars planitis
- [Sarcoidosis](#)

- Lyme disease
- Multiple sclerosis
- Syphilis
- [Peripheral toxocariasis](#)
- [Tuberculosis](#)
- Human T-cell lymphotropic virus type 1 (HTLV-1)

DIAGNOSIS: Intermediate Uveitis Associated With Hidradenitis Suppurativa

CLINICAL COURSE

Given that intermediate uveitis has a broad differential, a comprehensive work-up was obtained. A complete metabolic panel, complete blood cell count with differential, serum erythrocyte sedimentation rate, serum C-reactive protein, rheumatoid factor, antinuclear antibody testing, anti-neutrophil cytoplasmic antibody testing, angiotensin-converting enzyme level, Lyme antibody, QuantiFERON gold testing for tuberculosis, and syphilis antibody testing were all negative or normal. While pars planitis was considered as a diagnosis, this is a diagnosis of exclusion. In this case, however, the intraocular inflammation was linked to the patient's known history of hidradenitis suppurativa. He was treated with difluprednate 0.05% four times daily in the left eye and monitored with serial imaging. Co-management with dermatology was required to ensure appropriate systemic treatment for his underlying disease. In this case, oral doxycycline was used. Ultimately his visual acuity returned to 20/20 in both eyes with resolution of cystoid macular edema and intermediate uveitis. Fluorescein angiography was obtained post-treatment and ensured resolution of petaloid macular leakage. The patient's treatment course was complicated by steroid response ocular hypertension, which was treated with dorzolamide/timolol twice daily. He was eventually transitioned to prednisolone acetate 1% and tapered to once daily treatment of the left eye with continued quiescence of his ocular inflammation.

This case highlights the importance of considering HS in association with inflammatory eye disease and of performing a thorough review of systems in all patients presenting with ocular inflammation. [1,2] Furthermore, the presence of inflammatory eye disease may be indicative of uncontrolled systemic disease that may require treatment escalation; therefore a careful systemic review of systems is critical for these patients. [2]

DISCUSSION

Etiology/Epidemiology

Intermediate uveitis represents a type of uveitis in which the primary site of inflammation is the vitreous. [3] Specifically, intermediate uveitis includes pars planitis, posterior cyclitis, and hyalitis. Given the ambiguity of these terms, however, the International Uveitis Study Group (IUSG) reserves the diagnostic term pars planitis for the subset of intermediate uveitis that occurs in the absence of an identifiable cause (ie, infection or associated disease). [3] Intermediate uveitis is the least common form of uveitis. It represents about 15% of all uveitides based on previous surveys performed worldwide. [4, 5] Intermediate uveitis is described primarily as a disease of young adults, and most commonly occurs in patients under the age of 40 years. [6] It does not have gender, racial, or ethnic predilection. [5, 6] The majority of intermediate uveitis cases have bilateral involvement. [5] Systemic associations are reported in up to 30% of patients and varies with population studied. [10] Of the systemic associations, sarcoidosis and multiple sclerosis are most commonly identified and reported. [10]

Hidradenitis suppurativa (HS) is a chronic, recurrent inflammatory skin disease preferentially affecting the intertriginous skin and epidermis-containing apocrine glands. [11, 12] The condition manifests as painful nodules in intertriginous areas that can progress to abscesses, fistulae, and sinus tracts. These characteristic lesions may rupture and form scars. Globally, the prevalence of HS is estimated to range from 0.05% to 4.10%, although the exact prevalence is unknown. [11] Depression, anxiety, pain, and high body mass index are highly correlated with HS due to its profound negative effect on quality of life measures. [13, 14]

Pathophysiology

The exact underlying pathogenic mechanisms of intermediate uveitis are not well understood. The common effector mechanisms identified in experimental models implicate the release of major cytokines IL-17 and IFN- γ via a T cell-mediated pathway. [15] There are some associations between human leukocyte antigens (HLA) haplotypes, specifically HLA-DR15, HLA-DR51, and HLA-DR17, that may suggest an immunogenetic predisposition. [4, 9]

In terms of HS, the exact underlying pathogenesis also remains unknown but is postulated to include a combination of genetic predisposition and environmental triggers that predispose to epithelial fragility. [14] The primary cytokines identified in this inflammatory process are TNF-alpha and IL-17. [14] These cytokines are also well established in the pathogenesis of inflammatory eye disease. Despite this plausible link, few reports exist identifying the prevalence of inflammatory eye disease in patients with HS. In the largest retrospective cohort to date, only one of 236 patients had intermediate uveitis associated with HS. [1]

Signs/Symptoms:

Patients typically present with blurry vision or new floaters. Sudden vision loss may occur secondary to exudative or rhegmatogenous retinal detachment. Though many cases are bilateral at presentation, symptom severity tends to be asymmetric.

A diagnosis of intermediate uveitis requires the presence of pars plana exudates (“snowbanks”) or accumulation of fibroinflammatory debris in the inferior vitreous (“snowballs”), but can also be associated with other clinical findings of ocular inflammation (see Table 1). [3] Floaters reported by patients are the result of the shadows cast by vitreous cells and debris on the retina.

	Clinical manifestations of Intermediate Uveitis
Required findings	<ul style="list-style-type: none"> ◦ Pars plana exudates ("snowbanks") <p>OR</p> <ul style="list-style-type: none"> ◦ Accumulation of fibroinflammatory debris in the inferior vitreous
Possible associated findings	<ul style="list-style-type: none"> ◦ Anterior chamber reaction (anterior chamber inflammation must be less than vitreous humor) ◦ Nonsenile cataract ◦ Retrolental membrane formation ◦ Vitreous haze ◦ Vascular sheathing or retinal phlebitis ◦ Macular edema ◦ Epiretinal membrane ◦ Retinal detachment <p>></p>

Table 1. Summary of Clinical Manifestations of Intermediate Uveitis

Laboratory work-up:

In an individual presenting with intermediate uveitis, a broad infectious and inflammatory work up must be completed. If a comprehensive work-up is normal or negative, then a diagnosis of pars planitis should be considered. The initial work-up is guided by clinical suspicion but should include basic inflammatory and infectious tests to rule out commonly missed diseases such as syphilis and tuberculosis (see Table 2).

In children, care should be taken to differentiate intermediate uveitis from other forms of chronic uveitis such as juvenile idiopathic arthritis. [18] Another important association for the clinician to bear in mind is the strong association between intermediate uveitis and multiple sclerosis (MS) in patients of all ages. [19] If there are signs or symptoms suggestive of multiple sclerosis, evaluation with magnetic resonance imaging (MRI) of the brain with possible cerebrospinal fluid analysis should be considered.

Imaging:

Imaging is not required for the diagnosis of intermediate uveitis but can provide helpful adjunctive information and for tracking disease progression (see Table 2).

Laboratory testing	<ul style="list-style-type: none"> ◦ Basic metabolic panel (BMP) ◦ Complete blood cell count with differential (CBC) ◦ Serum erythrocyte sedimentation rate (ESR) ◦ Serum C-reactive protein (CRP) ◦ Rheumatoid factor (RF) ◦ Antinuclear antibody testing (ANA) ◦ Anti-neutrophil cytoplasmic antibody testing (ANCA) ◦ Angiotensin-converting enzyme level (ACE-1) ◦ Lyme antibody ◦ QuantiFERON gold testing for tuberculosis ◦ Syphilis antibody testing
Imaging	<ul style="list-style-type: none"> ◦ Digital fundus photography: document baseline appearance and assess progression ◦ Fluorescein angiography (FA): assess for cystoid macular edema and examine the retinal vasculature for signs of vasculitis and neovascularization ◦ Optical coherence tomography (OCT): evaluate retinal layers, detection and appearance of cystoid macular edema, and evaluation of late complications such as epiretinal membranes, retinal atrophy, or macular hole ◦ Ocular B-mode ultrasound: evaluation and monitoring of vitreous inflammation or hemorrhage ◦ Ultrasound biomicroscopy (UBM): evaluation of the ciliary body and pars plana ◦ MRI brain/orbits: evaluation for multiple sclerosis

Table 2. Summary of common ancillary workup studies. Workup should be guided by clinical suspicion based on the patient’s history and exam findings.

Treatment & Management:

Patients with intermediate uveitis typically have a long treatment course often complicated by relapsing and remitting disease. Treatment options vary based on severity of intraocular inflammation and individual practice, but include consideration of topical steroids, local injections of corticosteroids, intravitreal injection of corticosteroids, oral steroids, and systemic immunomodulatory therapy. [10] Despite the long disease course and frequent complications of intermediate uveitis, the visual prognosis remains favorable with a recent cross-sectional study reporting a median 10-year visual acuity of 20/30. [10] The most frequent cause of vision loss in patients with intermediate uveitis is cystoid macular edema (CME). [20] Other less common complications include vitreous hemorrhage, epiretinal membrane, and development of ocular hypertension/uveitic glaucoma. [21]

In the setting of systemic disease, the patient may benefit from multi-disciplinary management as in this case.

EPIDEMIOLOGY & ETIOLOGY <ul style="list-style-type: none"> ◦ Represents about 15% of all uveitides ◦ Young adults predominantly affected age groups ◦ No gender or racial predilection 	SIGNS <ul style="list-style-type: none"> ◦ Typically bilateral, asymmetric involvement ◦ “Snowbanks” – exudates in the pars plana or peripheral retina ◦ “Snowballs” – accumulation of inflammatory debris in inferior vitreous ◦ Cystoid macular edema, vascular sheathing, retinal detachment
--	--

SYMPTOMS

- Decreased visual acuity
- New or worsening floaters
- Rarely: pain, photophobia, and red eye

TREATMENT

- Topical, peri-ocular, regional, intravitreal or systemic steroids
- Steroid-sparing agents such as methotrexate
- Biologic agents such as adalimumab

References

1. Lee DJ, Desai S, Laurent E, Kopplin LJ. Characterization and Management of Inflammatory Eye Disease in Patients with Hidradenitis Suppurativa. *Ocul Immunol Inflamm*. 2020 Apr 7:1-6.
2. Saygin D, Syed AU, Lowder CY, Srivastava S, Maya JJ, Hajj-Ali RA. Characteristics of inflammatory eye disease associated with hidradenitis suppurativa. *Eur J Rheumatol*. 2018 Sep;5(3):165-8.
3. Jabs DA, Nussenblatt RB, Rosenbaum JT. Standardization of uveitis nomenclature for reporting clinical data. Results of the First International Workshop. *Am J Ophthalmol*. 2005 Sep;140(3):509-16.
4. Tsirouki T, Dastiridou A, Symeonidis C, Tounakaki O, Brazitikou I, Kalogeropoulos C, et al. A Focus on the Epidemiology of Uveitis. *Ocul Immunol Inflamm*. 2018;26(1):2-16.
5. Classification Criteria for Intermediate Uveitis, Non-Pars Planitis Type. *Am J Ophthalmol*. 2021 Aug;228:159-64.
6. Bonfioli AA, Damico FM, Curi AL, Orefice F. Intermediate uveitis. *Semin Ophthalmol*. 2005 Jul-Sep;20(3):147-54.
7. Schepens CL, Bahn GC. Examination of the ora serrata. Its importance in retinal detachment. *AMA Arch Ophthalmol*. 1950 Nov;44(5):677-90.
8. Donaldson MJ, Pulido JS, Herman DC, Diehl N, Hodge D. Pars planitis: a 20-year study of incidence, clinical features, and outcomes. *Am J Ophthalmol*. 2007 Dec;144(6):812-7.
9. Ozdal PC, Berker N, Tugal-Tutkun I. Pars Planitis: Epidemiology, Clinical Characteristics, Management and Visual Prognosis. *J Ophthalmic Vis Res*. 2015 Oct-Dec;10(4):469-80.
10. Niederer RL, Sharief L, Bar A, Lightman SL, Tomkins-Netzer O. Predictors of Long-Term Visual Outcome in Intermediate Uveitis. *Ophthalmology*. 2017 Mar;124(3):393-8.
11. Sabat R, Jemec GBE, Matusiak L, Kimball AB, Prens E, Wolk K. Hidradenitis suppurativa. *Nat Rev Dis Primers*. 2020 Mar 12;6(1):18.
12. Jemec GB. Clinical practice. Hidradenitis suppurativa. *N Engl J Med*. 2012 Jan 12;366(2):158-64.
13. Tiri H, Jokelainen J, Timonen M, Tasanen K, Huilaja L. Somatic and psychiatric comorbidities of hidradenitis suppurativa in children and adolescents. *J Am Acad Dermatol*. 2018 Sep;79(3):514-9.
14. Goldberg SR, Strober BE, Payette MJ. Hidradenitis suppurativa: Epidemiology, clinical presentation, and pathogenesis. *J Am Acad Dermatol*. 2020 May;82(5):1045-58.
15. Abraham A, Nicholson L, Dick A, Rice C, Atan D. Intermediate uveitis associated with MS: Diagnosis, clinical features, pathogenic mechanisms, and recommendations for management. *Neurol Neuroimmunol Neuroinflamm*. 2021 Jan;8(1).
16. Pederson JE, Kenyon KR, Green WR, Maumenee AE. Pathology of pars planitis. *Am J Ophthalmol*. 1978 Dec;86(6):762-74.
17. Classification Criteria For Pars Planitis. *Am J Ophthalmol*. 2021 Aug;228:268-74.
18. AlBloushi AF, Solebo AL, Gokhale E, Hayouti H, Ajamil-Rodanes S, Petrushkin H. Long-Term Outcomes of Pediatric Idiopathic Intermediate Uveitis. *Am J Ophthalmol*. 2021 Nov 13;237:41-8.
19. Malinowski SM, Pulido JS, Folk JC. Long-term visual outcome and complications associated with pars planitis. *Ophthalmology*. 1993 Jun;100(6):818-24; discussion 25.
20. Deane JS, Rosenthal AR. Course and complications of intermediate uveitis. *Acta Ophthalmol Scand*. 1997 Feb;75(1):82-4.
21. Sancho L, Kramer M, Koriati A, Eiger-Moscovich M, Sharon Y, Amer R. Complications in Intermediate Uveitis: Prevalence, Time of Onset, and Effects on Vision in Short-Term and Long-Term Follow-Up. *Ocul Immunol Inflamm*. 2019;27(3):447-55.
22. Ozdemir HB, Ozdal PC. Clinical characteristics and treatment of pars planitis: an adalimumab experience. *Graefes Arch Clin Exp Ophthalmol*. 2022 Feb;260(2):561-9.
23. Sohn EH, Chaon BC, Jabs DA, Folk JC. Peripheral Cryoablation for Treatment of Active Pars Planitis: Long-Term Outcomes of a Retrospective Study. *Am J Ophthalmol*. 2016 Feb;162:35-42.e2.

Suggested citation format:

Mansoor M, Diel RJ, Abramoff MD. Intermediate uveitis associated with hidradenitis suppurativa. EyeRounds.org. August 25, 2022. Available from <https://EyeRounds.org/cases/328-hidradenitis-suppurativa.htm>

Image Permissions:



Ophthalmic Atlas Images by EyeRounds.org, [The University of Iowa](https://www.uniowa.edu) are licensed under a [Creative Commons Attribution-NonCommercial-NoDerivs 3.0 Unported License](https://creativecommons.org/licenses/by-nc-nd/3.0/).

Address

University of Iowa
Roy J. and Lucille A. Carver College
of Medicine
Department of Ophthalmology and
Visual Sciences
200 Hawkins Drive
Iowa City, IA 52242

[Support Us](#)

Legal

Copyright © 2019 The University of
Iowa. All Rights Reserved
[Report an issue with this page](#)
[Web Privacy Policy](#) |
[Nondiscrimination Statement](#)

Related Links

[Cataract Surgery for Greenhorns](#)
[EyeTransillumination](#)
[Gonioscopy.org](#)
[Iowa Glaucoma Curriculum](#)
[Iowa Wet Lab](#)
[Patient Information](#)
[Stone Rounds](#)
[The Best Hits Bookshelf](#)

EyeRounds Social Media

Follow



Receive notification of new cases,
[sign up here](#)
[Contact Us](#)
[Submit a Suggestion](#)