

# EyeRounds.org

## Cornea verticillata

**Category(ies):** Cornea

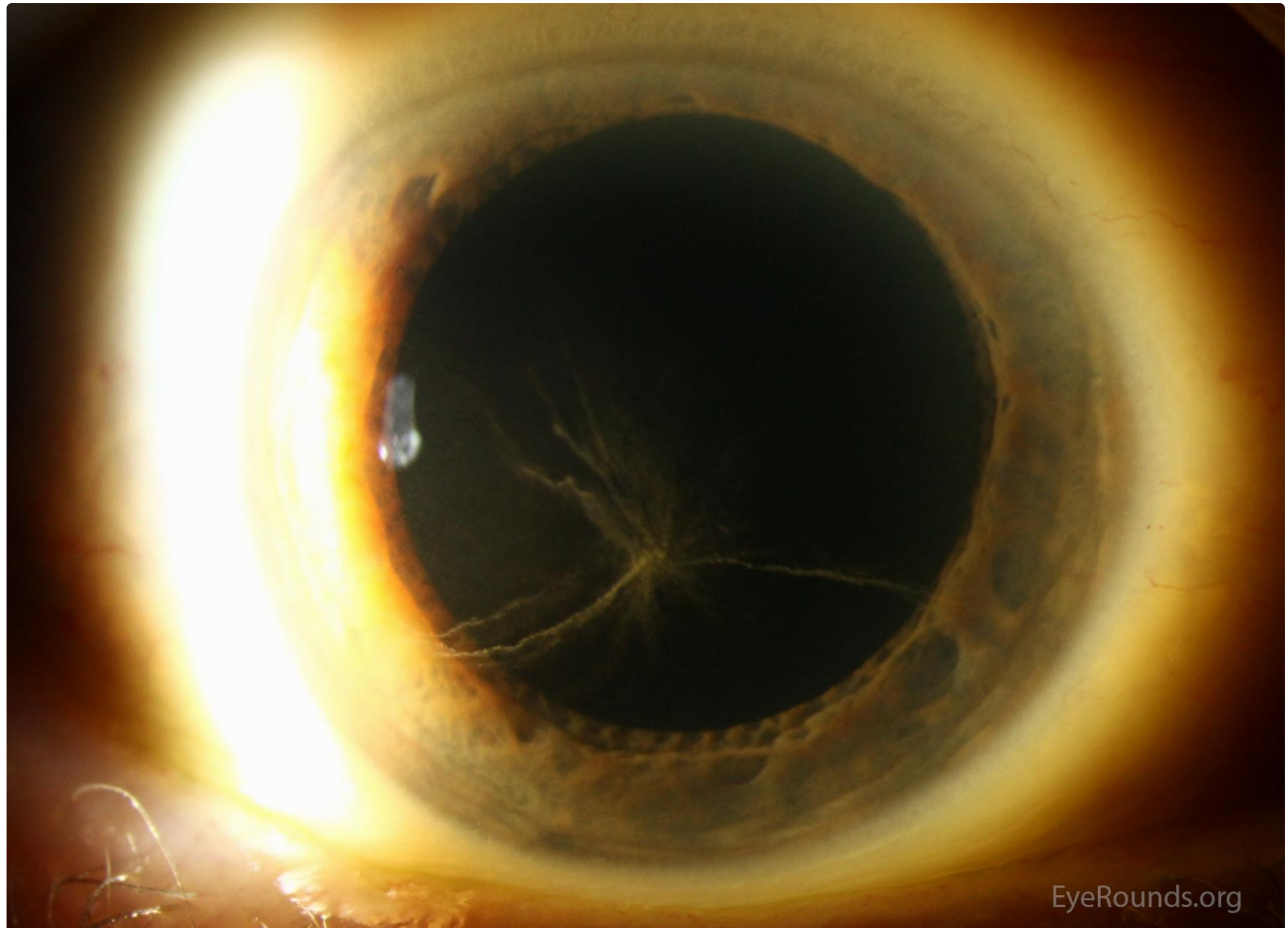
**Contributor:** [Jesse Vislisel, MD](#)

Cornea verticillata, also known as vortex keratopathy, describes a pattern of whorl- shaped opacities within the basal corneal epithelium. They are most commonly located in the inferior paracentral region, are non-elevated, and can range from white to brown in color. These changes are usually not visually significant. Cornea verticillata is often caused by the use of certain systemic medications, the most common of which include amiodarone, chloroquine, hydroxychloroquine, indomethacin, and phenothiazines. Cornea verticillata can also be seen in the sphingolipidosis, [Fabry disease](#).

## Figure 1

**Contributor:** [Jesse Vislisel, MD](#)

**Photographer:** Brice Critser, CRA

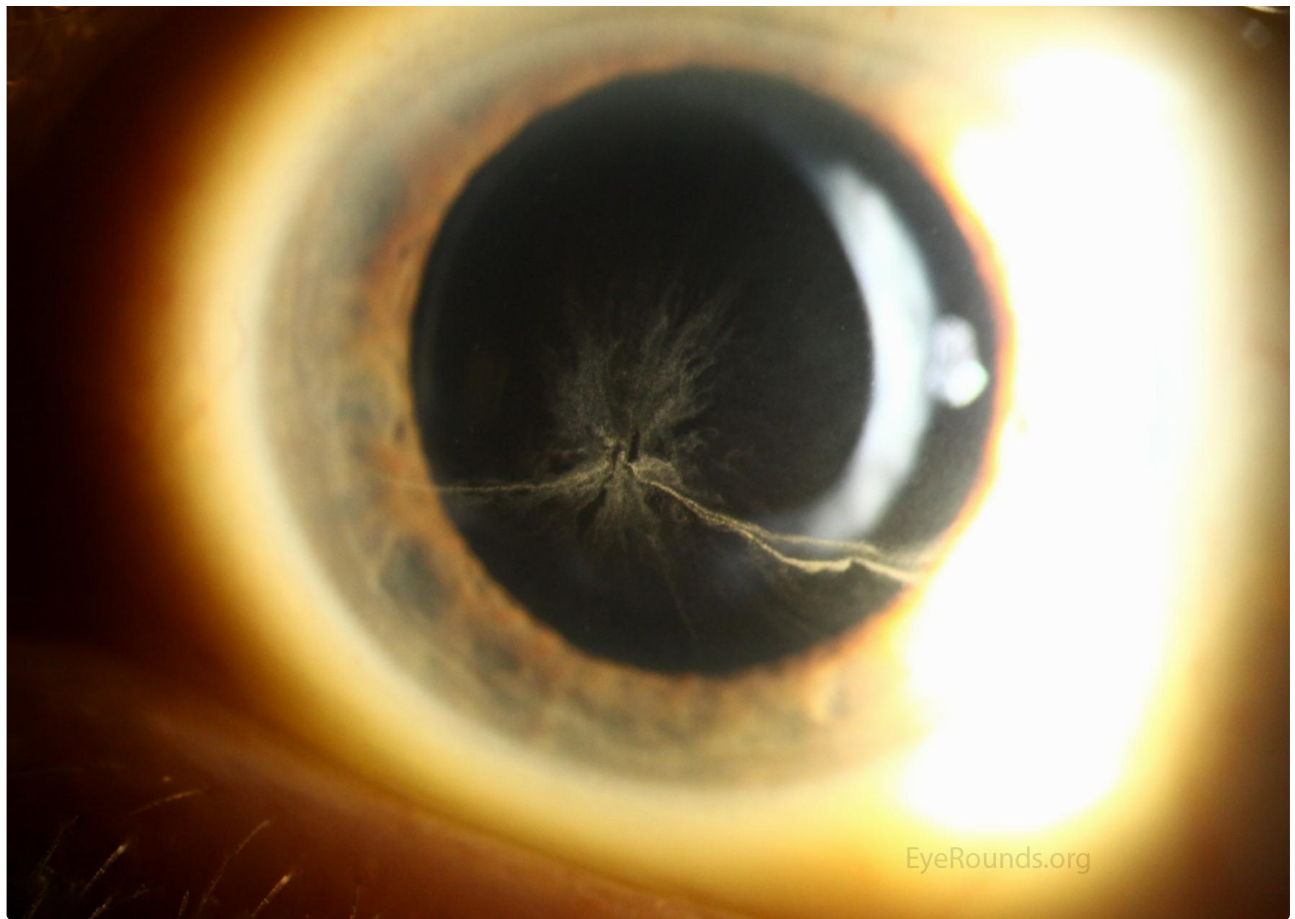


Right Eye

 Enlarge

 Download

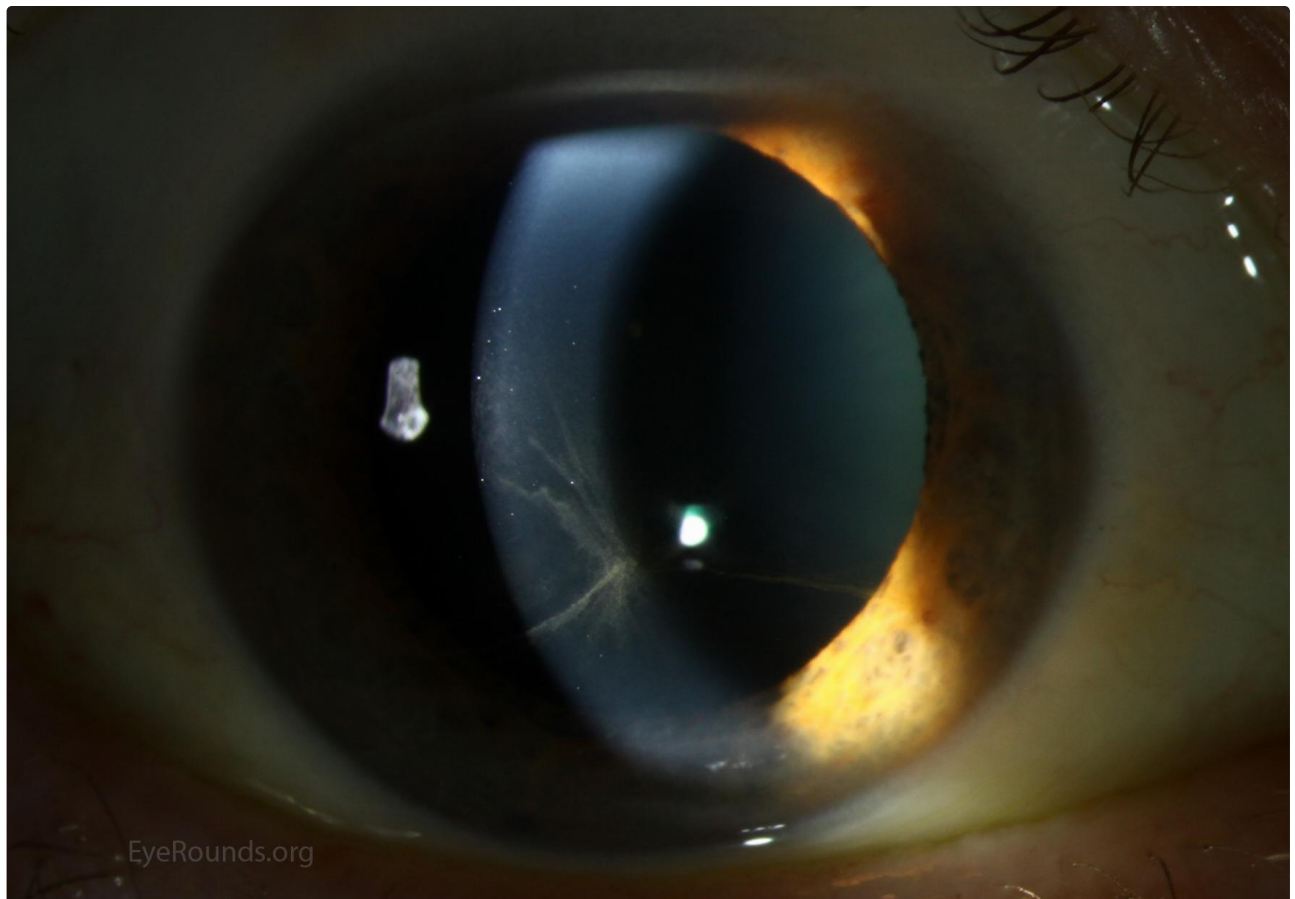




Left Eye

[Enlarge](#)

[Download](#)

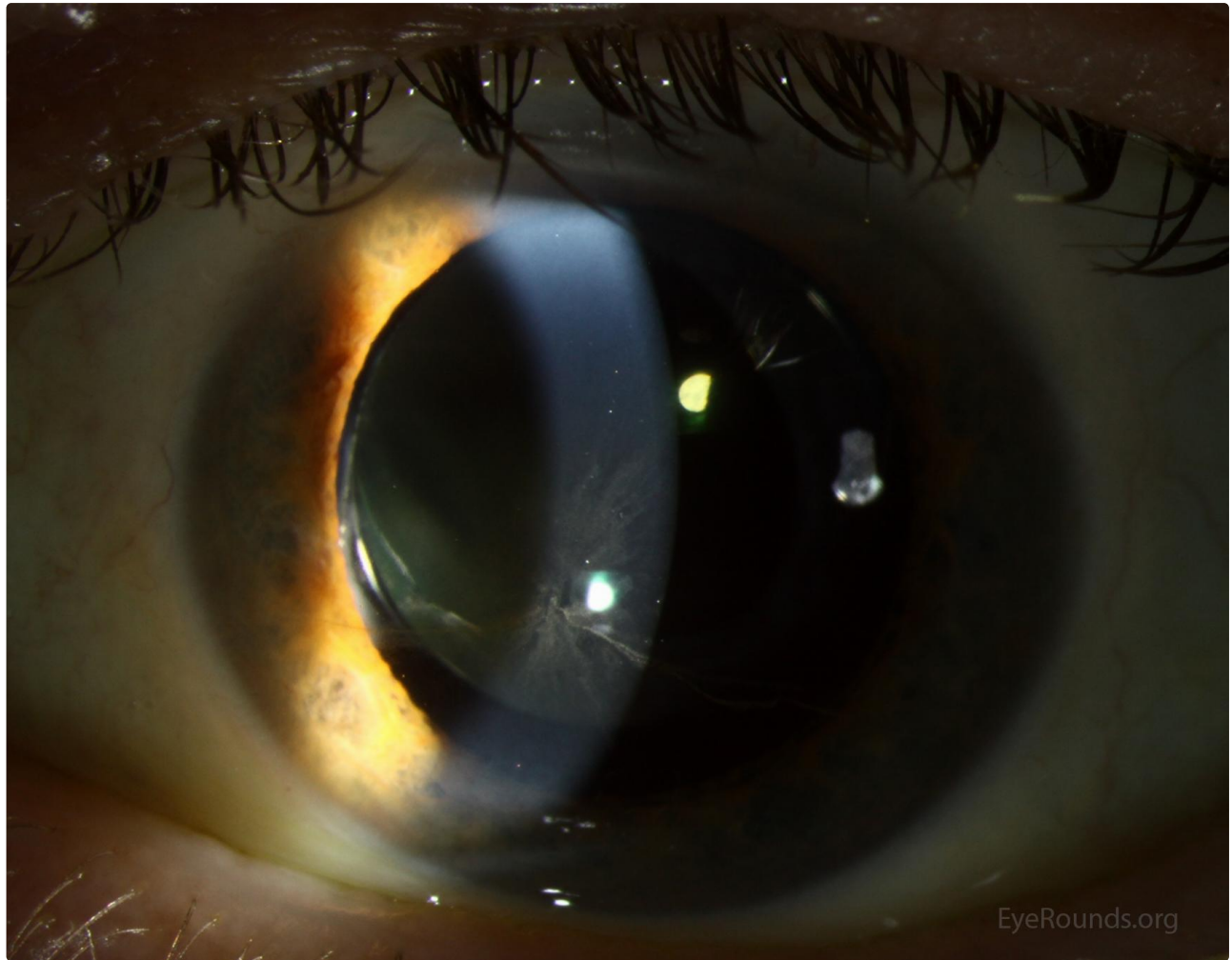


Right Eye

Right Eye

[Enlarge](#)

[Download](#)



Left Eye

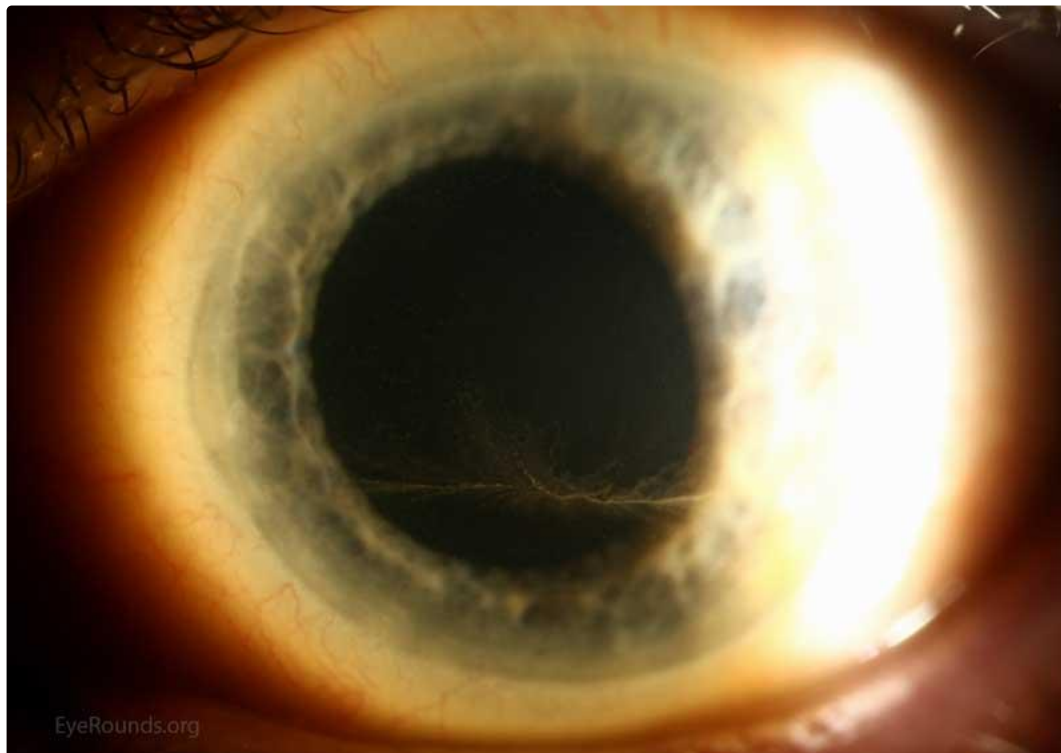
[Enlarge](#)

[Download](#)

## Figure 2

Contributor: [Jesse Vislisel, MD](#); W.L.M. Alward, MD

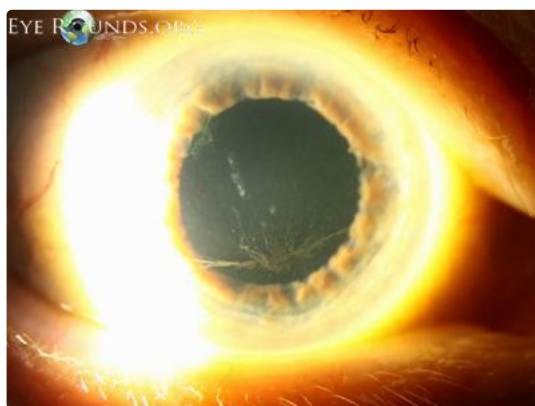
Photographer: Brice Critser, CRA



Cornea verticillata in a another patient taking amiodarone

[Enlarge](#)

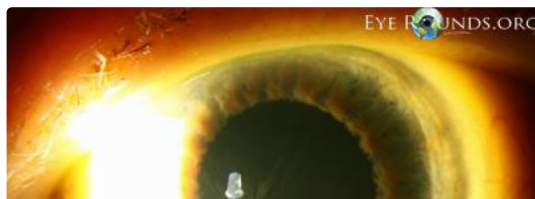
[Download](#)

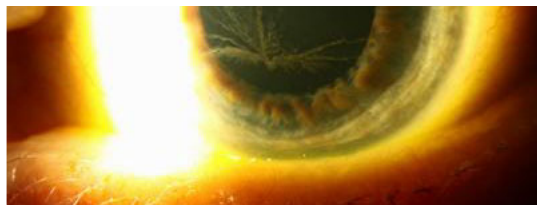

right eye

[Enlarge](#)

[Download](#)





left eye

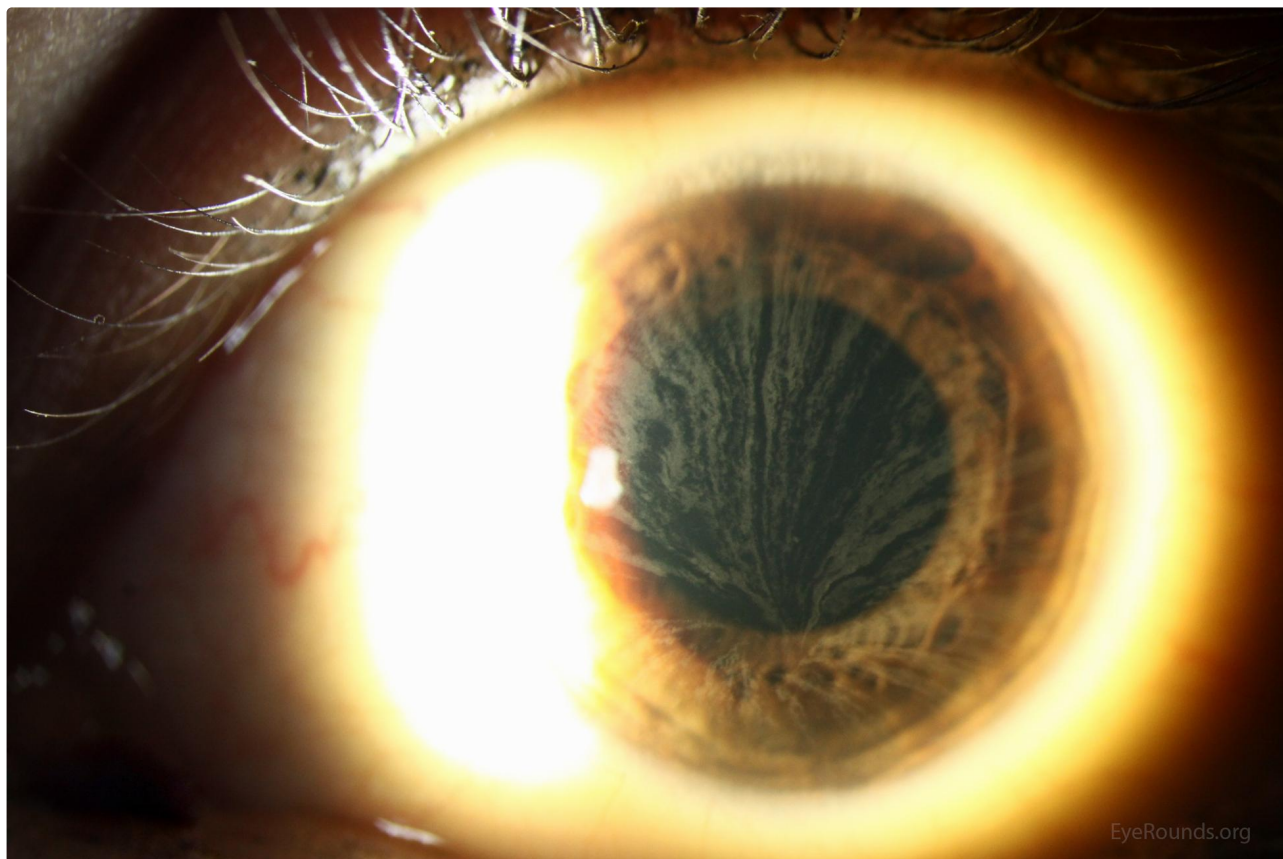
[Enlarge](#)

[Download](#)

## Figure 3

Contributor: [Jesse Vislisel, MD](#)

Photographer: Cindy Montague, CRA



[Enlarge](#)

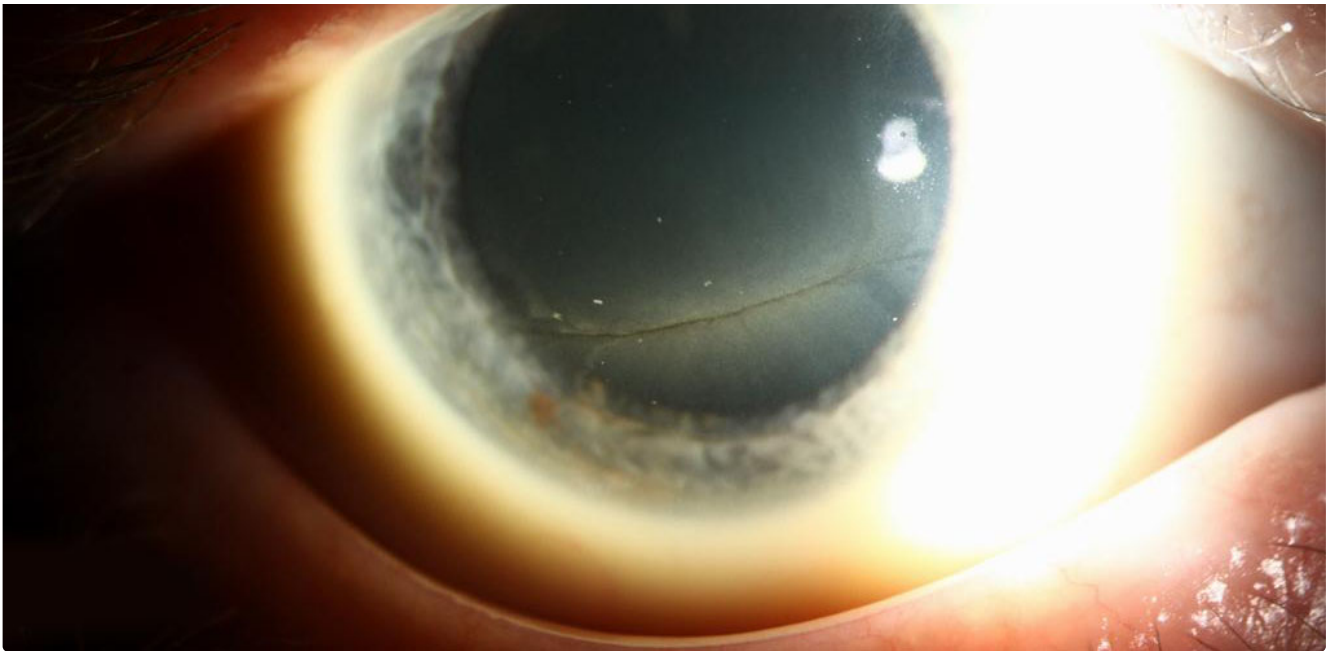
[Download](#)

## Figure 4: Cornea verticillata in a patient with known Fabry disease.

Contributor: Jeff Welder, MD

EYE ROUNDS.ORG

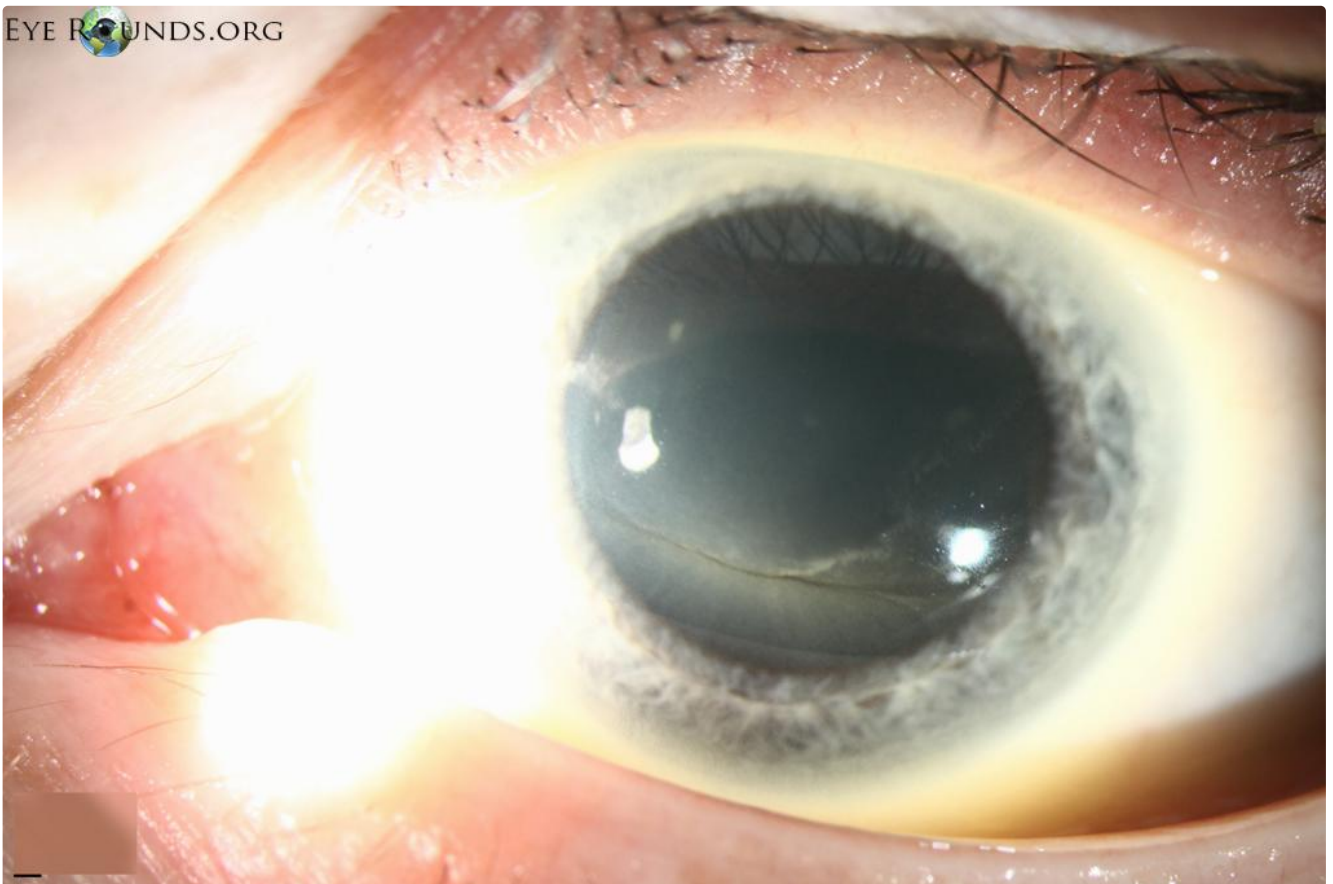




[Enlarge](#)

[Download](#)

EYE  ROUNDS.ORG



[Enlarge](#)

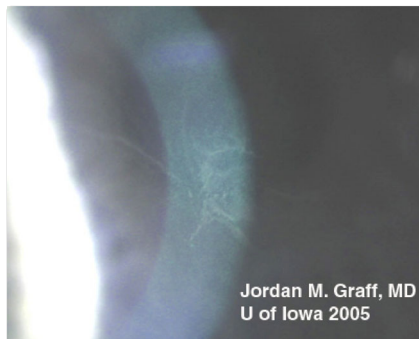[Download](#)

#### Image Permissions:



Ophthalmic Atlas Images by [EyeRounds.org](http://EyeRounds.org), [The University of Iowa](http://The University of Iowa) are licensed under a [Creative Commons Attribution-NonCommercial-](http://creativecommons.org/licenses/by-nc-sa/4.0/)

## Related Articles



[Related Case: Verticillata](#)

## Address

University of Iowa  
Roy J. and Lucille A. Carver College  
of Medicine  
Department of Ophthalmology and  
Visual Sciences  
200 Hawkins Drive  
Iowa City, IA 52242

[Support Us](#)

## Legal

Copyright © 2019 The University of  
Iowa. All Rights Reserved  
[Report an issue with this page](#)  
[Web Privacy Policy](#) |  
[Nondiscrimination Statement](#)

## Related Links

[Cataract Surgery for Greenhorns](#)  
[EyeTransillumination](#)  
[Gonioscopy.org](#)  
[Iowa Glaucoma Curriculum](#)  
[Iowa Wet Lab](#)  
[Patient Information](#)  
[Stone Rounds](#)  
[The Best Hits Bookshelf](#)

## EyeRounds Social Media

Follow



Receive notification of new cases,  
[sign up here](#)  
[Contact Us](#)  
[Submit a Suggestion](#)