

Corneal macular dystrophy

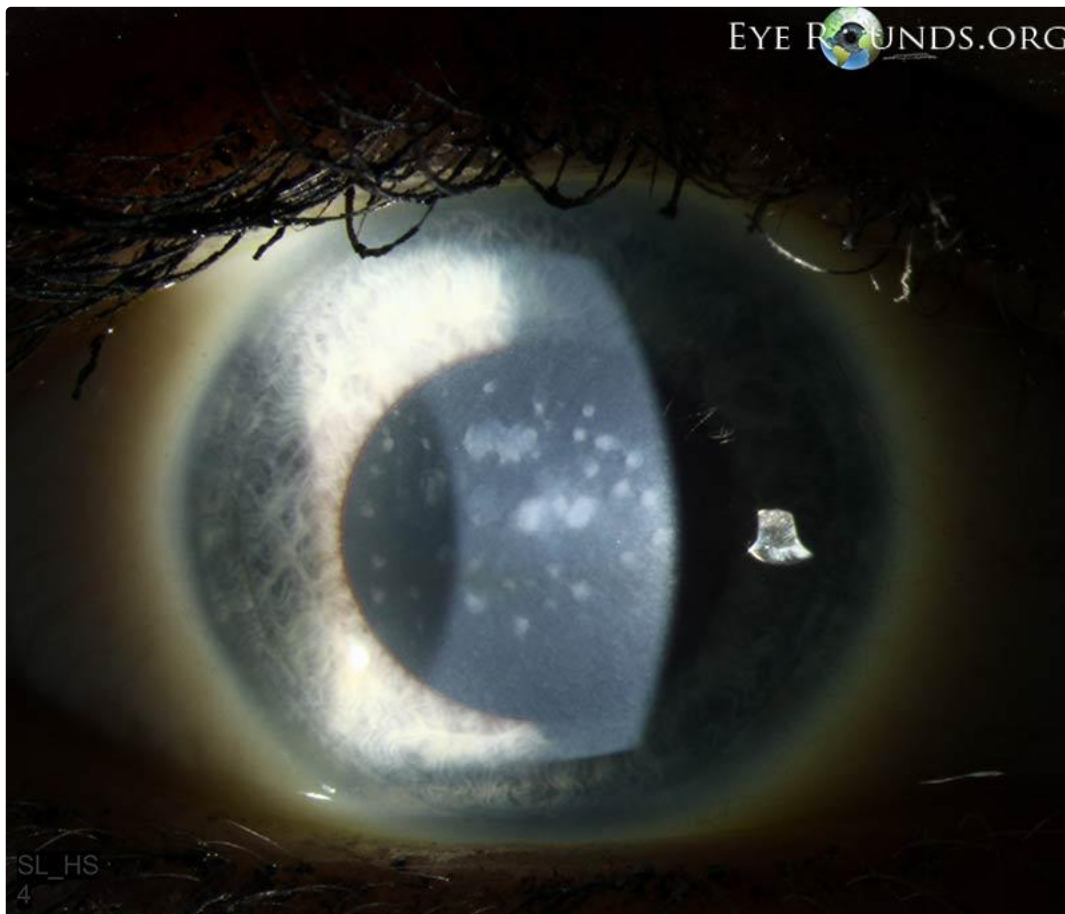Category(ies): [Inherited Eye Disease](#), [Cornea](#)

Contributor: [Jesse Vislisel, MD](#)

Photographer: [Cindy Montague, CRA](#)



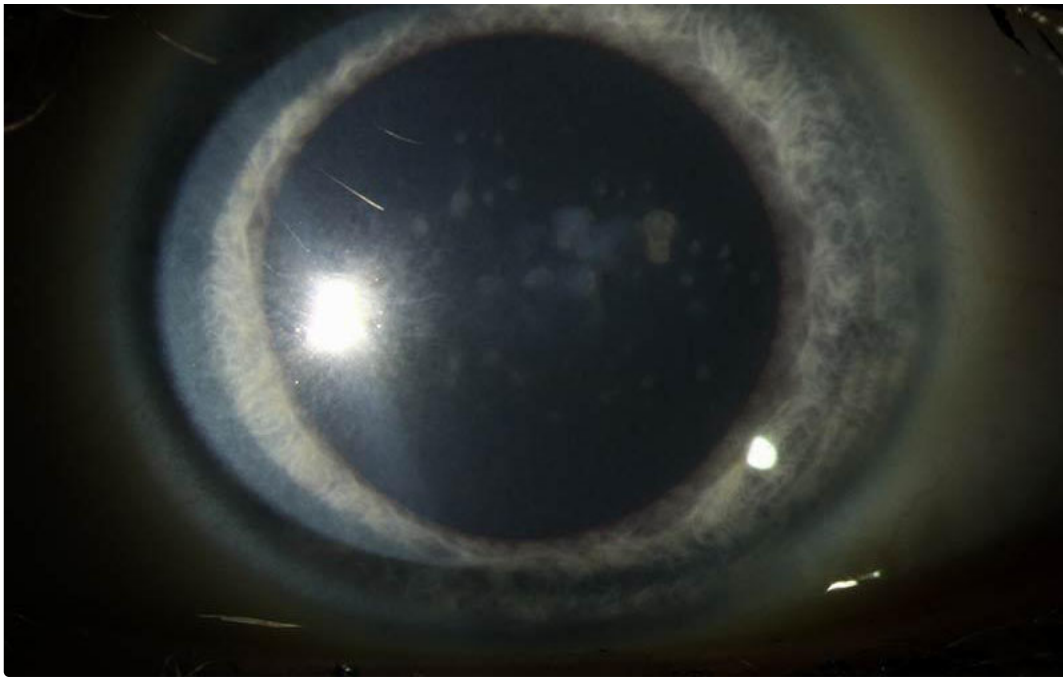
Corneal macular dystrophy is an autosomal recessive condition due to a mutation in the CHST6 gene which results in abnormal synthesis of keratan sulfate. The condition presents with mucopolysaccharide deposits appearing as gray-white opacities throughout all corneal stromal levels and extending into the periphery. There is diffuse clouding of the stroma between opacities.



right eye

[Enlarge](#) [Download](#)





right eye

[Enlarge](#) [Download](#)

Image Permissions:



Ophthalmic Atlas Images by EyeRounds.org, The University of Iowa are licensed under a [Creative Commons Attribution-NonCommercial-NoDerivs 3.0 Unported License](https://creativecommons.org/licenses/by-nc-nd/3.0/).

Address

University of Iowa
Roy J. and Lucille A. Carver College
of Medicine
Department of Ophthalmology and
Visual Sciences
200 Hawkins Drive
Iowa City, IA 52242

[Support Us](#)

Legal

Copyright © 2019 The University of
Iowa. All Rights Reserved
[Report an issue with this page](#)
[Web Privacy Policy](#) |
[Nondiscrimination Statement](#)

Related Links

[Cataract Surgery for Greenhorns](#)
[EyeTransillumination](#)
[Gonioscopy.org](#)
[Iowa Glaucoma Curriculum](#)
[Iowa Wet Lab](#)
[Patient Information](#)
[Stone Rounds](#)
[The Best Hits Bookshelf](#)

EyeRounds Social Media

Follow



Receive notification of new cases,
[sign up here](#)
[Contact Us](#)
[Submit a Suggestion](#)