

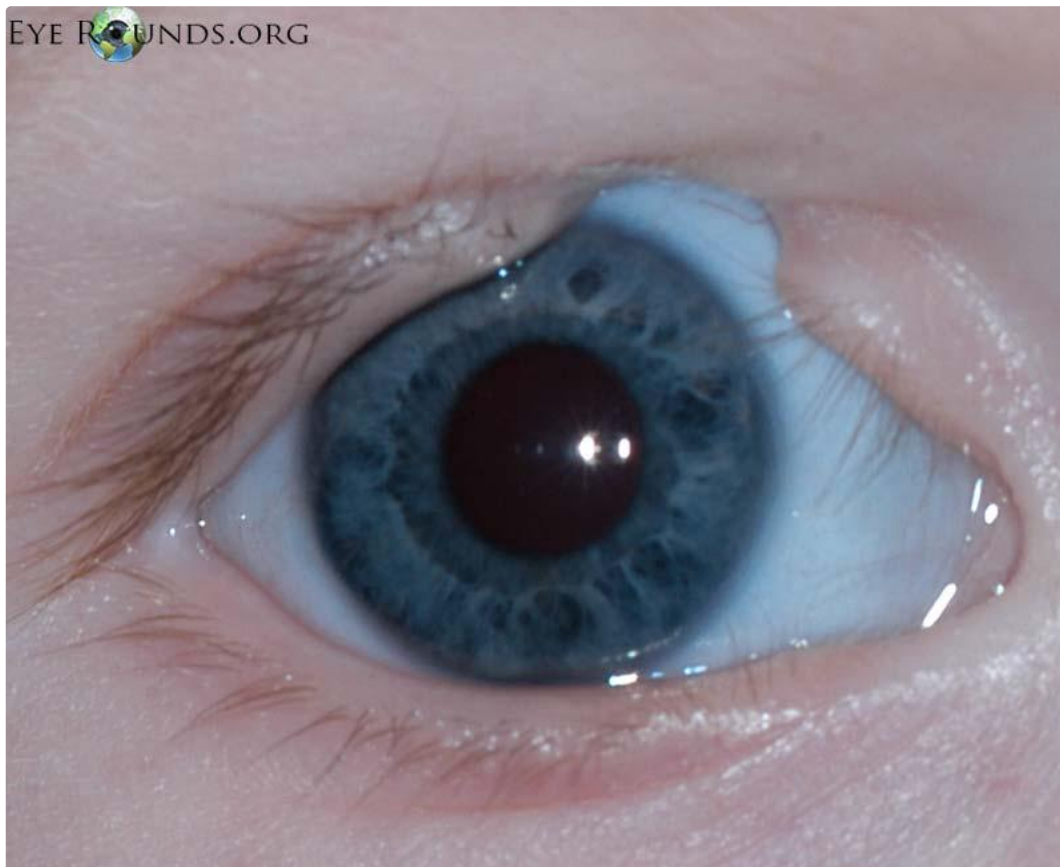
Eyelid coloboma

Category(ies): [Pediatrics](#)

Contributor: [Jesse Vislisel, MD](#)



Eyelid colobomas are embryologic clefts that can range in size from a small notch to the full length of the eyelid. Medial upper lid colobomas, as seen in this photo, are typically isolated anomalies. Those involving the lower lid are often associated with other congenital conditions such as Goldenhar syndrome.



[Enlarge](#) [Download](#)

Image Permissions:



Ophthalmic Atlas Images by [EyeRounds.org, The University of Iowa](#) are licensed under a [Creative Commons Attribution-NonCommercial-NoDerivs 3.0 Unported License](#).

Address

University of Iowa
Roy J. and Lucille A. Carver College
of Medicine
Department of Ophthalmology and
Visual Sciences
200 Hawkins Drive
Iowa City, IA 52242

[Support Us](#)

Legal

Copyright © 2019 The University of
Iowa. All Rights Reserved
[Report an issue with this page](#)
[Web Privacy Policy](#) |
[Nondiscrimination Statement](#)

Related Links

[Cataract Surgery for Greenhorns](#)
[EyeTransillumination](#)
[Gonioscopy.org](#)
[Iowa Glaucoma Curriculum](#)
[Iowa Wet Lab](#)
[Patient Information](#)
[Stone Rounds](#)
[The Best Hits Bookshelf](#)

EyeRounds Social Media

Follow



[Receive notification of new cases,
sign up here](#)
[Contact Us](#)
[Submit a Suggestion](#)