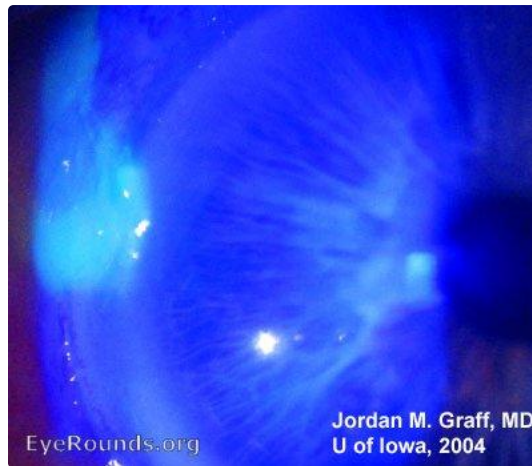


Foreign body

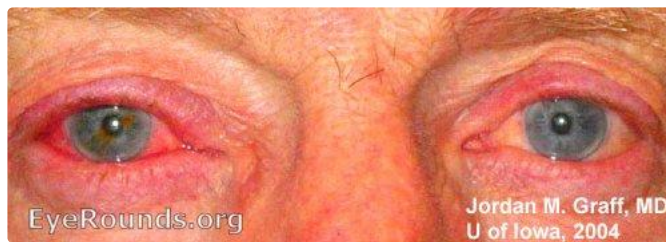Category(ies): Cornea

Contributor: [Jordan Graff, MD](#)



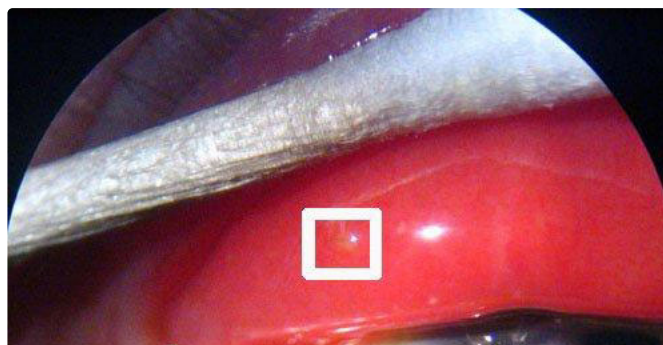
This farmer had been bothered by red eye, foreign body sensation, tearing, and irritation for several days.

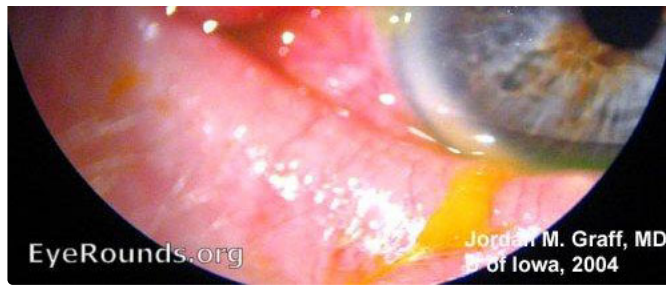[Enlarge](#) [Download](#)



The localized conjunctival and epithelial defect suggested a focal irritant.

[Enlarge](#) [Download](#)





The tiny shred of a thistle is evident on the tarsal surface of the upper lid.

[Enlarge](#) [Download](#)



Be aware that tiny foreign bodies could be easily missed, as was the case for this patient seen at another facility only two days before this visit for similar complaints.

[Enlarge](#) [Download](#)

Image Permissions:



Ophthalmic Atlas Images by [EyeRounds.org](#), [The University of Iowa](#) are licensed under a [Creative Commons Attribution-NonCommercial-NoDerivs 3.0 Unported License](#).

Address

University of Iowa
Roy J. and Lucille A. Carver College
of Medicine
Department of Ophthalmology and
Visual Sciences
200 Hawkins Drive
Iowa City, IA 52242

[Support Us](#)

Legal

Copyright © 2019 The University of
Iowa. All Rights Reserved
Report an issue with this page
[Web Privacy Policy](#) |
[Nondiscrimination Statement](#)

Related Links

[Cataract Surgery for Greenhorns](#)
[EyeTransillumination](#)
[Gonioscopy.org](#)
[Iowa Glaucoma Curriculum](#)
[Iowa Wet Lab](#)
[Patient Information](#)
[Stone Rounds](#)
[The Best Hits Bookshelf](#)

EyeRounds Social Media

Follow



Receive notification of new cases,
[sign up here](#)
[Contact Us](#)
[Submit a Suggestion](#)