

Herpes Simplex Keratitis

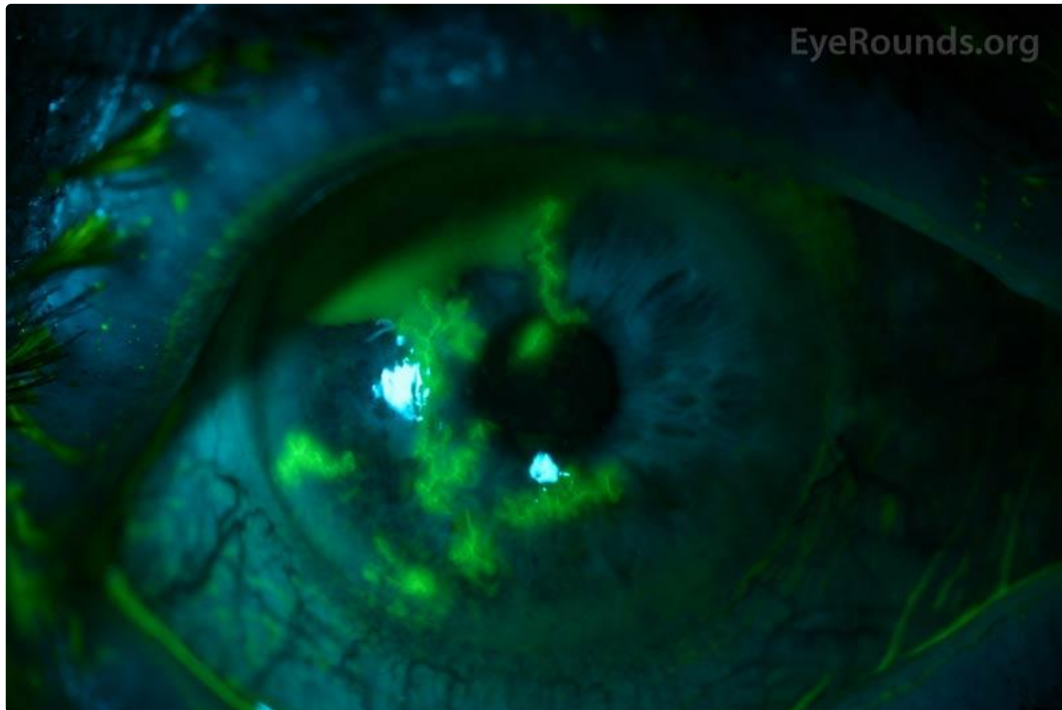Category(ies): Cornea

Contributor: [Alison Bozung, OD](#)

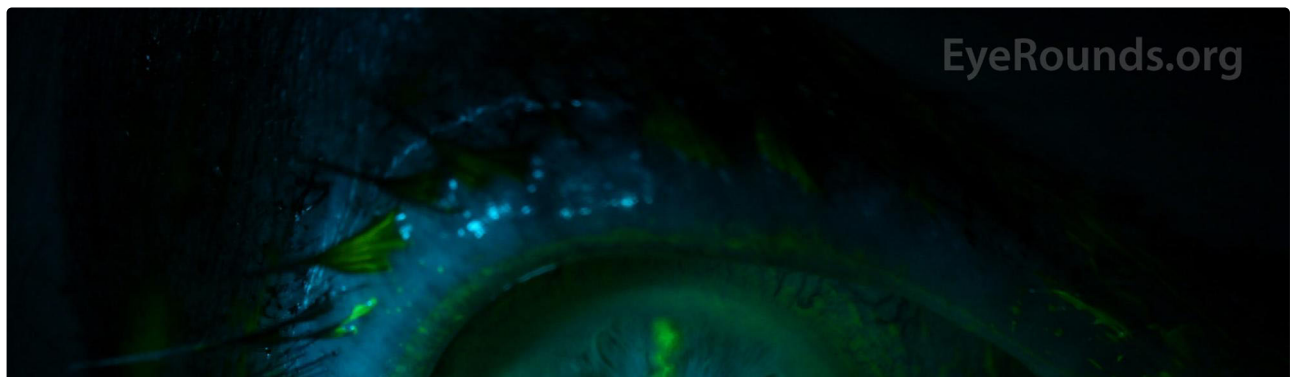
Photographer: Jody Troyer, CRA

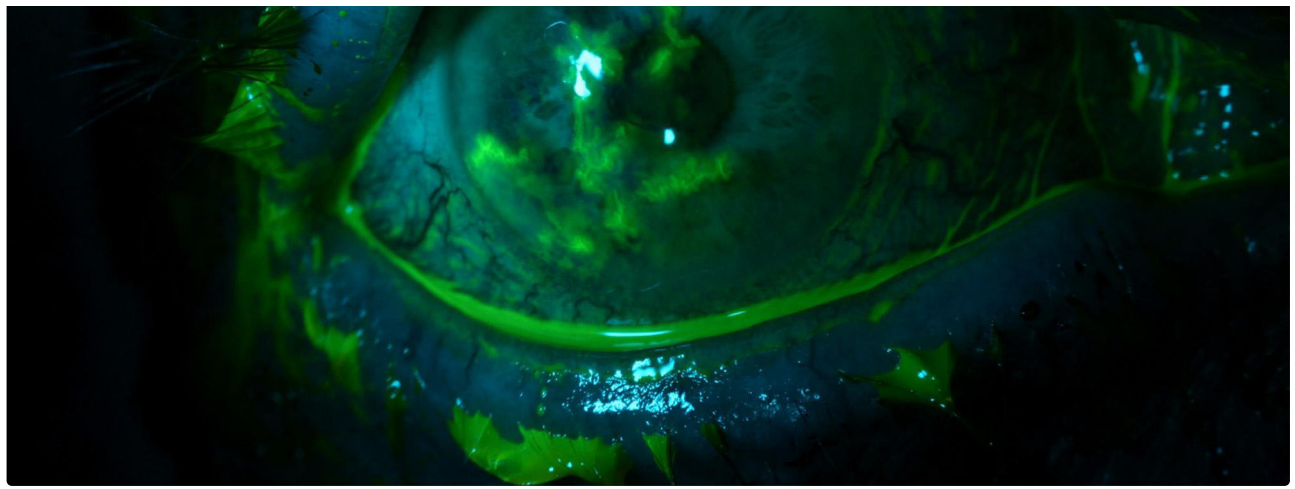


This photo exhibits multiple branching epithelial dendritic lesions due to herpes simplex virus (HSV). This particular patient had a history of herpetic keratitis, and reactivation of the virus was likely due, in part, to immunosuppression from the initiation of systemic chemotherapy for metastatic adenocarcinoma.



[Enlarge](#) [Download](#)

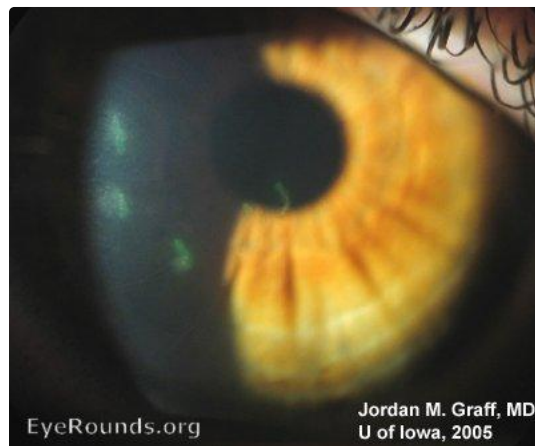



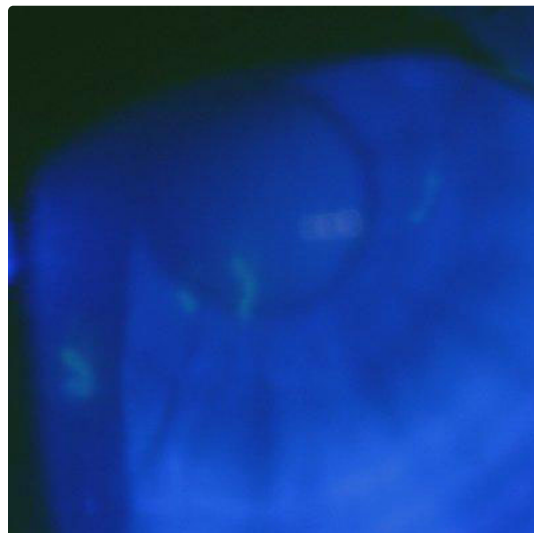
[Enlarge](#) [Download](#)

Contributor: [Jordan M. Graff, MD](#)

Not all cases of HSV keratitis have the large, arborating brightly staining dendrites seen in classic text-book examples. The lesions in this case of documented HSV keratitis are multiple, smaller, and with less impressive branching. However, the clinician should recognize the dendritic appearance. The overall context of the patient's clinical presentation helps to make the diagnosis (pain, photophobia, blurred vision, tearing, epithelial vesicles, decreased corneal sensation).



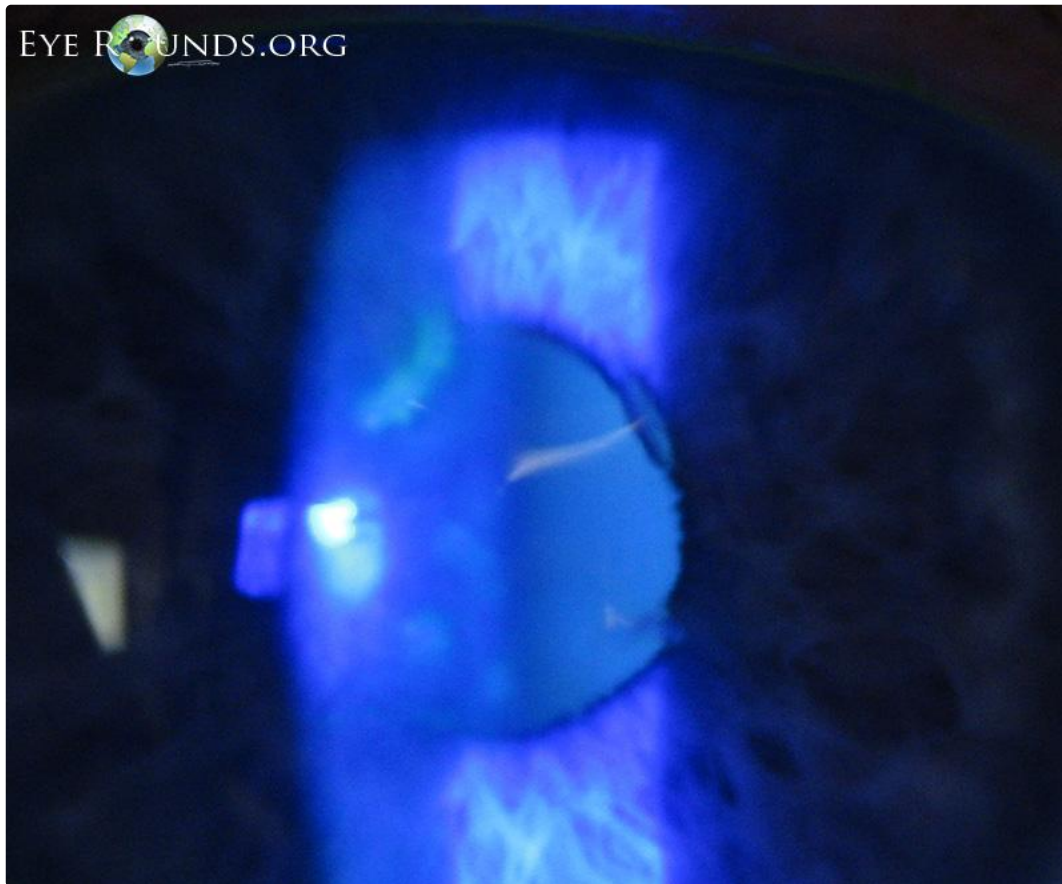
[Enlarge](#) [Download](#)



Flourescein staining and cobalt blue light illumination of the same lesions seen in Figure 1.

[Enlarge](#) [Download](#)

Contributor: [Jeffrey D. Welder, MD](#)



48-year-old male with Herpes simplex virus keratitis in left eye showing dendrite pattern of fluoroscein staining

[Enlarge](#) [Download](#)

Image Permissions:



Ophthalmic Atlas Images by [EyeRounds.org](#), [The University of Iowa](#) are licensed under a [Creative Commons Attribution-NonCommercial-NoDerivs 3.0 Unported License](#).

Address

University of Iowa
Roy J. and Lucille A. Carver College
of Medicine
Department of Ophthalmology and
Visual Sciences
200 Hawkins Drive
Iowa City, IA 52242

[Support Us](#)

Legal

Copyright © 2019 The University of
Iowa. All Rights Reserved
[Report an issue with this page](#)
[Web Privacy Policy](#) |
[Nondiscrimination Statement](#)

Related Links

[Cataract Surgery for Greenhorns](#)
[EyeTransillumination](#)
[Gonioscopy.org](#)
[Iowa Glaucoma Curriculum](#)
[Iowa Wet Lab](#)
[Patient Information](#)
[Stone Rounds](#)
[The Best Hits Bookshelf](#)

EyeRounds Social Media

[Follow](#)



[Receive notification of new cases,
sign up here](#)
[Contact Us](#)
[Submit a Suggestion](#)