

Mature Cataract

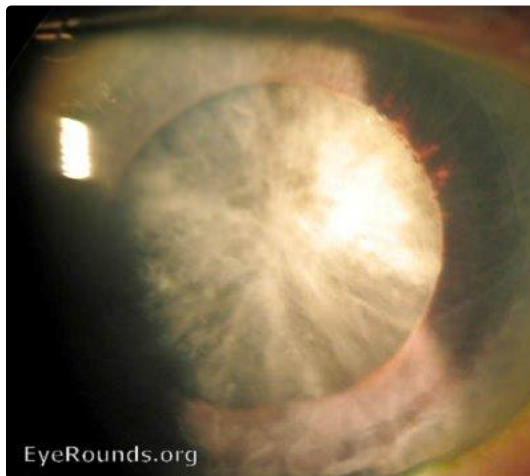
Category(ies): Cataract

Contributor: [Andrew Doan, MD, PhD](#)



Mature Cataract removed via ECCE.

[Enlarge](#) [Download](#)

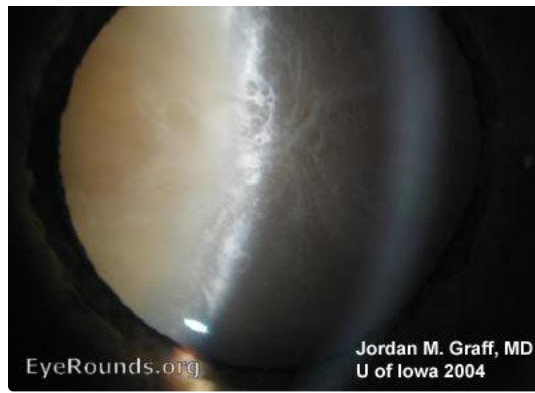

Patient with light perception vision from dense cataract.

[Enlarge](#) [Download](#)

Contributor: [Jordan M. Graff, MD](#)

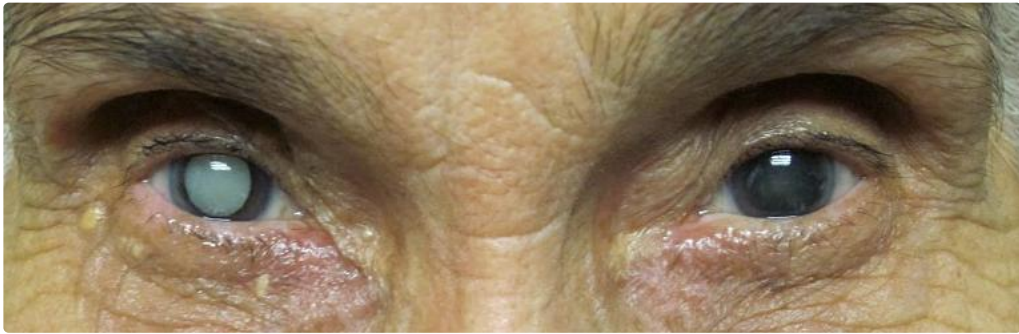




This patient with mature cataract (nuclear sclerotic and cortical changes) had only bare light perception vision.

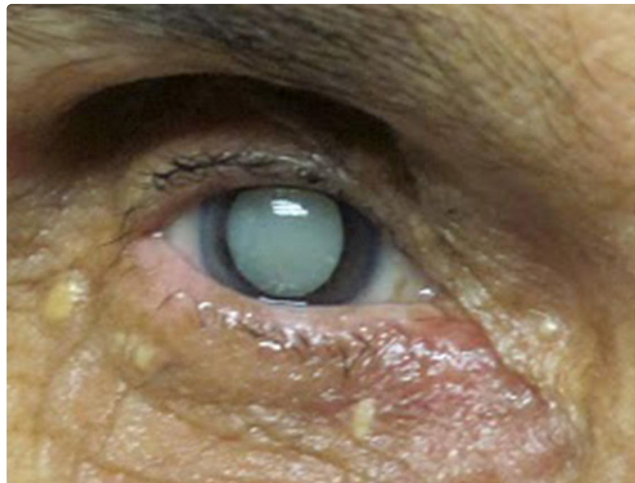
[Enlarge](#) [Download](#)

Contributor: Elizabeth Gauger, MD

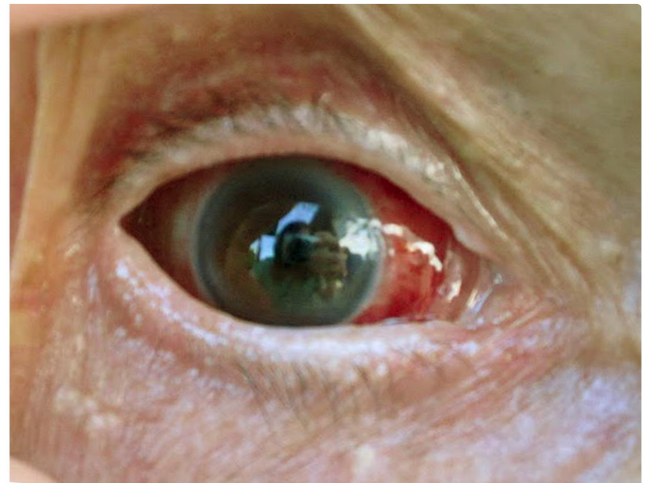


Presurgically, this elderly female presented with a mature cataract in the right eye. Visual Acuity in her right eye was hand motions only

[Enlarge](#) [Download](#)



Mature Cataract



One day post-op Extracap

Extracapsular Cataract Surgery was performed. Visual Acuity 1 day postoperatively was 20/50in her right eye

[Enlarge](#) [Download](#)



Ophthalmic Atlas Images by [EyeRounds.org](https://www.eyerounds.org), [The University of Iowa](https://www.uniowa.edu) are licensed under a [Creative Commons Attribution-NonCommercial-NoDerivs 3.0 Unported License](https://creativecommons.org/licenses/by-nc-nd/3.0/).

Address

University of Iowa
Roy J. and Lucille A. Carver College
of Medicine
Department of Ophthalmology and
Visual Sciences
200 Hawkins Drive
Iowa City, IA 52242

[Support Us](#)

Legal

Copyright © 2019 The University of
Iowa. All Rights Reserved
[Report an issue with this page](#)
[Web Privacy Policy](#) |
[Nondiscrimination Statement](#)

Related Links

[Cataract Surgery for Greenhorns](#)
[EyeTransillumination](#)
[Gonioscopy.org](#)
[Iowa Glaucoma Curriculum](#)
[Iowa Wet Lab](#)
[Patient Information](#)
[Stone Rounds](#)
[The Best Hits Bookshelf](#)

EyeRounds Social Media

Follow



Receive notification of new cases,
[sign up here](#)
[Contact Us](#)
[Submit a Suggestion](#)