

Traumatic cataract with iridodialysis and lens coloboma

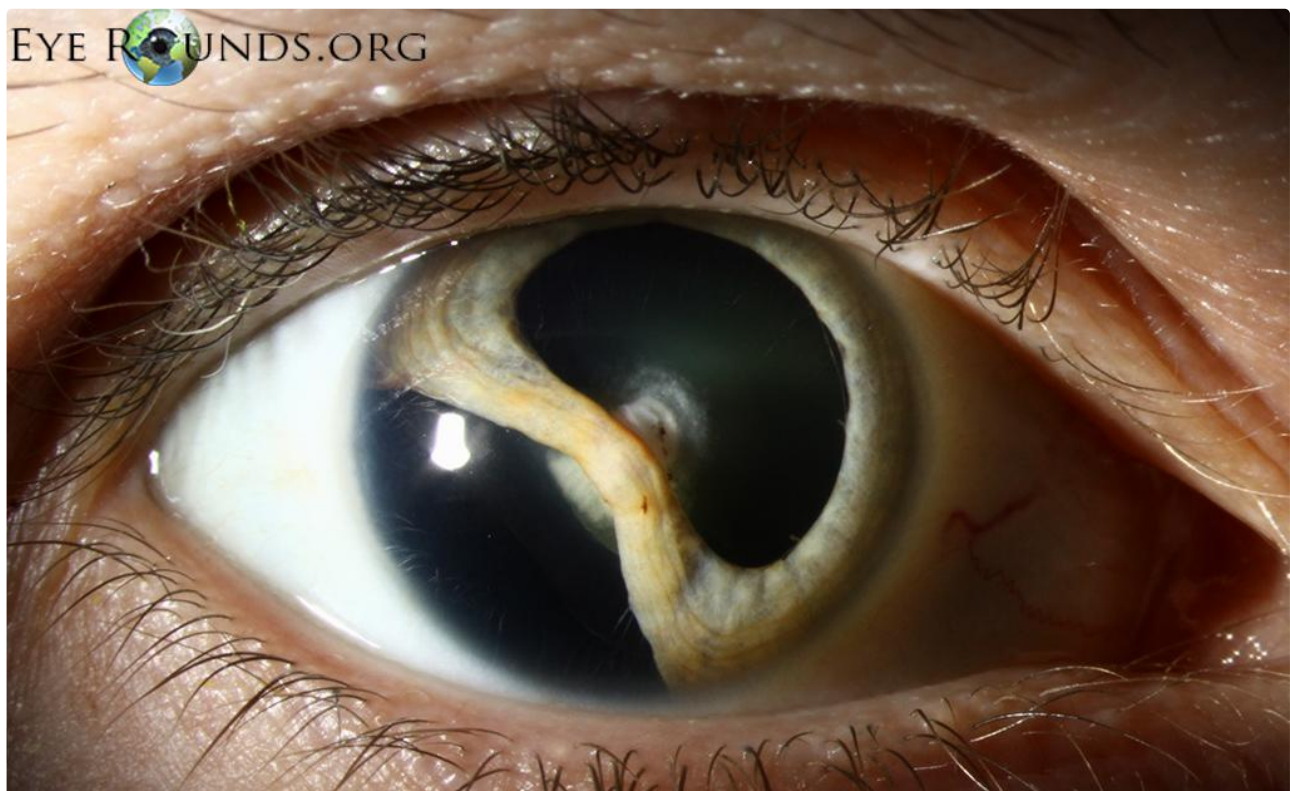
Category(ies): Lens, Iris, Trauma

Contributor: [Christopher A Kirkpatrick, MD](#)

Photographer: Cindy Montague, CRA



This is a traumatic cataract with an iridodialysis (separation of the iris from its attachment to the ciliary body) from a blunt injury during childhood. There is an anterior cortical cataract with evidence of capsular compromise and adhesion of the displaced iris to this area. There is also a lens pseudo-coloboma (lessened convexity along the equator) inferotemporally secondary to zonular dehiscence (not shown).



[Enlarge](#) [Download](#)

Image Permissions:



Ophthalmic Atlas Images by [EyeRounds.org](#), [The University of Iowa](#) are licensed under a [Creative Commons Attribution-NonCommercial-NoDerivs 3.0 Unported License](#).

Address

University of Iowa
Roy J. and Lucille A. Carver College
of Medicine
Department of Ophthalmology and
Visual Sciences
200 Hawkins Drive
Iowa City, IA 52242

[Support Us](#)

Legal

Copyright © 2019 The University of
Iowa. All Rights Reserved
[Report an issue with this page](#)
[Web Privacy Policy](#) |
[Nondiscrimination Statement](#)

Related Links

[Cataract Surgery for Greenhorns](#)
[EyeTransillumination](#)
[Gonioscopy.org](#)
[Iowa Glaucoma Curriculum](#)
[Iowa Wet Lab](#)
[Patient Information](#)
[Stone Rounds](#)
[The Best Hits Bookshelf](#)

EyeRounds Social Media

Follow



[Receive notification of new cases,
sign up here](#)
[Contact Us](#)
[Submit a Suggestion](#)