

Sarcoidosis

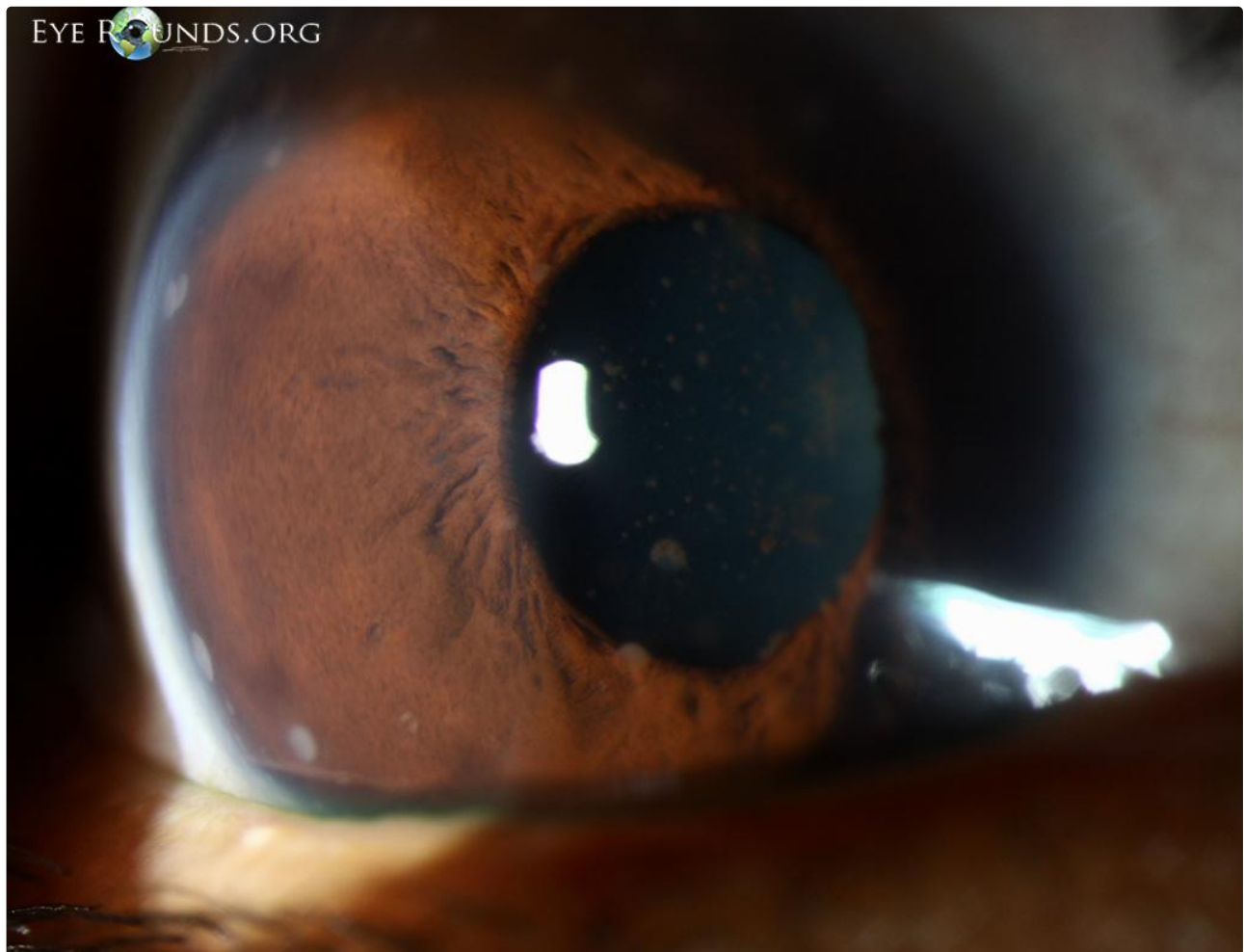
Category(ies): Uveitis

Contributor: [Justin Risma, MD](#)

Photographer: Carol Chan, CRA and Deb Kaefring



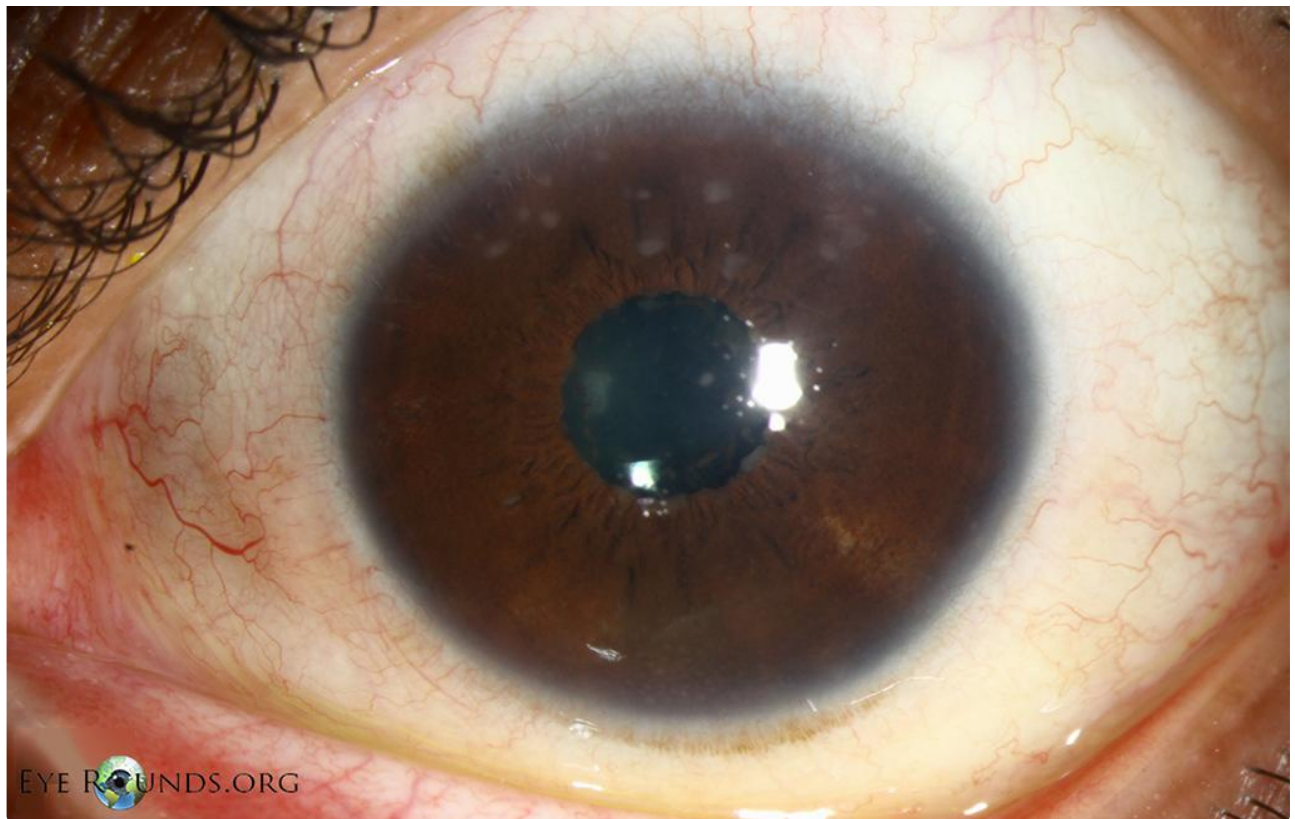
This 34-year-old African American male presented with a few months of blurry vision and photophobia. On exam, he was noted to have bilateral granulomatous anterior uveitis with large mutton-fat keratic precipitates, iris granulomas, enlarged lacrimal glands, and bilateral cervical and post-auricular lymphadenopathy. Laboratory testing revealed an angiotensin converting enzyme (ACE) level of 294 U/L (normal 8-52). He was referred to pulmonary medicine and diagnosed with sarcoidosis.



Photos 1 : Mutton-fat keratic precipitates and iris granulomas in sarcoidosis.

[Enlarge](#) [Download](#)





Photos 2: Mutton-fat keratic precipitates and iris granulomas in sarcoidosis.

[Enlarge](#) [Download](#)

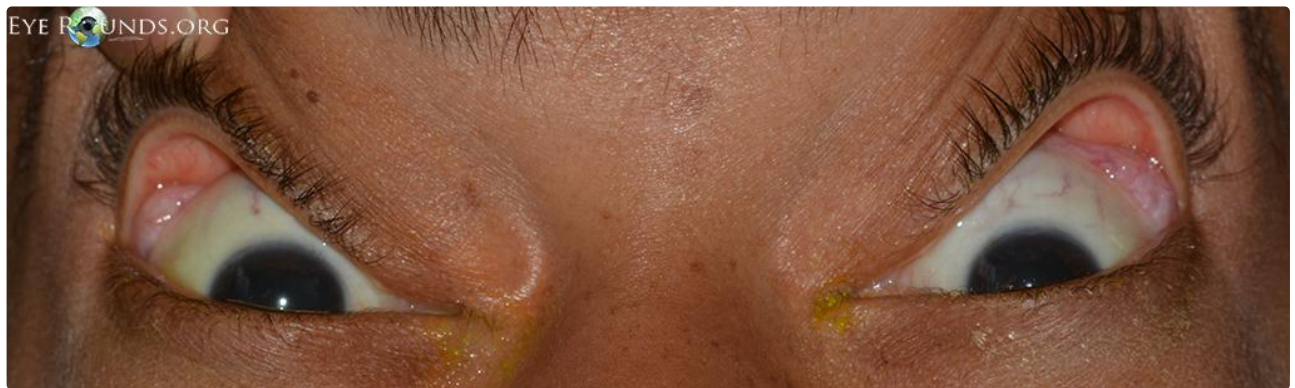
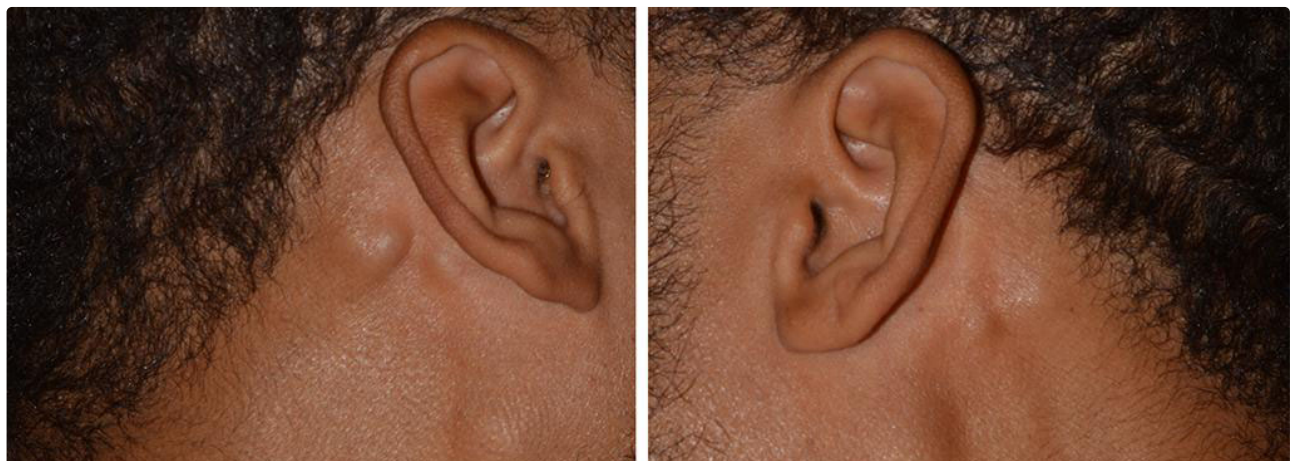
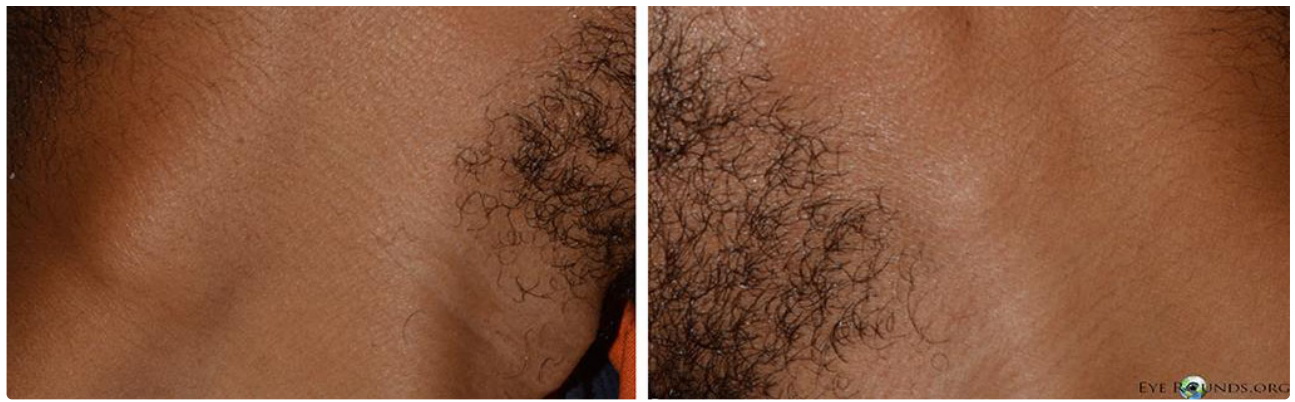

Photo 3: Lacrimal gland enlargement in sarcoisosis

[Enlarge](#) [Download](#)





Photos 4 and 5: Cervical and post-auricular lymphadenopathy in sarcoidosis

[Enlarge](#)

[Download](#)

Image Permissions:



Ophthalmic Atlas Images by EyeRounds.org, The University of Iowa are licensed under a [Creative Commons Attribution-NonCommercial-NoDerivs 3.0 Unported License](https://creativecommons.org/licenses/by-nc-nd/3.0/).

Address

University of Iowa
Roy J. and Lucille A. Carver College
of Medicine
Department of Ophthalmology and
Visual Sciences
200 Hawkins Drive
Iowa City, IA 52242

[Support Us](#)

Legal

Copyright © 2019 The University of
Iowa. All Rights Reserved
[Report an issue with this page](#)
[Web Privacy Policy](#) |
[Nondiscrimination Statement](#)

Related Links

[Cataract Surgery for Greenhorns](#)
[EyeTransillumination](#)
[Gonioscopy.org](#)
[Iowa Glaucoma Curriculum](#)
[Iowa Wet Lab](#)
[Patient Information](#)
[Stone Rounds](#)
[The Best Hits Bookshelf](#)

EyeRounds Social Media

Follow



Receive notification of new cases,
sign up here
[Contact Us](#)
[Submit a Suggestion](#)